ORIGINAL ARTICLE

Association of Cardiac Resynchronization Therapy with Stem Cell Transplantation for Ischemic Heart Disease

JUAN C. CHACHQUES, MD, PHD; ABDEL SHAFY, MD; THOMAS LAVERGNE, MD; CHRISTIAN LATREMOUILLE, MD, PHD; MIGUEL CORTES-MORICHETTI, MD; ALAIN CARPENTIER, MD, PHD

Received: 30/11/2009
Accepted: 15/02/2010

Address for reprints:
Juan C. Chachques, MD, PhD
Department of Cardiovascular Surgery
Pompidou Hospital
20 rue Leblanc, 75015 Paris, France.
e-mail :
j.chachques@brs.aphp.fr

SUMMARY

Local myocardial treatments using stem cells was proposed in ischemic and non ischemic cardiomyopathies for repairing the injured ventricles. The association of electrostimulation with cellular cardiomyoplasty could be a way to transform passive cell therapy into "dynamic cellular support". The purpose of this study is to evaluate myogenic cell transplantation in an ischemic heart model associated with cardiac resynchronization therapy (CRT).

Materials and Methods

Twenty two sheep were included. All animals underwent myocardial infarction by ligation of 2 coronary artery branches. After 4 weeks, autologous cultured skeletal myoblasts were injected. Atrial synchronized biventricular pacing was performed and echocardiography was performed at 4 weeks (baseline) and 12 weeks after infarction.

Results

Echocardiography showed a significant improvement in ejection fraction and limitation of LV dilatation in cell therapy with CRT as compared to the other groups. Viable cells were identified in the infarcted areas. Differentiation of myoblasts into myotubes and enhanced expression of slow myosin heavy chain was observed in the electrostimulated group. Transplantation of cells with CRT caused an increase in diastolic wall thickening in the infarcted zone relative to cells-only and CRT-only.

Conclusions

Biventricular pacing seems to induce synchronous contraction of transplanted myoblasts and the host myocardium, thus improving ventricular function. Electrostimulation was related with enhanced expression of slow myosin and the organization of myoblasts in myotubes, better adapted at performing cardiac work. Heart failure patients presenting myocardial infarct scars and indication for CRT might benefit from simultaneous cardiac pacing and stem cell therapy for myocardial support and regeneration.

Rev Argent Cardiol 2010: 75-81.

Key words > Ischemic Heart Disease - Myocardial Infarction - Cardiac Resynchronisation Therapy - Cell Transplantation - Heart Failure - Functional Electrostimulation - Skeletal Myoblasts

Abbreviations >

CRT	Cardiac resynchronization therapy	**LV**	Left ventricle
FCS	Fetal calf serum	**LVAWd**	Left ventricle anterior wall thickness at diastole
LVEF	Left ventricular ejection fraction	**LVEDV**	Left ventricle endiastolic volume
HF	Heart failure		
HMSCs	Human mesynchymal stem cells		

INTRODUCTION

Stem cell research has been one of the most exciting recent developments in biotechnology, promising to aid in the treatment or cure of degenerative and chronic diseases, including leukaemia, cardiovascular pathology, cancer, and diabetes. Local myocardial treatments using stem cells was proposed 10 years ago in ischemic and non ischemic cardiomyopathies for repairing the injured heart. Clinical results have showed some evidence of myocardial regeneration and effects in diastolic function but poor effect in systolic function. This can be due to the lack of gap junctions between the native myocardium and the grafted cells. Also, cell transplantation seems to be limited by death of transplanted cells. Most cell death occurs in the first few days post-transplantation, likely from a combination of ischemia, apoptosis and inflammation. (1-4) Interventions known to enhance transplanted cell survival include heat shock, over-expressing

Laboratory of Biosurgical Research and Departments of Cardiovascular Surgery and Cardiology, Pompidou Hospital, University of Paris, France.

antiapoptotic proteins, free radical scavengers, anti-inflammatory therapy and co-delivery of extracellular matrix molecules. Combinatorial use of such interventions could enhance graft cell survival. (5) In spite of these possibilities, until now cell transplantation constitutes a passive therapeutic approach, the only effects seems to be related to the reduction of the myocardial fibrosis and the limitation of the adverse ventricular remodelling. (6, 7)

Atrial synchronized biventricular pacing for cardiac resynchronization therapy (CRT) is indicated in patients suffering from heart failure to correct conduction disorders associated with chronic systolic and diastolic dysfunction. (8-10) The association of elec-trostimulation with cellular cardiomyoplasty could be a way to transform passive cell therapy into "dynamic cellular support". The principles of electrophysiolo-gical conditioning of skeletal muscle fibers (e.g., as developed for dynamic cardiomyoplasty procedure) can be applied in cellular cardiomyoplasty. (11) The hypothesis is that electrostimulation of both ventricles following skeletal myoblast implantation should induce the contraction of the transplanted cells and a higher expression of slow myosin, better adapted for chronic ventricular assistance. The purpose of this study is to evaluate myogenic cell transplantation in an ischemic heart model (12, 13) associated with atrial synchronized biventricular pacing.

MATERIALS AND METHODS

Experimental Animals

In 22 female Rambouillet sheep weighing 21 to 34 kg (mean, 30 ± 3.5 kg), a left ventricular (LV) myocardial infarct was surgically created by ligation of 2 coronary artery branches (distal LAD and D2). During the procedure a skeletal muscle biopsy was performed.

Four weeks after coronary artery ligation, 4 different treatment groups were defined.

GROUP 1 (control, n=5): surgical injection of cell culture medium in the infarcted area.

GROUP 2 (cell therapy, n=5): intrainfarct implantation of autologous myoblasts (70 million cells).

GROUP 3 (CRT, n=5): biventricular cardiac pacing alone.

GROUP 4 (cells + CRT, n=5): intrainfarct implantation of myoblasts associated with cardiac pacing.

In the group associating CRT, atrial synchronized biventricular pacing using epicardial electrodes was performed after cell implantation (study design in Fig. 1).

All animals were treated according to the guidelines of the French National Institute of Health and Medical Research (INSERM).

Anesthetic management

Premedication was carried out by intramuscular injection of acepromazine 150 mg (Vetranquil). The animals were prepared for surgery, using a jugular venous line and an auricular arterial line. For anesthesia, Propofol (Diprivan) was administered though the venous line at a concentration of 6 mg/kg. Ventilation was ensured though an endotracheal probe (n° 7) connected to a Siemens 900C respirator (Siemens AG, Munich, Germany) using the following parameters:

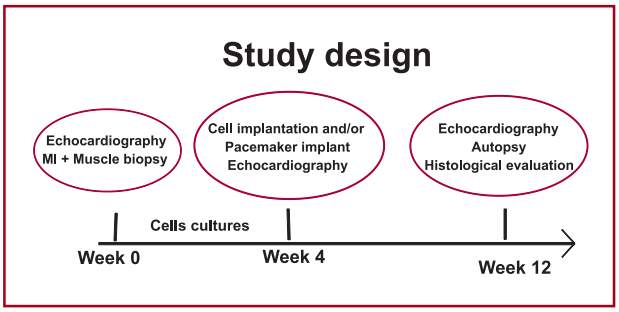

Fig. 1. Study design.

volume of 10 mL/kg, frequency of 24 breaths/min, and inspired oxygen fraction of 60%. Anesthesia was maintained by inhalation of isoflurane 1% to 2%. Postoperative management of the sheep consisted of cefazolin injected intramuscularly at 1 g per day during 5 days.

Skeletal muscle explantation and myocardial infarction

A 2-cm^3 skeletal muscle fragment was taken from the left posterior femoral biceps of each sheep under sterile conditions. The biopsy tissue was kept in Hanks balanced salt solution (Life Technologies, Rockville, Md) at 4°C until the cell culture was started.

Via a left thoracotomy, the ligation of the distal homonymous (equivalent to human left anterior descending) and second diagonal coronary arteries produced a constant transmural myocardial infarction. To reduce the risk of ventricular fibrillation, lidocaine 1% (2 mg · kg^{-1} · h^{-1}) was administered IV during the entire surgical procedure. Thereafter, the thoracic wall was closed after placing a chest tube in the pleural cavity. The drain was removed as soon as the sheep started spontaneous respiration. The severity of the myocardial injury was evaluated by cardiac troponin serum levels measured 24 hours after infarction.

Satellite cell isolation and culture

Skeletal myoblasts obtained from autologous muscle biopsy samples were isolated, purified, and cultured as previously described (7). In brief, the cells were cultured for 4 weeks in Ham's F12 medium containing 20% fetal calf serum (FCS) and 1% penicillin/streptomycin. To reduce the number of fibroblasts and achieve a pure myoblast culture, a preplating step was applied on the first passage. The preplating technique was based on the quicker attachment of fibroblasts compared with satellite cells. At 4 weeks, the cultured myoblasts were detached from the cell culture dish with 0.25% trypsin-ethylene diamine tetra acetic acid. After centrifugation at 300*g* for 5 minutes, 70 million cells were resuspended in 2 mL of culture medium and used for each transplantation.

Cell labeling

Sterile DAPI stock solution (Sigma, St Louis, Mo) was added to the culture medium at a final concentration of 50 μg/mL on the day of implantation. The dye was allowed to remain in the culture dishes for at least 30 minutes. The cells were rinsed at least 6 times in Hanks balanced salt solution to remove all excess (unbound) DAPI. Myoblast cells were then collected (approximately 70 x 10^6 cells for one implantation) and resuspended in minimal volume of the serum-free Dulbecco's medium and stored on ice (less than 1 hour) until implantation into the myocardium.

Cell implantation

After a 4-week in vitro cell expansion period, the animals were operated on. After usual preparation and median sternotomy, the infarct area was identified and the cell suspension was injected by using an insulin syringe and a retrobulbar ophthalmic needle (25 gauge x 40 mm). By 4 injection points, 70% of cells were implanted in the peri-infarct area (borderzone), since residual irrigation and collateral myocardial revascularization in this intermediate area allows for a better survival of the implanted cells. The remaining 30% of cells were implanted in the central portion of the scar. The treated area was identified with 2 single sutures associated with metal ligating clips. The use of a long needle for cell implantation avoids multiple traumatic injection points. Cells were delivered when the implanted needle was progressively removed from the myocardium. In order to avoid regurgitation of the cell solution (channel leakage), we performed finger compression (1 to 2 minutes) at the needle injection sites after every injection.

Pacemaker implantation

Animals were implanted with a pulse generator, Transform device (Model 4710, Medtronic, MN, USA) which is an implantable programmable dual channel pacemaker, the two channel coordinated by a synchronization circuit. The first channel is capable of sensing atrial signals and delivering stimuli to them when the sensed atrial intrinsic rate drops below the programmed pacing rate. The second channel is capable of generating a stimulation pulse synchronized to the first channel. The synchronization circuit determines the synchronization of the ventricles to paced or sensed atrial events.

Four epicardial electrodes (Medtronic SP 5591) were used for every sheep, two were implanted in the right atrium, one in the right ventricle and one in the left ventricle near the infarcted area.

Stimulation protocol was done by sensing of the right atrium and biventricular pacing using an atrio-ventricular delay of 70 ms (the normal delay at rest in sheep is 110 ms). This approach was used to induce the capture of ventricular activity. Atrial synchronized biventricular pacing was performed using the epicardial ventricular electrodes, with pulse amplitude of 5 Volts and a pulse width of 0.5 milliseconds.

Evaluation of ventricular function

Echocardiography (Sonos 1000, Hewlett-Packard, Palo Alto, California) with the aid of a 7-MHz transducer in the epicardial position was performed at cell implantation or at control medium injection or pacemaker implantation. Echocardiography was performed 4 weeks after infarction (baseline) and at 12 weeks after infarction. The global cardiac function was measured at the same time points in the 2-dimensional mode. Parameters included the LV end-diastolic and end-systolic diameters, the shortening fraction, the end-diastolic and systolic volumes, and the ejection fraction. The ejection fraction and shortening were calculated by the Teicholz method and were based on the LV end-systolic and end-diastolic diameters.

Histology and immunohistochemistry

All sheep were put to death 12 weeks after creation of infarct. The site of myocardial injury was identified and dissected. Five specimens were harvested, and each of these was cut into 2 pieces. The first one was fixed in 10% formol, embedded in paraffin, and sectioned to yield 10-μm-thick slices. The sections were stained with hematoxylin and eosin. The second piece of each specimen was frozen in liquid nitrogen–cooled isopentane. Frozen biopsy tissue was stored at -80°C until it was processed on a cryostat.

When cells were observed in the infarct sections, they were tested with fast and slow myosin heavy chain antibodies (Sigma Aldrich, St. Louis, Mo), which are specific for the skeletal isoform of adult fast and slow myosin.

For immunohistochemical studies, 5-μm-thick sections of frozen tissues were fixed for 10 minutes in cold acetone, and endogenous avidin and biotin sites were blocked (Dako, Glostrup, Denmark). Samples were incubated with the myosin heavy chain antibodies (1:300) in 0.1% FCS for 1 hour, followed by incubation with biotinyl anti-mouse immunoglobulin (1:200) (Vector Laboratories, Burlingame, Calif), and were finally incubated with streptavidin-cyanine 2 (Amersham Biosciences, Buckinghamshire, United Kingdom) 1:800 in phosphate-buffered saline for 30 minutes. The slides were then mounted with the Immuno-mount system (Thermo Shandon, Runcorn, United Kingdom) and studied with an inverted fluorescent microscope (Nikon Eclipse TE300; Nikon Inc, Melville, NY).

Statistical methods

Results are reported as percentage or mean ± SD. A paired or unpaired Student t test was used to compare the groups when needed. A 1-way analysis of variance was used when more than 2 groups were present. When indicated, a Student-Newman-Keuls multiple comparison test was used as a post hoc test.

RESULTS

Myocardial infarction creation

From 22 operated animals, two died during the creation of the infarction, both developed refractory ventricular fibrillation. Cardiac troponin I was chosen as an indicator of myocardial infarction. Cardiac troponin I values were expressed as mean ±standard deviation. The average serum level of cardiac troponin I one day after infarction was 125.4±70 ng/ml. No mortality was registered during reoperations or follow-up; at 12 weeks the number of the surviving animals was 20 (5 in each group).

Cell cultures

Cell culture conditions were evaluated before cell implantation, the primary skeletal muscle cell culture contained about 90% myoblasts as determined with desmin immunofluorescece. All cultures showed 99% of viability before implantation by means of trypan blue exclusion assay. In addition, all cell culture media taken from the cultures before implantation tested negative for aerobic and nonaerobic bacterial contaminations.

Echocardiography

Left ventricular function and dimensions were quantified 4 (baseline) and 12 weeks after myocardial injury. At baseline, the mean ejection fraction (EF) and LVEDV were similar in all four treatment groups.

Over the course of 4 weeks, each group dilated their LV end diastolic dimension compared with their preoperative value. At 12 weeks, a statistically significant attenuation of LV dilation was

demonstrated with CRT + cells compared with cells-only or CRT-only ($p < 0.01$ for both comparisons). In those animals, LVEDV increase from 58.4 ± 4.3 to 64.6 ± 6.6 mL (Fig. 2 A).

At 12 weeks, EF was significantly greater in the hearts treated with CRT + cells compared with those receiving cells-only or CRT-only ($p < 0.01$ for both comparisons). In those animals, EF was increased from 38.8 ± 1.97 to 44.8 ± 5.97% (Fig. 2 B).

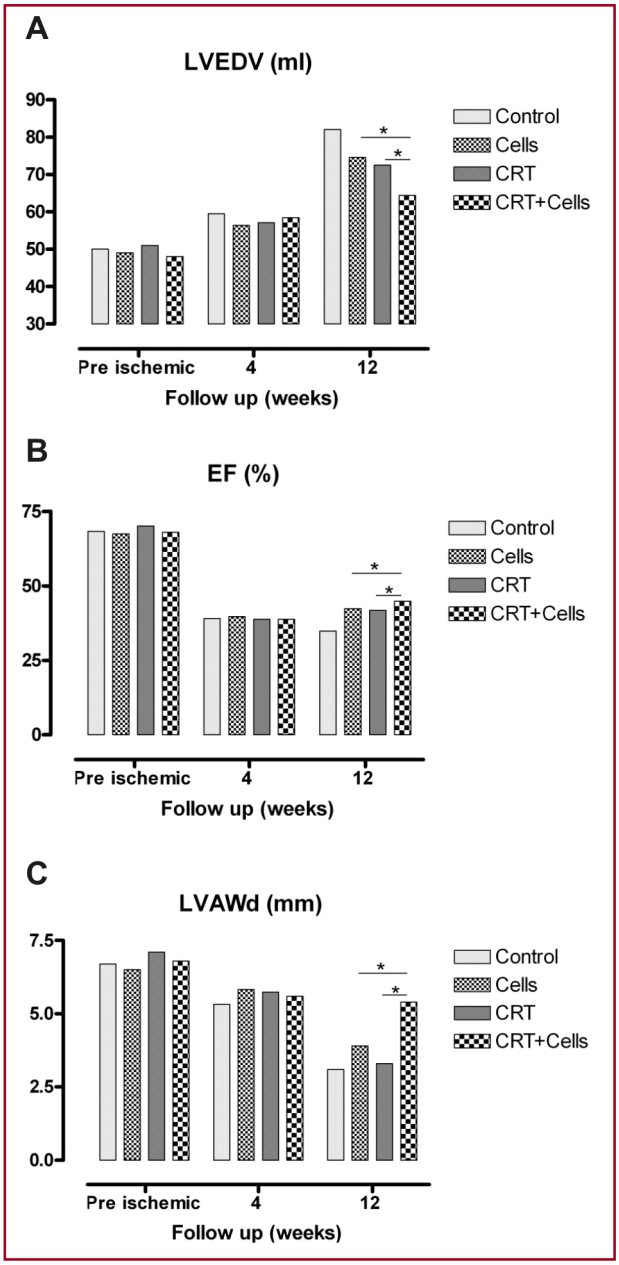

Fig. 2. A. Echocardiographic studies. Left ventricular end-diastolic volume evolution during follow up (* $p<0.01$). **B.** Ejection fraction evolution during follow up (* $p<0.01$). **C.** Left ventricular anterior wall thickness at diastolic phase evolution during follow up (* $p<0.01$).

Wall thickening was determined by echocardiography in the thinnest region of the infarct area 4 and 12 weeks after myocardial injury. At baseline LVAWd did not differ among groups. Transplantation of cells and CRT caused an increase in diastolic wall thickening in the infarcted zone relative to cells-only and CRT-only ($p < 0.01$ for all) (Fig. 2 C).

Identification of implanted cells

Macroscopically at 12 weeks, a local area of necrosis was consistently observed in the apex and anterolateral LV wall of all animals. Histological analysis with hematoxylin and eosin stain showed infarcted areas characterized by the replacement of healthy myocardium by adipose and fibrous tissue. The myocardial scars in sheep are predominantly infiltrated by adipose tissue.

By immunohistochemical analysis, sections from sheep treated with cells were positively stained with myosin heavy chain (the skeletal isoform of adult fast myosin heavy chain), and satellite cells were detected (Fig. 3 left). This antibody did not react with healthy or ischemic cardiac sections. In 4 sheep of the Group 4 (pacing + cell), elongated skeletal muscle cells structures were observed that resembled multinucleated well differentiated myotubes (Fig. 3 right), slow twitch type I fibers were identified across the sections.

By fluorescence microscopy satellite cells and myotubes were detected with their nucleus marked with DAPI stain, with better organization and much number when comparing the Group 2 (cells) versus the Group 4 (pacing + cells). (Fig. 4 and 5)

DISCUSSION

The prevalence of severe heart failure (HF) and the clear clinical limitations of conventional interventions

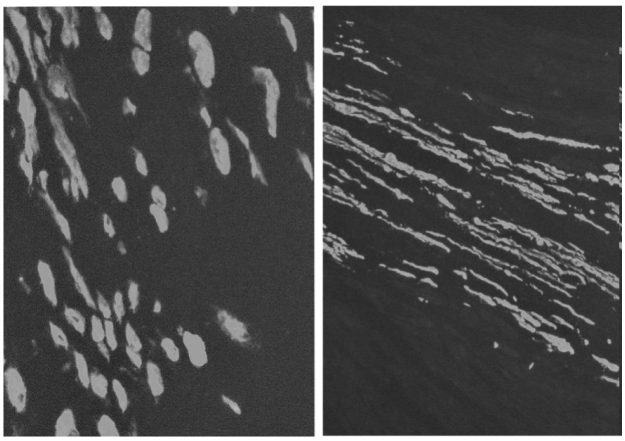

Fig. 3. Stain with MY-32 antibody to skeletal myosin (original magnifications, 200X). **Left:** Histoimmunologic studies at 12 weeks in cell treated group, showing isolated grafted myoblasts into the infarcted area. **Right:** Study of the cell + electrostimulation group, showing a mixture of multinucleated myotubes and fibrillar configuration.

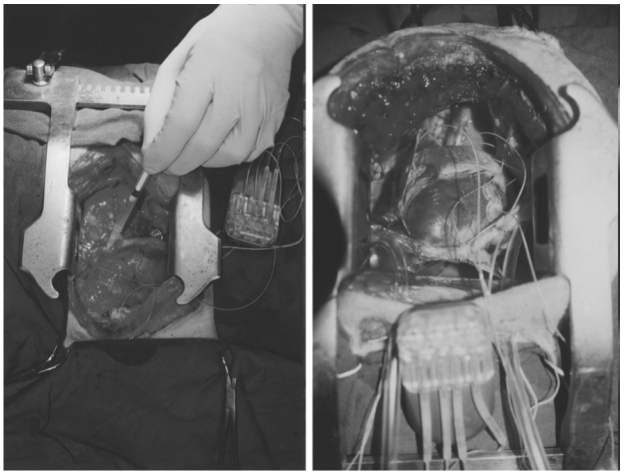

Fig. 4. Cross and longitudinal section of multinucleated myotubes (marked with DAPI dye) developed in the myocardial infarcted area after treatment with skeletal myoblasts associated with chronic electrostimulation (original magnification, 360X).

Fig. 5. Fibrillar configuration of myoblasts marked with DAPI dye in the infarcted area, Group 4 (original magnification, 320X).

have encouraged the development of new therapeutic tools. (14, 15) The natural evolution of HF with systolic function impairment leads to progression of the size of cardiac cavities. The interaction of hemodynamic processes influences on this dilatation (Frank-Starling law). In the cases of high significant increases of LV volumes, actin-myosin cross-bridges stretch outside of their physiologic limits, thus causing a decrease -instead of an increase- of contractile strength as well as structural changes due to the increase of end diastolic pressures which accompanies dilatation. In addition this pathological process involves extracardiac mechanisms, like metabolic changes at the systemic level. Thus, myocardial infarction leaves an akinetic fibrotic scar, which with adverse chamber remodelling leads to ventricular dilation and an overall loss of systolic and diastolic mechanical functions. Progressive left ventricular remodelling after myocardial infarction has been viewed as an important contributor to progressive heart failure, increase in regional remodelling strain led to an increase in myocardial apoptosis and regional contractile dysfunction in heart failure. (13)

Cellular therapy for myocardial regeneration in ischemic and non-ischemic cardiomyopathies is a rapidly burgeoning field, in view of the number of randomized controlled trials of this treatment modality currently in progress or being initiated. The idea of transplanting single cells has a number of attractive attributes and is dependent on an ever-expanding understanding of the molecular basis of angiogenesis and myogenesis. Cellular therapy's primary objective is to ensure the recolonization and restoration of postinfarction myocardial tissue, thus improving viability and function. The initial clinical trials of cell transplantation after a myocardial infarction have reported only limited improvements in ventricular function. Ongoing studies showed survival of the implanted cells, but no study showed active participation of the implanted cells in the force generation. This may due to lack of electrophysiological connections between the implanted cells and the host myocardium and lack of the gap junction protein (connexin 43). (6, 16-18)

The concept of electrostimulation of homed myogenic cells (e.g.: skeletal myoblasts) is to transform the passive cells into active contracting cells, i.e. from static cells to dynamic cells. It is important to remark that the physiologic myocardial cell potential is 85 mV. In our research protocol we have been delivering a 5V pulse from a pacemaker, the aim being to create a potential difference greater than 85 mV across each cell membrane. Therefore, we think that ventricular wall electrostimulation using 5 Volts pulses should induce depolarization and contraction of the implanted stem cells. In our experimental model ventricular walls were electrostimulated, therefore the transplanted skeletal myoblasts and the infarcted myocardium were simultaneously activated. Importantly, during the postoperative evolution we did not observe any animal mortality, indicating that this approach may allow excluding the induction of malignant cardiac arrhythmias related with the association of cells and electrostimulation.

The principle of electrophysiological conditioning of muscle fibers developed by our group for the latissimus dorsi dynamic cardiomyoplasty procedure were applied to this experimental study. (11) But in the present approach cells were stimulated with single pulses, not with pulse trains (bursts containing 6 spikes) as used in cardiomyoplasty. This was decided to avoid the risk of deleterious effects on myoblasts. (19) A functional engraftment is required to augment

synchronized contractility and to avoid potentially life-threatening alterations in the electrical conduction of the heart. Current evidence suggests that skeletal myoblasts or bone marrow-derived adult stem cells fail to electromechanically integrate into the recipient heart with direct consequences on their terminal differentiation. It has been suggested that the use of electrostimulation would drive stem cells towards differentiating into cardiac-type myogenic cells. This type of differentiation should include the induction of gap junction formation, improving stem cells engraftment and reducing the risk of arrhythmogenic events. (3, 20-22)

Most HF patients present a mechanical and/or electrical ventricular dyssynchrony resulting in increased ventricular wall stress and increased myocardial oxygen consumption. Both are detrimental to cell survival. These are minimized when CRT is activated and could contribute to better cell survival. (8-10) The impact of submitting cell transplant to pulsed or static electrical fields is not very well known and the subject of many studies. In a previous study (23) we have analyzed this impact on cell cultures and found that in vitro electrostimulation of cell cultures was able to induce both morphological and biochemical changes in human mesenchymal stem cells (hMSCs) realizing a shift toward a striated muscle cell phenotype expressing cardiac specific markers. Remarkably, the phenotype change could be achieved without any additional treatment or media supplementation or coculturing conditions defining what we could call a "clean" method to induce cell differentiation. Avoiding coculturing or growth factors use, issues concerning change in cell immunogenicity and biosafety following culturing conditions could be outwitted. Thus, our assumption is that the combination of coordinating the tissue contraction in addition to the application of pulse electrical field would be beneficial for the reasons exposed above. The results of the present study tend to support this hypothesis.

The effects of cell therapy on cardiac function need to be further investigated, analyzing the active contribution of transplanted cells to myocardial contractility, since until now the effects of this therapy seem principally limited to stabilization or reduction of ventricular dilatation (reverse remodelling) and improvement of myocardial viability. Cell transplantation for heart failure still raises several questions regarding cell delivery, cell survival, and cell injection site. The development of strategies for improving cell survival and differentiation, e.g. by using prevascularization, preconditioning procedures like in vitro cell electrostimulation, cell cultures under hypoxia conditions, combination of angiogenic and myogenic stem cells, and tissue engineering approaches seems to be of great interest. (2, 17, 23-28)

Cardiac resynchronization therapy (CRT) is an effective therapy in symptomatic, drug-refractory heart failure patients with prolonged QRS and low ejection fraction. Long-term results of CRT on exercise tolerance and disease progression as evaluated by reversal of maladaptive remodeling process are rather limited, and mostly reported in patients with sinus rhythm. However, it is estimated that less than half of heart failure patients have dyssynchrony and as many as 30% of implanted patients are considered non-responders (29-32).

In spite of progressive improvement of left ventricular function and functional capacity induced by CRT, the benefits of long term benefits can be limited in patients having large post-ischemic myocardial scars. In fact, it seems that the correction of conduction delays is not enough to improve heart failure symptoms when myocardial viability is severely compromised (10, 32-34). For this reason we underwent studies associating cell-based myocardial regeneration procedures with CRT. The use of electrostimulation seems to drive stem cells towards differentiating into cardiac-type myogenic cells. This type of differentiation should include the induction of gap junction formation, improving stem cells engraftment and reducing the risk of arrythmogenic events.

Cardiac tissue engineering emerges as a new therapeutic tool and extends even more the amazing possibilities of stem cell transplantation, becoming a promising approach for myocardial assistance and regeneration (27, 35). For the future, electrostimulation of cell-seeded biological matrix-scaffolds may be a way to generate "bioartificial myocardium".

REFERENCES

1. Chachques JC. Cellular cardiac regenerative therapy in which patients? Expert Rev Cardiovasc Ther 2009;7:911-9.

2. Trainini JC, Lago N, Barisani JL, Masoli O, Mouras J, Chachques JC, y col. Implante cardíaco de mioblastos. Resultado en el seguimiento a cinco años. Rev Argent Cardiol 2008;76:465-9.

3. Lai VK, Linares-Palomino J, Nadal-Ginard B, Galiñanes M. Bone marrow cell-induced protection of the human myocardium: characterization and mechanism of action. J Thorac Cardiovasc Surg 2009;138:1400-8.

4.Kan CD, Li SH, Weisel RD, Zhang S, Li RK. Recipient age determines the cardiac functional improvement achieved by skeletal myoblast transplantation. J Am Coll Cardiol 2007;50:1086-92.

5. Robey TE, Saiget MK, Reinecke H, Murry CE. Systems approaches to preventing transplanted cell death in cardiac repair. J Mol Cell Cardiol 2008;45:567-81.

6. Jolicoeur EM, Granger CB, Fakunding JL, Mockrin SC, Grant SM, Ellis SG, et al; National Heart, Lung, and Blood Institute Cell Therapy Working Group Members. Bringing cardiovascular cell-based therapy to clinical application: perspectives based on a National Heart, Lung, and Blood Institute Cell Therapy Working Group meeting. Am Heart J 2007;153:732-42.

7. Chachques JC, Acar C, Herreros J, Trainini JC, Prosper F, D'Attellis N, et al. Cellular cardiomyoplasty: clinical application. Ann Thorac Surg 2004;77:1121-30.

8. Auricchio A, Prinzen FW. Update on the pathophysiological basics of cardiac resynchronization therapy. Europace 2008;10:797-800.

9. Cazeau S, Alonso C, Jauvert G, Lazarus A, Ritter P. Cardiac resynchronization therapy. Europace 2004;5:S42-8.

10. Nagueh SF. Mechanical dyssynchrony in congestive heart failure: diagnostic and therapeutic implications. J Am Coll Cardiol 2008;51:18-22.
11. Chachques JC, Shafy AB, Duarte F, Cattadori B, Goussef N, Shen L, et al. From dynamic to cellular cardiomyoplasty. J Card Surg 2002;17:194-200.
12. Monnet E, Chachques JC. Animal models of heart failure: What is new? Ann Thorac Surg 2005;79:1445-53.
13. Yankey GK, Li T, Kilic A, Cheng G, Satpute A, Savai K, et al. Regional remodeling strain and its association with myocardial apoptosis after myocardial infarction in an ovine model. J Thorac Cardiovasc Surg 2008;135:991-8.
14. Jessup M, Brozena SC. Guidelines for the management of heart failure: differences in guideline perspectives. Cardiol Clin 2007;25:497-506.
15. Cleland JG, Coletta AP, Abdellah AT, Cullington D, Clark AL, Rigby AS. Clinical trials update from the American Heart Association 2007: CORONA, RethinQ, MASCOT, AF-CHF, HART, MASTER, POISE and stem cell therapy. Eur J Heart Fail 2008;10:102-8.
16. Rajnoch C, Chachques JC, Berrebi A, Bruneval P, Benoit MO, Carpentier A. Cellular therapy reverses myocardial dysfunction. J Thorac Cardiovasc Surg 2001;121:871-8.
17. Chachques JC, Duarte F, Cattadori B, Shafy A, Lila N, Chatellier G, et al. Angiogenic growth factors and/or cellular therapy for myocardial regeneration: a comparative study. J Thorac Cardiovasc Surg 2004; 128:245-53.
18. Carvalho KA, Simeoni RB, Guarita-Souza LC, Francisco JC, Abdelwahid E, Myiague NI, et al. Angiogenesis without functional outcome after mononuclear stem cell transplant in a doxorubicin-induced dilated myocardiopathy murine model. Int J Artif Organs 2008; 31:431-8.
19. Chachques JC. Cardiomyoplasty: is it still a viable option in patients with end-stage heart failure? Eur J Cardiothorac Surg 2009;35:201-3.
20. Iijima Y, Nagai T, Mizukami M, Matsuura K, Ogura T, Wada H, et al. Beating is necessary for transdifferentiation of skeletal muscle-derived cells into cardiomyocytes. FASEB J 2003;17:1361-3.
21. Mills WR, Mal N, Kiedrowski MJ, Unger R, Forudi F, Popovic ZB, Penn MS, Laurita KR. Stem cell therapy enhances electrical viability in myocardial infarction. J Mol Cell Cardiol 2007;42:304-14.
22. Carraro U. Long-term aneurally regenerated skeletal myofibers into heart: how long they could survive and grow by phasic daily FES? Basic Appl Myol 2003;13:53-63.
23. Genovese JA, Spadaccio C, Chachques E, Schussler O, Carpentier A, Chachques JC, et al. Cardiac pre-differentiation of human mesenchymal stem cells by electrostimulation. Front Biosci 2009;14:2996-3002.
24. Hu X, Yu SP, Fraser JL, Lu Z, Ogle ME, Wang JA, et al. Transplantation of hypoxia-preconditioned mesenchymal stem cells improves infarcted heart function via enhanced survival of implanted cells and angiogenesis. J Thorac Cardiovasc Surg 2008;135:799-808.
25. Memon IA, Sawa Y, Miyagawa S, Taketani S, Matsuda H. Combined autologous cellular cardiomyoplasty with skeletal myoblasts and bone marrow cells in canine hearts for ischemic cardiomyopathy. J Thorac Cardiovasc Surg 2005;130:646-53.
26. Cortes-Morichetti M, Frati G, Schussler O, Van Huyen JP, Lauret E, Genovese JA, et al. Association between a cell-seeded collagen matrix and cellular cardiomyoplasty for myocardial support and regeneration. Tissue Eng 2007;13:2681-7.
27. Chachques JC, Trainini JC, Lago N, Cortes-Morichetti M, Schussler O, Carpentier A. Myocardial Assistance by Grafting a New Bioartificial Upgraded Myocardium (MAGNUM trial): clinical feasibility study. Ann Thorac Surg 2008;85:901-8.
28. Schussler O, Coirault C, Louis-Tisserand M, Al Chare W, Oliviero P, Menard C, et al. Use of Arginine-Glycine-Aspartic acid adhesion peptides coupled with a new collagen scaffold to engineer a myocardium-like tissue graft. Nat. Clin. Pract. Cardiovasc. Med 2009; 6:240-9.
29. Conti JB, Sears SF. Cardiac resynchronization therapy: can we make our heart failure patients smarter? Trans Am Clin Climatol Assoc 2007;118:153-64.
30. Young JB, Abraham WT, Smith AL, Leon AR, Lieberman R, Wilkoff B, et al; Multicenter InSync ICD Randomized Clinical Evaluation (MIRACLE ICD) Trial Investigators. Combined cardiac resynchronization and implantable cardioversion defibrillation in advanced chronic heart failure: the MIRACLE ICD Trial. JAMA 2003; 289:2685-94.
31. Doll N, Piorkowski C, Czesla M, Kallenbach M, Rastan AJ, Arya A, et al. Epicardial versus transvenous left ventricular lead placement in patients receiving cardiac resynchronization therapy: Results from a randomized prospective study. Thorac Cardiovasc Surg 2008;56:256-61.
32. Rademakers LM, de Boeck BW, Maessen JG, Prinzen FW. Development of strategies for guiding cardiac resynchronization therapy. Heart Fail Clin 2008;4:333-45.
33. Fauchier L, Poret P, Robin I, de Labriolle A, Giraudeau C, Cosnay P, et al. Different criteria of cardiac resynchronization therapy and their prognostic value for worsening heart failure or major arrhythmic events in patients with idiopathic dilated cardiomyopathy. Am J Cardiol 2006;97:393-9.
34. de Sisti A, Toussaint JF, Lavergne T, Ollitrault J, Abergel E, Paziaud O, et al. Determinants of mortality in patients undergoing cardiac resynchronization therapy: baseline clinical, echocardiographic, and angioscintigraphic evaluation prior to resynchronization. Pacing Clin Electrophysiol 2005;28:1260-70.
35. Trainini JC, Lago N, Chachques JC. La plasticidad en la regeneración cardiaca. Rev Argent Cardiol 2005;73:301-7.