

Rastelli Procedure in Anomalies of Ventriculoarterial Connection Associated with Ventricular Septal Defect and Ventricular Outflow Tract Obstruction

ANA MARÍA SUSANA DE DIOS^{MTSAC,1}

Today, the arterial switch is the surgical technique of choice for patients with simple complete transposition of great arteries and intact interventricular septum, with no other associated anatomic defect.

This technique is based on the anatomic correction of transposition of the great vessels (TGV) described by Jatene in 1975, by transecting the aorta and pulmonary artery with coronary reimplantation, (1) which allows to reconnect the arteries to their respective ventricles.

In previous years, other techniques were used with apparent success (Senning in 1959, and Mustard in 1964); the approach was based on redirecting the pulmonary and systemic venous return at the atrial level, resulting in an oximetric –but not anatomic– correction with the disadvantage that the right ventricle was left in systemic position, which eventually lead to hemodynamic consequences.

Long-term follow-up on these patients showed poor late outcomes due to severe complications related to arrhythmia and RV dysfunction. (2)

In later years, new surgical techniques for patients with transposition associated with other defects emerged.

In 1969, the Rastelli procedure was introduced; it was originally designed for surgery of the truncus arteriosus, but it was soon incorporated for the treatment of patients with anomaly of ventriculoarterial connection (TGV) associated with ventricular septal defect (VSD) and ventricular outflow tract obstruction (PS). (3, 4)

Basically, this procedure consists of tunneling the systemic flow through the ventricular septum towards the aorta (Ao), and then positioning an extracardiac conduit from the right ventricle to the pulmonary artery (RV-PA). Later, it was also used in patients with double outlet right ventricle (DORV) with pulmonary stenosis or previous pulmonary artery cerclage.

Despite the Rastelli procedure has been successfully used over the past 30 years to treat these complex forms of transposition, follow up has showed that late outcomes are suboptimal, with a survival rate at 20 years of only 52% of the cases. (5, 6)

Its main disadvantage is that it requires the inevitable and subsequent reoperations to replace the conduits that become obstructed with the passing of time. (5, 7)

The reconstruction of both outflow tracts has a

key role in the late prognosis of these patients, and that is why now several authors have reviewed the late outcomes of patients operated with the different techniques available, trying to identify the most relevant aspects so as to choose the most favorable technique, depending on the anatomy of the defect.

Three major surgical techniques have been developed for the surgical management of these patients with TGV + VSD + PS: the Rastelli, the Lecompte, and the Nikaidoh procedures.

In 1992, Lecompte et al introduced the Lecompte procedure (REV) (8) for the reconstruction of the pulmonary outflow tract without prosthetic conduit, as an alternative to the Rastelli technique; two years later, Nikaidoh (9) proposed the aortic root translocation and biventricular outflow tract reconstruction.

In the Nikaidoh procedure, both arterial, aortic and pulmonary roots are translocated, and a bovine jugular vein patch is used to repair the stenotic pulmonary artery. Both the Nikaidoh (Figure 1) and the Lecompte (Figure 2) procedures have the same goal: to preserve the competence and potential growth of the native pulmonary valve.

When using the Rastelli procedure, and connection between left ventricle and aorta is performed, the subarterial ventricular septal position –or sufficiently close or distant from the aorta (inlet or remote muscular)– is a relevant aspect for tunneling, as it is pointed out in the study by Villalba et al (10).

The typical conoventricular VSD is more easily tunneled, and flow is less turbulent than in defects unrelated to or away from the outflow tract.

This tunneling is possible as long as there are no chordae that obstruct or hinder it.

Accurate diagnosis of the size and location of the ventricular septal defect and its relation with semilunar and atrioventricular valves is required, (11) and the different types of conus or atypical (bilateral, deficient or displaced) conus, the presence of straddling atrioventricular orifice, leaflets or subvalvular apparatus should be identified.

Even if surgeries are properly performed, reoperating the patient treated with the Rastelli technique is inevitable when an extracardiac conduit was used.

Moreover, the need for reoperation to repair

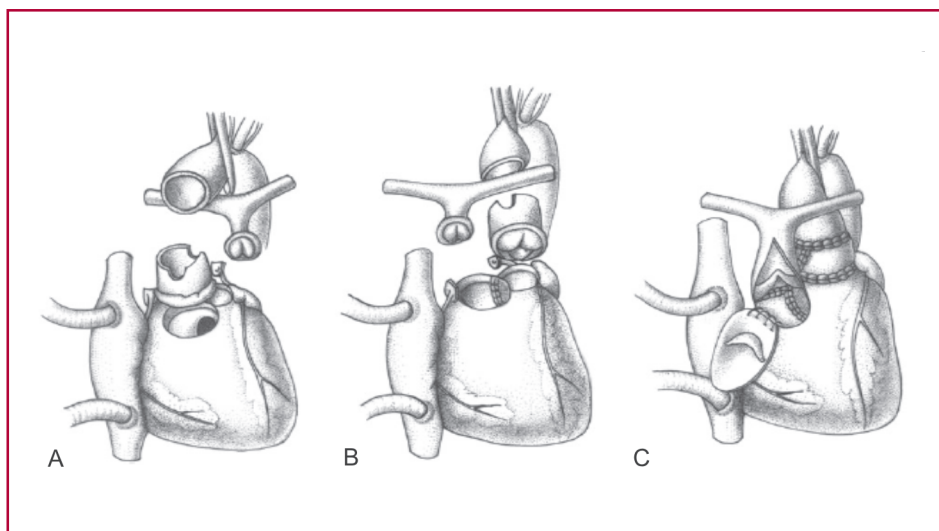


Fig 1. Nikaidoh procedure: Double root translocation technique. **A.** Aortic and pulmonary root manipulation. Both the aortic and the pulmonary root are mobilized and excised. The ascending aorta is transected and the coronary arteries are detached from the aortic sinus. **B.** Lecompte maneuver, which, in both cases, is done by passing the pulmonary artery forward. **C.** Restoration of left ventricle-aorta and right ventricle-pulmonary artery continuity. A single-valved bovine jugular vein patch is used to repair right ventricle outflow tract and enlarge the stenotic main pulmonary artery. Taken from cite 16.

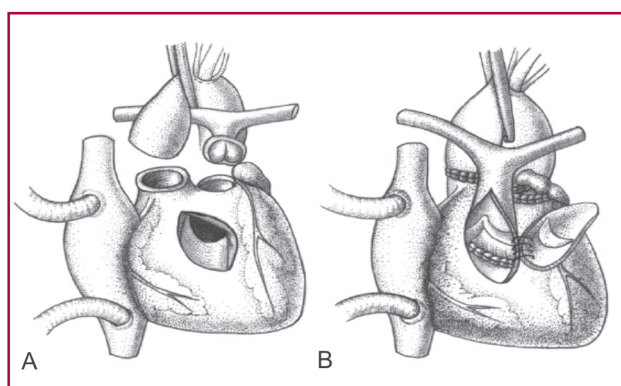


Fig. 2. Modified REV procedure: Pulmonary root translocation technique. **A.** Pulmonary artery root. The ascending aorta is transected above the sinus-tubular junction. **B.** Lecompte maneuver. Restoration of right ventricle-pulmonary artery continuity and left ventricle-aorta. A single-valved bovine jugular vein patch is used to repair right ventricular outflow tract, enlarge the stenotic main pulmonary artery, and restore the competence of the neopulmonary valve. Taken from cite 16.

the tunnel created with the Rastelli procedure –by angulation or obstruction– is strongly related to the complexity of the course of the tunnel.

Reviewing the experience of Kirklin et al, in cases of double outlet right ventricle with subaortic septal defect, only 1% of the catheterized patients had evidence of residual shunts or obstructions that would require reoperation. In contrast, 18% of the patients with complex intraventricular tunnels (noncommitted VSD) would have required reoperation due to significant obstruction or residual leaks. (12)

Reoperation rate due to subaortic obstruction within the surgically created tunnel between the left ventricle and the aorta may be high (20-40%) in patients treated with the Rastelli technique (13) because of the natural tendency for VSD to shrink and the impossibility to create tunnels which would grow.

Risk factors are not clearly defined, but include small

or noncommitted ventricular septal defect, young age at operation, surgical procedure used, and ventricular geometry.

More complex tunnels seem to increase risk factors.

Observations from the study by Villalba et al (10) go along the same lines, since patients who had remote ventricular septal defects underwent surgery with longer time of extracorporeal circulation and aortic clamping, increased early and late mortality rate, greater incidence of reoperations (due to subaortic stenosis, conduit replacement, and retunneling) and arrhythmias in the immediate postoperative period. Another interesting aspect regarding the RV-PA conduit replacement was the greater durability of pericardial conduits, with a lower incidence of reoperation than with homografts.

We agree that, in the presence of a remote septal defect with unfavorable anatomy –which would require complex tunneling–, the Nikaidoh procedure is an interesting option with encouraging results, since it allows for restoration of the outflow tract physiology and hemodynamics with better outcomes; however, later follow-ups are required to draw definitive conclusions.

Double aortic and pulmonary roots traslocation, modified Nikaidoh procedure (14, 15) or modified Lecompte (REV) procedure, versus the conventional Rastelli procedure, have been proposed for these patients.

Hu et al (16) compared their results from 30 consecutive patients with TGV + VSD + PS who alternatively underwent the three procedures mentioned. The postoperative hemodynamics and physiology in the left ventricular outflow tract, as well as ventricular function were normal in the Nikaidoh group, whereas abnormal flow pattern in ventricular outflow tract was noted in both REV and Rastelli groups, especially in cases of complex tunneling.

The Nikaidoh procedure seems to be a better surgical option in terms of cardiac physiology.

The study by Villalba et al seems to ratify and confirm all these observations, in line with those reported by other authors.

BIBLIOGRAPHY

1. Jatene AD, Fontes VF, Paulista PP, de Souza LC, Neger F, Galantier M, et al. *Successful anatomic correction of transposition of the great vessels. A preliminary report.* Arq Bras Cardiol 1975; 28:461-4.
2. Kirjavainen M, Happonen JM, Louhimo I. *Late results of Senning operation.* J Thorac Cardiovasc Surg 1999; 117:488-95.
3. Rastelli GC, Wallace RB, Ongley PA. *Complete repair of transposition of the great arteries with pulmonary stenosis. A review and report of a case corrected by using a new surgical technique.* Circulation 1969; 39:83-95.
4. Rastelli GC, McGoon DC, Wallace RB. *Anatomic correction of transposition of the great arteries with ventricular septal defect and subpulmonary stenosis.* J Thorac Cardiovasc Surg 1969; 58:545-52.
5. Kreutzer C, De Vive J, Oppido G, Kreutzer J, Gauvreau K, Freed M, et al. *Twenty-five-year experience with Rastelli repair for transposition of the great arteries.* J Thorac Cardiovasc Surg 2000; 120:211-23.
6. Dearani JA, Danielson GK, Puga FJ, Mair DD, Schleck CD. *Late results of the Rastelli operation for transposition of the great arteries.* Semin Thorac Cardiovasc Surg Pediatr Card Surg Annu 2001; 4:3-15.
7. Marcelletti C, Mair DD, McGoon DC, Wallace RB, Danielson GK. *The Rastelli operation for transposition of the great arteries. Early and late results.* J Thorac Cardiovasc Surg 1976; 72:427-34.
8. Lecompte Y, Neveux JY, Leca F, Zannini L, Tu TV, Dubois Y, et al. *Reconstruction of the pulmonary outflow tract without prosthetic conduit.* J Thorac Cardiovasc Surg 1982; 84:727-33.
9. Nikaidoh H. *Aortic translocation and biventricular outflow tract reconstruction. A new surgical repair for transposition of the great arteries associated with ventricular septal defect and pulmonary stenosis.* J Thorac Cardiovasc Surg 1984; 88:365-72.
10. Villalba CN, Woloszyn MI, Mouratian MD, Barreta J, Laura JP, Faella H, Capelli H. *Cirugía de Rastelli: impacto adverso de la comunicación interventricular no relacionada con los grandes vasos en los resultados quirúrgicos.* Rev Argent Cardiol 2010; 78:315-22.
11. De Dios AMS, Granja M, Trentacoste L, Damsky Babosa J, Ferrin L, Fischman E y col. *Diagnóstico ecocardiográfico de transposición completa de grandes vasos en el neonato.* Rev Argent Cardiol 1999; 67(Supl II).
12. Kirklin JW, Pacifico AD, Blackstone EH, Kirklin JK, Bargeron LM Jr. *Current risks and protocols for operations for double-outlet right ventricle. Derivation from an 18 year experience.* J Thorac Cardiovasc Surg 1986; 92:913-30.
13. Rychik J, Jacobs ML, Norwood WI. *Early changes in ventricular geometry and ventricular septal defect size following Rastelli operation or intraventricular baffle repair for conotruncal anomaly. A cause for development of subaortic stenosis.* Circulation 1994; 90:II13-9.
14. Yeh T Jr, Ramaciotti C, Leonard SR, Roy L, Nikaidoh H. *The aortic translocation (Nikaidoh) procedure: midterm results superior to the Rastelli procedure.* J Thorac Cardiovasc Surg 2007; 133:461-9.
15. Morell VO, Jacobs JP, Quintessenza JA. *Aortic translocation in the management of transposition of the great arteries with ventricular septal defect and pulmonary stenosis: results and follow-up.* Ann Thorac Surg 2005; 79:2089-92.
16. Hu SS, Liu ZG, Li SJ, Shen XD, Wang X, Liu JP, et al. *Strategy for biventricular outflow tract reconstruction: Rastelli, REV, or Nikaidoh procedure?* J Thorac Cardiovasc Surg 2008; 135:331-8.