

# Severe Mitral Regurgitation After Percutaneous Mitral Valvuloplasty

JULIO C. ECHARTE MARTÍNEZ<sup>1</sup>, JUAN VALIENTE MUSTELIER

Received: 08/11/2009

Accepted: 01/26/2010

**Address for reprints:**

Dr. Julio C. Echarte Martínez  
Calle 302 N° 340 entre 3ra B y  
3ra C  
Santa Fe. Playa  
Ciudad de La Habana, Cuba  
Phone number: 209-8309  
e-mail: jecharte@infomed.sld.cu

## SUMMARY

### Background

Percutaneous mitral valvuloplasty is currently the treatment of choice in patients with rheumatic mitral stenosis with suitable valvular anatomy. After the procedure, the development of severe mitral regurgitation is still a challenge.

### Objective

To determine the causes of severe mitral regurgitation after percutaneous mitral valvuloplasty.

### Material and Methods

A total of 110 percutaneous mitral valvuloplasties were consecutively performed in 107 patients (3 procedures were repeated due to restenosis) at the *Instituto de Cardiología y Cirugía Cardiovascular* in Cuba between June 17, 1998 and June 30, 2004 (106 using the Inoue technique and 4 with the Multi-Track system). The average follow-up was 24.6 months (maximum 72 and minimum 1.93 months). The severity of mitral regurgitation was evaluated according to the regurgitant jet area measured by Doppler echocardiography: mild regurgitation when the area was  $<4 \text{ cm}^2$ , moderate when the area ranged from  $4\text{--}8 \text{ cm}^2$ , and severe when it was  $>8 \text{ cm}^2$ . Left ventriculography was also used to quantify the severity of mitral regurgitation using Seller's criteria. The calibration of Doppler echocardiographic measures of the degree of mitral regurgitation (3 degrees of severity) by angiographic grading (4 degrees) provided the following grading ranges: 1+, mild regurgitation; 2+ and 3+, moderate regurgitation; and 4+, severe regurgitation.

### Results

A total of five severe mitral regurgitations developed after the procedure (4.54%). A mitral valve replacement was necessary in three of them due to rupture of the anterior valve. The remaining two cases are still under medical treatment.

### Conclusion

Multifactorial mechanisms are responsible for the development of mitral regurgitation after percutaneous mitral valvuloplasty, which may occur even in expert hands.

REV ARGENT CARDIOL 2010;78:222-227.

**Key words** > Mitral Valve - Mitral Regurgitation - Balloon Valvuloplasty

## BACKGROUND

Percutaneous mitral valvuloplasty is currently the treatment of choice in patients with rheumatic mitral stenosis in whom valvular anatomy is suitable.

Severe mitral regurgitation is still a challenge, even in expert hands.

The goal of the present paper is to contribute to elucidate the causes of severe mitral regurgitation after percutaneous mitral valvuloplasty.

## MATERIAL AND METHODS

The methodology was defined in the summary. We conducted a prospective, applied research study.

Wilkins score was used to assess mitral valve anatomy.

The severity of mitral regurgitation was evaluated according to the regurgitant jet area measured by Doppler echocardiography (1): we considered mild regurgitation when the area was  $<4 \text{ cm}^2$ , moderate when the area ranged from  $4\text{--}8 \text{ cm}^2$ , and severe when it was  $>8 \text{ cm}^2$ . Left ventriculography was also used to quantify the severity of mitral regurgitation using Seller's criteria. (2)

## Statistical Analysis

Baseline clinical, echocardiographic and hemodynamic data, together with the information regarding the

procedure and the echocardiographic outcomes after percutaneous mitral valve valvuloplasty, were prospectively recorded into a data base and subsequently analyzed. Clinical and echocardiographic follow-up data were obtained from the medical records.

Values were expressed as percentage, mean, standard deviation (SD) and minimum and maximum values.

Continuous variables as mitral valve area and mean mitral gradient were analyzed using the Wilcoxon signed-rank test.

Categorical variables were analyzed with chi-square test.

Analysis was performed in PC using Access, Excel and Microstat software.

A  $p$  value < 0.05 was considered statistically significant.

### Ethical considerations

Patients and their relatives gave their consent to undergo percutaneous mitral valvuloplasty.

### RESULTS

Table 1 shows the general characteristics of patients undergoing percutaneous mitral valvuloplasty.

#### Importance of severe mitral regurgitation complicating percutaneous mitral valvuloplasty

Most patients (92.72%) did not present complications (Figure 1). Five patients (4.54%) developed severe mitral regurgitation and 3 of them needed mitral valve replacement (Figure 2). Tables 2 and 3 show the baseline clinical characteristics of patients who developed severe mitral regurgitation, their outcomes and the strategies used.

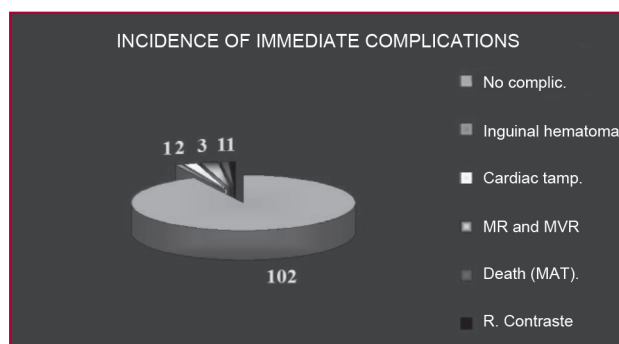
#### Different grades of mitral regurgitation after percutaneous valvuloplasty and outcomes

Most patients did not develop mitral regurgitation after mitral valvuloplasty or only presented mild regurgitation (88.18%). In one patient, the diagnosis of

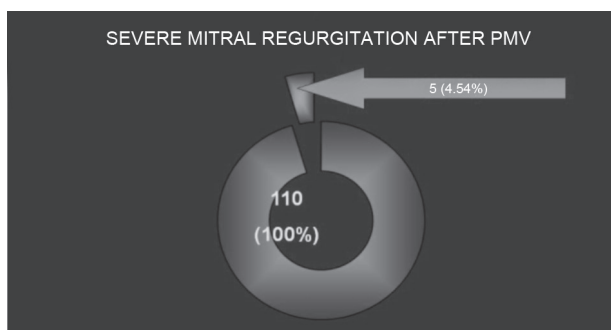
**Table 1.** General characteristics of patients

|                      |               |
|----------------------|---------------|
| Total patients       | 107           |
| Total PMV            | 110           |
| Female gender        | 101           |
| Pregnancy            | 9             |
| Previous SMC         | 5             |
| Age (years)          | 35.2          |
| Wilkins score        | 7.4 ± 1.69    |
| Hospital stay (days) | 1.36 ± 0.92   |
| Follow-up (months)   | 24.57 ± 17.65 |

SMC: Surgical mitral commissurotomy. PMV: Percutaneous mitral valvuloplasty.



**Fig. 1.** Most patients (102, 92.72%) did not present complications. Three patients developed severe mitral regurgitation immediately after the procedure and underwent mitral valve replacement. compic: complications. tamp: tamponade. MR: Mitral regurgitation. MRV: Mitral valve replacement. MAT: Mesenteric artery thrombosis.

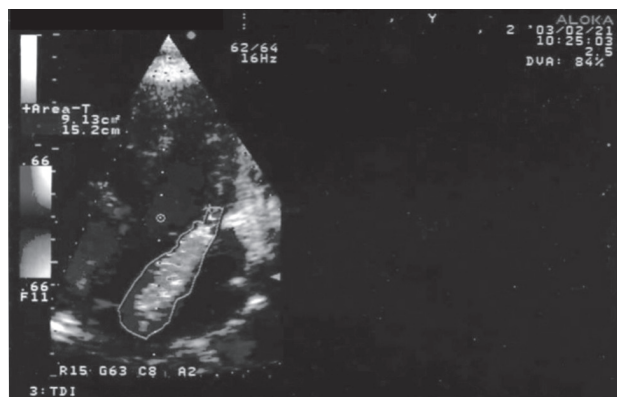

**Fig. 2.** Severe mitral regurgitation occurred in 5 patients (4.54% of all PMV); three of them have been described in Figure 1, and in another two female patients: in one patient mitral regurgitation was severe according to Doppler echocardiography, and moderate based on Sellers criteria (3+) in contrast ventriculography; however, we considered it severe. In the remaining asymptomatic patient, Doppler echocardiography performed at one-year follow-up revealed progression from moderate to severe mitral regurgitation. PMV: Percutaneous mitral valvuloplasty.

severe mitral regurgitation was made with Doppler echocardiography; (Figure 3) the patient had no heart murmur and presented symptoms related to atrial fibrillation with rapid ventricular response. Another patient with moderate mitral regurgitation after the procedure progressed to severe regurgitation one year after, as evidenced by Doppler echocardiography; the patient did not present symptoms (Figure 4).

### DISCUSSION

Mitral regurgitation after percutaneous mitral valvuloplasty is still a challenging problem. Most patients develop mild mitral regurgitation without clinical repercussion; however, the severity of mitral regurgitation increases by 2 grades or greater in about 6% to 19% of patients. (3-5)



Severe mitral regurgitation. Regurgitant jet area : 9.13 cm<sup>2</sup>

**Fig. 3.** Image corresponding to a patient with severe mitral regurgitation that required mitral valve replacement during follow-up. See the regurgitant jet area of 9.13 cm<sup>2</sup>.

Severe mitral regurgitation complicating percutaneous mitral valvuloplasty has been described in association with fibrotic and calcified mitral valves; (6, 7) however, other authors have found this complication in patients with pliable leaflets (8, 9) and a favorable score to undergo the procedure. Our experience is coincidental with the latter observation. In our series, all three female patients that required mitral valve replacement had adequate scores to undergo percutaneous mitral valvuloplasty. Rupture of the anterior leaflet occurred

in the three of them. Thicker and thinner areas were observed. Other authors have reported similar findings. (9-11) The presence of commissural asymmetry of thickness or calcification might predispose to leaflet tearing during balloon inflation, especially in relatively thin portions of inhomogeneously thickened leaflets or in the contralateral commissure. (12)

Impairment of the subvalvular apparatus might generate traction in the point of insertion to the mitral leaflets and produce a tear during balloon insufflation. (10) In several occasions we have found that impairment of the subvalvular apparatus was more severe than that described by echocardiography and it becomes evident when the distal end of the Inoue balloon is entrapped in the subvalvular apparatus during withdrawal from the apex of the left ventricle to the mitral valve plane. Fortunately, the presence of indentations on the surface of the Inoue balloon during inflation indicates that the balloon is wrongly positioned (10) and inflation should be stopped.

The use of oversized balloons may also cause rupture of the valve leaflets. (10) Balloon sizing for percutaneous mitral valvuloplasty using the Inoue method is based on body surface area, (13) while the Multi-Track system considers the diameter of the mitral annulus. (14) We have compared the balloon sizes obtained using body surface area with those according to mitral annulus diameter in the last patients undergoing percutaneous mitral valvuloplasty. In some patients

**Table 2.** Baseline clinical characteristics of patients with severe mitral regurgitation after percutaneous mitral valvuloplasty

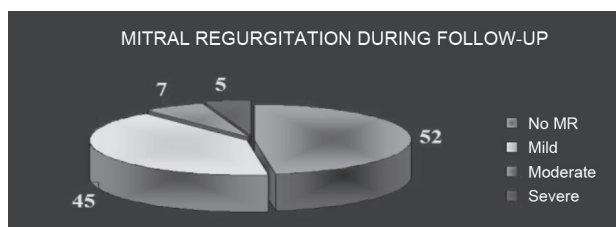
| Patient N° | Age (years) | Gender | Repeated tonsillitis | History of RF | CRF | Previous SMC | FC  | Symptoms          | ECG | Pregnancy | MR (grade) | Wilkins score | Mitral valve area (cm <sup>2</sup> ) | LAD (mm) |
|------------|-------------|--------|----------------------|---------------|-----|--------------|-----|-------------------|-----|-----------|------------|---------------|--------------------------------------|----------|
| 1          | 41          | F      | Yes                  | Yes           | No  | No           | IV  |                   | SR  | No        | Mild       | 8             | 1                                    | 44       |
| 2          | 27          | F      | Yes                  | No            | No  | No           | IV  | APE               | SR  | 24 weeks  | No         | 6             | 0.75                                 | 29       |
| 3          | 45          | F      | No                   | No            | No  | No           | III | APE               | AF  | No        | No         | 7             | 1.1                                  | 39       |
| 4          | 40          | M      | Yes                  | Yes           | No  | No           | IV  | PND<br>Hemoptysis | AF  | No        | Mild       | 9             | 0.8                                  | 49       |
| 5          | 45          | F      | Yes                  | No            | No  | No           | III |                   | AF  | No        | Mild       | 6             | 0.92                                 | 45       |

F: Female. M: Male. RF: Rheumatic fever. CRF: Coronary risk factors. SMC: Surgical mitral commissurotomy. FC: Functional class. APE: Acute pulmonary edema. PND: Paroxysmal nocturnal dyspnea. ECG: Electrocardiogram. SR: Sinus rhythm. AF: Atrial fibrillation. MR: Mitral regurgitation. LAD: Left atrial diameter.

| Patient N° | Age (years) | ECG | Score | LAD | Asymptomatic | Symptomatic | Treatment |
|------------|-------------|-----|-------|-----|--------------|-------------|-----------|
| 1          | 41          | SR  | 8     | 44  |              | CHF         | SVM       |
| 2          | 27          | SR  | 6     | 29  |              | CHF         | SVM       |
| 3          | 45          | AF  | 7     | 39  |              | CHF         | MVR       |
| 4          | 40          | AF  | 9     | 49  | X            |             | Medical   |
| 5          | 45          | AF  | 6     | 45  | X            |             | Medical   |

LAD: Left atrial diameter. ECG: Electrocardiogram. AF: Atrial fibrillation. CHF: Congestive Heart Failure. SR: Sinus rhythm. MVR: Mitral valve replacement.

**Table 3.** Clinical outcomes and treatment of patients with severe percutaneous mitral valvuloplasty



**Fig. 4.** Development of mitral regurgitation after percutaneous mitral valvuloplasty. Note that 52 patients were free of mitral regurgitation after the procedure, and 45 patients developed only mild mitral regurgitation (97 patients between both groups; 88.81% of total patients). One patient with moderate mitral regurgitation progressed to severe asymptomatic mitral regurgitation at Doppler echocardiography one year after. MR: mitral regurgitation.

with relatively small body surface areas the diameter of the mitral annulus was greater and larger balloons could be used, and vice versa. This situation might have an influence on generating mitral regurgitation if large balloon sizes are used. In addition, the use small balloon sizes without considering the diameter of the mitral annulus may produce suboptimal outcomes.

Traditional or Multi-Track double-balloon techniques may have better outcomes in cases of uneven distribution of tension in weaker areas predisposing to rupture of the mitral leaflets, or in the presence of asymmetry of the commissures. Each balloon would dilate one commissure making valve rupture and mitral regurgitation more difficult. (14)

Other authors have reported favorable outcomes in patients with high scores using stepwise balloon inflations with progressive increase in the diameter of the balloon. (15, 16). The velocity of balloon inflation might contribute to rupture of mitral leaflets; slow insufflations produce commissural separation and prevent valve rupture.

It has been suggested that the contrast agent should be diluted in saline solution in a 1:2 ratio. In our opinion, special attention should be paid to this subject, as higher concentrations of contrast agents inside the balloon might exert greater pressure on the valvular apparatus, predisposing to valve rupture.

### Clinical evaluation of mitral regurgitation

Mild to moderate commissural mitral regurgitation is a consequence of mitral valve dilation and has favorable outcomes. (17) On the contrary, severe mitral regurgitation is generally associated with rupture of a leaflet. (18-22) Several clinical variables, such as atrial fibrillation, identify patients who will benefit early from mitral valvuloplasty. (22) However, other variables may play an important role, as 3 of our patients ( $n = 5$ ) had atrial fibrillation with an excellent Wilkins score and were  $< 50$  years (Table 2). Three of the five patients with severe mitral regurgitation needed mitral valve replacement (Table 3). Despite none of these patients required urgent surgery, they

developed progressive impairment of their functional capacity. These patients presented rupture of the anterior leaflet. One patient with moderate mitral regurgitation, evaluated by Doppler echocardiography ( $4.12 \text{ cm}^2$ ), developed asymptomatic mitral regurgitation. Finally, in one patient the diagnosis of severe mitral regurgitation was made with Doppler echocardiography; the patient had no heart murmur and presented symptoms related to atrial fibrillation with rapid ventricular response. Once the arrhythmia was controlled, he remained without symptoms. Some reports have suggested favorable clinical outcomes in patients with a diagnosis of severe mitral regurgitation made by echocardiography. About 10-15% of them remain with severe asymptomatic mitral regurgitation and surgery can be postponed. (10) These cases are not associated with valve rupture. The mechanisms of spontaneous diminution of mitral regurgitation following percutaneous mitral valvuloplasty have been reported. (24) As we have previously mentioned, Figure 3 shows a case of severe mitral regurgitation diagnosed by Doppler echocardiography.

Since 2004 a strategy has been designed to identify the likelihood of developing significant mitral regurgitation following percutaneous mitral valvuloplasty.

### High likelihood of significant mitral regurgitation

- Significant valvular thickening and/or calcification.
- Commissural asymmetry and/or calcification.
- Severe impairment of the subvalvular apparatus.
- Operator-dependent factors (experience)

### Low likelihood of significant mitral regurgitation

- Suitable mitral valve anatomy.

### Balloon sizing

For high likelihood of mitral regurgitation

- Progressive increase in the diameter of the balloon.
- Use traditional or Multi-Track double-balloon techniques. Surgery should be recommended in case of severe commissural calcification.
- In cases of severe disease of the subvalvular apparatus, the presence of indentations on the surface of the Inoue balloon during inflation indicates that the balloon is positioned at the level of the subvalvular apparatus and inflation should be stopped. The Inoue technique (the balloon is advanced from the left ventricular apex across the mitral valve orifice) should be avoided if the balloon is entrapped in the subvalvular apparatus. In this case, once the balloon catheter has crossed the mitral valve, two strategies can be implemented using the pig-tail catheter positioned in the aortic valve plane as a reference. The distal portion of the Inoue balloon, located just in front of the pig-tail catheter, is then insufflated and the waist of the Inoue balloon catheter is positioned in the mitral valve plane, or



contrast media can be injected in the left ventricle through the pig-tail catheter to outline the mitral valve plane.

- D. In-training staff should take special care when preparing the balloon, using contrast agent diluted in saline solution in a 1:2 ratio. Do not insufflate the balloon rapidly or with too much pressure.
- E. As we have corroborated that the balloon size of the Inoue catheter selected according to body surface area (Inoue technique) does not always coincide with the diameter of the mitral annulus, we recommend to measure the diameter of the mitral annulus to avoid using large balloons which might produce valve rupture and severe mitral regurgitation, or small balloons with subsequent suboptimal outcomes.

The homogeneity of leaflet thickening should be evaluated in cases of mitral valves with suitable anatomy.

## CONCLUSION

Multifactorial mechanisms are responsible for the development of mitral regurgitation after percutaneous mitral valvuloplasty which may occur even in expert hands.

## RESUMEN

### Insuficiencia mitral grave posvalvuloplastia mitral percutánea

#### Introducción

La valvuloplastia mitral percutánea es en la actualidad el tratamiento de elección en pacientes portadores de estenosis mitral de etiología reumática si la anatomía es apropiada. La insuficiencia mitral grave posvalvuloplastia continúa siendo un desafío.

#### Objetivo

Determinar las causas de insuficiencia mitral grave posvalvuloplastia mitral.

#### Material y métodos

Se realizaron 110 valvuloplastias mitrales percutáneas en forma consecutiva en 107 pacientes (3 repetidas por reestenosis) en el Instituto de Cardiología y Cirugía Cardiovascular de Cuba, entre el 17 de junio de 1998 y el 30 de junio de 2004 (106 por el método de Inoue y 4 por Multitrack); el tiempo de evolución promedio fue de 24,6 meses (máximo 72 y mínimo 1,93 meses). La insuficiencia mitral se clasificó por ecocardiografía Doppler en leve si el área regurgitante era menor de 4 cm<sup>2</sup>, moderada si era de 4-8 cm<sup>2</sup>, y grave si era > 8 cm<sup>2</sup> y por ventriculografía izquierda según los criterios de Sellers. Para lograr correlación entre la clasificación por ecocardiografía Doppler color de tres grados y la de Sellers (cuatro grados) la insuficiencia mitral 1+ se consideró leve, 2+ y 3+ moderada y 4+, grave.

#### Resultados

Se produjeron cinco insuficiencias mitrales graves posprocedimiento (4,54% del total). Tres de ellas necesitaron reemplazo valvular mitral por rotura de la valva anterior. Las dos restantes se encuentran bajo tratamiento médico.

## Conclusión

Los mecanismos de producción de la insuficiencia mitral posvalvuloplastia mitral percutánea son multifactoriales. Puede ocurrir en manos expertas.

**Palabras clave** > Válvula mitral - Insuficiencia de la válvula mitral - Valvuloplastia con balón

## BIBLIOGRAPHY

- Helmcke F, Nanda NC, Hsiung MC, Soto B, Adey CK, Goyal R, et al. Color Doppler assessment of mitral regurgitation with orthogonal planes. *Circulation* 1987;75:175-83.
- Sellers RD, Levy MJ, Amplatz K, Lillehei CW. Left retrograde cardioangiography in acquired cardiac disease: technic, indications and interpretation of 700 cases. *Am J Cardiol* 1964;14:437-47.
- Vahanian A, Michel PL, Ghanem G, Cormier B, Maroni JP, Iung B, et al. What is the risk of percutaneous commissurotomy in a high volume center? *Circulation* 1991;84:II-204.
- Complications and mortality of percutaneous balloon mitral commissurotomy: a report from the National Heart, Lung, and Blood Institute Balloon Valvuloplasty Registry. *Circulation* 1992;85:2014-24.
- Roth RB, Block PC, Palacios IF. Predictors of increased mitral regurgitation after percutaneous mitral balloon valvotomy. *Cathet Cardiovasc Diagn* 1990;20:17-21.
- Sadee AS, Becker AE. In vitro dilatation of mitral valve stenosis: the importance of subvalvular involvement as a cause of mitral valve insufficiency. *Br Heart J* 1991;65:277-9.
- Reifart N, Nowak B, Baykut D, Satter P, Bussmann WD, Kaltenbach M. Experimental balloon Valvuloplasty of fibrotic and calcific mitral valves. *Circulation* 1990;81:1005-11.
- Cequier A, Bonan R, Crepeau J, Dethy M, Dyrda I, Waters D. Massive mitral regurgitation caused by tearing of the anterior leaflet during percutaneous mitral balloon valvuloplasty. *Am J Med* 1988;85:100-3.
- Essop MR, Wisenbaugh T, Skoularigis J, Middlemost S, Sareli P. Mitral regurgitation following mitral balloon valvotomy. Differing mechanisms for severe versus mild-to-moderate lesions. *Circulation* 1991;84:1669-79.
- Hernández R, Macaya C, Bañuelos C, Alfonso F, Goicolea J, Iñiguez A, et al. Predictors, mechanisms and outcome of severe mitral regurgitation complicating percutaneous mitral valvotomy with the Inoue balloon. *Am J Cardiol* 1992;70:1169-74.
- Padiál LR, Freitas N, Sagie A, Newell JB, Weyman AE, Levine RA, et al. Echocardiography can predict which patients will develop severe mitral regurgitation after percutaneous mitral valvotomy. *J Am Coll Cardiol* 1996;27:1225-31.
- Hernández RA. Resultados a corto y medio plazo de la valvuloplastia mitral percutánea con catéter-balón. Universidad Autónoma de Madrid. Facultad de Medicina. Madrid 1993. (Tesis Doctoral).
- Inoue K, Owaki T, Nakamura T, Kitamura F, Miyamoto N. Clinical application of transvenous mitral commissurotomy by a new balloon catheter. *J Thorac Cardiovasc Surg* 1984;87:394-402.
- Bonhoffer P, Esteves C, Casals U, Tortoledo F, Yonga G, Patel T, et al. Percutaneous Mitral Valve Dilatation with the Multi-Track System. *Catheter Cardiovasc Interv* 1999;48:178-83.
- Vahanian A, Michel PL, Cormier B, Ghanem G, Dadez E, Iung B, et al. A prospective evaluation of stepwise mitral balloon dilatation using the Inoue technique. *Circulation* 1991;84:II-26.
- Feldman T, Carroll JD, Ramaswamy K, Chisholm R, Herrmann H, Pichard A, et al. Effect of stepwise balloon inflations on results and mitral regurgitation after Inoue mitral valvotomy. *Circulation* 1991;84:II-723.
- Krishnamoorthy KM, Radhakrishnan S, Shrivastava S. Natural history and predictors of moderate mitral regurgitation following balloon mitral valvuloplasty using Inoue balloon. *Int J Cardiol* 2003;87:31-6.

18. Essop MR, Wisenbaugh T, Skoularigis J, Middlemost S, Sareli P. Mitral regurgitation following mitral balloon valvotomy. Differing mechanisms for severe versus mild-to-moderate lesions. *Circulation* 1991;84:1669-79.
19. Abascal VM, Wilkins GT, Choong CY, Block PC, Palacios IF, Weyman AE. Mitral regurgitation after percutaneous balloon mitral valvuloplasty in adults: evaluation by pulsed Doppler echocardiography. *J Am Coll Cardiol* 1988;11:257-63.
20. Abascal VM, Wilkins GT, Choong CY, Thomas JD, Palacios IF, Block PC, et al. Echocardiographic evaluation of mitral valve structure and function in patients followed at least 6 months after percutaneous balloon mitral valvuloplasty. *J Am Coll Cardiol* 1988;12:606-15.
21. Utsunomiya T, Patel D, Doshi R, Quan M, Guardin JM. Can signal intensity of the continuous wave Doppler regurgitant jet estimate severity of mitral regurgitation? *Am Heart J* 1992;123:166-71.
22. Schwartz SL, Pandian NG, Kumar R, Katz SE, Kusay BS, Aronovitz M, et al. Intracardiac echocardiography during simulated aortic and mitral balloon valvuloplasty: in vivo experimental studies. *Am Heart J* 1992;123:665-74.
23. Palacios IF, Sanchez PL, Harrell LC, Weyman AE, Block PC. Which patients benefit from percutaneous mitral balloon valvuloplasty? Prevalvuloplasty and postvalvuloplasty variables that predict long-term outcome. *Circulation* 2002;105:1465-71.
24. Cheng TO. Mechanisms of spontaneous diminution of mitral regurgitation following percutaneous mitral valvuloplasty with the Inoue balloon. *Int J Cardiol* 2004;93:329.

#### **Competing interests**

None declared.