

Consensus Statement on Pediatric Cardiology

AUTHORS

Consensus Director:
Dr. Ana de Dios^{MTSAC}

Scientific Secretary:
Dr. Ángela Sardella^{MTSAC}

Technical Secretary:
Dr. Alejandro Peirone^{MTSAC}

Advisory Council:
Dr. Luis Alday^{MTSAC}
Dr. Horacio Faella^{MTSAC}
Dr. Raúl Cayre^{MTSAC}
Dr. Ana Schroh^{MTSAC}

Vocals:
Dr. José Moltedo^{MTSAC}
Dr. Nora Bueno
Dr. Alberto Sciegata^{MTSAC}
Dr. Miguel Granja
Dr. Jesús Damsky Barbosa
Dr. Liliana Ferrin
Dr. Cristian Kreutzer
Dr. Carlos Antello
Dr. María F. Biancolini

**Director of the Area of
Consensus and Rules:**
Dr. Eduardo Sampó^{MTSAC}

DIAGNOSIS

Area of Consensus and Rules of the Sociedad Argentina de Cardiología together with the Council of Pediatric Cardiology of the Sociedad Argentina de Cardiología decided to launch something unpublished until now, the development of a Pediatric Cardiology Consensus. This document will be a material of continuing consultation by cardiologists across the country, especially pediatricians.

Throughout 2010, the pediatric cardiologists led by the Director of the Council of Pediatric Cardiology, Dr. Ana de Dios, gathered together and worked hard to develop the first part of the Consensus that is published today. They had meetings with the Area of Consensus and Rules, which oversaw the work.

Today we are pleased with the publication of the first three chapters, which will be of great help to all cardiologists:

- a) Chapter 1: Coarctation of the aorta
- b) Chapter 2: Therapeutic Interventionism: ductus arteriosus, interatrial communication, interventricular communication
- c) Chapter 3: Physiology of univentricular heart

As in other Consensus, in each one of the subjects, the recommendations are classified according to the degree of reached agreement (Table 1). Likewise, it sometimes refers to the level of evidence on which is based the consensual recommendation (Table 2).

The purpose of this Consensus is to guide mainly to pediatricians for the management of these pathologies, but, of course, it does not intend to supplant the judgement of the physician in charge in front of each patient.

We should not ignore that the implementation of measures may be affected by the availability and experience of the environment in which the patient is.

Dr. Eduardo A. Sampó

Director of the Area of Consensus and Rules of the Sociedad Argentina de Cardiología.

CHAPTER 1 - COARCTATION OF AORTA

This is a broader document about the pathologies or groups of associated cardiovascular pathologies in which conclusions were agreed after an extensive debate among many expert colleagues in the subject matter, the result of the Pediatric Cardiology Council meeting based on available evidence on the subject and the needs and possibilities of the environment.

OBJECTIVES

1. To unify opinions and behaviours before the patient with this cardiovascular disease.
2. To encourage the rational use of diagnostic and therapeutic resources, optimizing the quality of medical care.
3. To develop guidelines and set standards for clinical monitoring, prognostic assessment and the choice of appropriate treatment.
4. To emphasize the role and value of guides as an educational source, promoting through them the interexchange of experiences among experts and encouraging the development of new studies with appropriate methodology in the areas that require it.

Table 1 Classification according to the degree of reached agreement

Class I: Conditions for which there is evidence and/or general agreement in which the procedure or treatment is beneficial, useful and effective. A class I indication does not mean that the procedure is the only acceptable.
Class II: Conditions for which there is conflictive evidence and/or divergences of opinion about the usefulness/efficacy of the procedure or treatment.
Class IIa: Weight of evidence/opinion is in favour of usefulness/efficacy.
Class IIb: Usefulness/efficacy is less well established by evidence/opinion.
Class III: Conditions for which there is evidence and/or general agreement that the procedure or treatment is not useful/effective and in some cases may be harmful.

Table 2 Classification of level of evidence that supports the recommendation

Level of evidence A: solid evidence, from randomized clinical studies or meta-analysis. Multiple groups of population at assessed risk. General consistency in the direction and magnitude of the effect.
Level of evidence B: evidence from a single randomized clinical study or large non-randomized studies. Small groups of populations at assessed risk.
Level of evidence C: expert consensus or opinion and/or small studies, retrospective studies, registries.

- These guidelines will not be dogmatic, but rather flexible and led to Argentine cardiologic community, for which should be adapted to current conditions of planning, provision and use of diagnostic and therapeutic resources in our country.

DEFINITION OF THE PROBLEM IN QUESTION

- Coarctation of the aorta (CoA) is characterized by a narrowing of the aorta in the adjacent area to the junction of the ductus to the descending aorta.
 - The typical CoA is a congenital heart disease that is manifested as a more or less extensive obstruction of the descending aorta.
 - It consists of a disease of the aortic wall with alterations of the elastic tunica, and foci of cystic medial necrosis that extends above and below the area of obstruction.
- CoA anatomical varieties should be identified by Doppler echocardiography as:
- Localized or extensive CoA.
 - Within the localized group: the CoA may be membranous or fibrous type.
 - With / without hypoplastic isthmus or aortic arch (located between the subclavian artery and ductus arterious).

The CoA should be seen as complex congenital heart disease and not simple.

It is not only a narrowing of the distal aorta to left subclavian artery, but a true diffuse arteriopathy and, therefore, with an increased morbidity and a shorter life expectancy, even if it is successfully corrected.

It may be accompanied by aneurysmatic injuries of arterial circle of Willis, hypertension, dilatation of the ascending aorta, recoarctation and premature coronary arteriosclerosis.

CONFIRMATION OF DIAGNOSIS

- By Doppler echocardiography.
- Magnetic resonance imaging (MRI) or computed axial tomography (CAT) allow us to see anatomical details and measure diameters.

Echo-Doppler

- Protrusion of endothelial tissue into the lumen of the descending aorta in posterolateral face, distal to the left subclavian artery and opposite to the ductus.
- Post-stenotic dilatation.
- It is accompanied by hipopulsatility in the descending aorta.
- Hypoplasia of the transverse aorta: a uniform narrowing of the aortic arch segment, with a histologically normal aortic wall. The most frequently form affects the aortic isthmus.
- The pulsed Echo Doppler may record postcoarctation and precoarctation gradient.
- The continuous Echo Doppler quantifies the severity of the coarctation.
- The morphology of the Echo Doppler allows us to see an antegrade high-speed flow which continues during diastole and to be assured of the presence of coarctation.
- The colour Echo Doppler allows us to locate the place of the narrowness.

Severity according to the gradient

- <20mmHg: mild CoA.
- 20 to 40mm Hg: moderate CoA.
- > 40mm Hg: severe CoA.
- Other signs and/or severity criteria: hypertension (HT) to exercise, heart failure and/or severe left ventricular dysfunction (LV). Generally it is accompanied by some other associated pathology. 92% of cases have any other intracardiac or extracardiac concomitant anomalies:
 - Interventricular communication in 44% of cases.
 - Bicuspid aorta (42%) or unicuspid (rare), valvular aortic stenosis (8%) subaortic (8%).
 - Mitral pathology (4%).
 - Interruption of the aortic arch.
 - Hypertrophic, dilated or restrictive cardiomyopathy; in newborns discard endocardial fibroelastosis.
 - Aberrant right subclavian artery (7%).
 - DiGeorge syndrome (17% interruption of type A arch).

TREATMENT OF THE PATHOLOGY ON THE BASIS OF THE BIBLIOGRAPHIC EVIDENCES AND THE PARTICIPANTS' EXPERIENCE AND CRITERIA.

Surgical treatment is the ideal and should be to nullify the obstruction, dry and replace or modify the diseased aortic wall (**Class I indication**).

In newborns, unweaned babies and children under 2 years of age

- Surgical: it is the choice behaviour (**Class I indication**).
- Angioplasty: before native CoA, localized or recoarctation of the aorta after one year of life (**Class IIa indication**).
- It is only indicated in the unweaned baby (**Class III**) for emergencies:
 - a) Severe dilated cardiomyopathy.
 - b) Heart failure and surgical impracticability.
 - c) Lack of collateral circulation (in older than 2 years of age).

Angioplasty is an effective method to solve the complicated forms or in "emergency" in little unweaned baby (localized forms, without hypoplastic isthmus or aortic arch), but it has a high rate of recoarctation (65%) and saccular aneurysms (4.2%).

- It is the choice method in post-surgical CoAs (**Class I indication**).

In > 2 years of age and children weighing <18kg

- Surgical: native CoA, choice behaviour (**Class I indication**).
- Angioplasty: before native CoA, balloon angioplasty (**Class IIa indication**).
- It is the choice method in post-surgical CoAs (**Class I indication**).

In children weighing over 18kg

- Balloon angioplasty, with stent and/or covered stent (**Class IIa indication**).
- In older than 10 years of age: angioplasty with stent before wall defect or disease of elastic tissue (**Class IIa indication**).

Coarctation of the aorta in adults

- The treatment of CoA in adult and adolescent patients in the world, today is strongly oriented to balloon angioplasty in localized membranous and post-surgical forms (**Class I indication**).
- Balloon and stenting angioplasty in extended forms (**Class IIa indication**).
- Balloon and covered stent angioplasty and with PTFE in severe or extreme forms (**Class IIa indication**).
- Indication of intervention: before **resting gradient > 20mm Hg** (**Class I indication**).

Why stent?

- It reduces the need for stretching the wall with balloon to achieve an effective dilation (decreasing the risk of aneurysm).

- It stabilizes the wall, which reduces the risk of dissection.
- It avoids the failure of elastic injuries.
- It modifies the characteristics of the wall above and below the blockage.

Initial criteria for the stent indication

- Mild CoA (<20mm Hg), but with exaggerated hypertensive response to exercise.
- Elastic injuries (postsurgical).
- Relation isthmus / CoA 3/1: PTFE covered stent.
- Age > 45 years: always PTFE covered stent.

Causes

- Only with balloon angioplasty can lead to development of aneurysms, and restenosis.
- The surgery is low risk, but may occur paraplegia and has greater morbidity.
- Angioplasty with stent placement has better results.
- Angioplasty with PTFE covered stent in all adult patients with native or postsurgical coarctation is low risk and has become the choice behaviour.

What would be the contraindications in the adult for his repair by catheterization?

In adult patient, according to the relationship of the stenosis location, are related to:

- The vessels of the neck and
- The coexistence of stenosis of the transverse arch.

FOLLOW UP

At Postintervention follow up the CoA is carried out clinically by the presence of equal pulses in all four limbs, measuring blood pressure in them, and provided by color Doppler echocardiography and always, according to the stent, with MRI or CAT.

Patients undergoing for CoA or percutaneous surgery should be carried out follow up for life even when they are successfully corrected.

It should include an annual assessment by a cardiologist specializing in congenital heart diseases (**Class I, level of evidence C**).

The repair area should be assessed by MRI or CAT at intervals of five years or less, depending on the specific anatomic findings observed before and after the intervention (**Class I, level of evidence C**).

RECOMMENDED BIBLIOGRAPHY

- De Dios A, Olive A, Damsky Barbosa J, Granja M, Trentacoste L, Kreutzer E. Experiencia en el manejo de coartación de aorta (CoAo). Rev Argent Cardiol 2007;75(Supl 2):32.
- Hamdan MA, Maheshwari S, Fahey JT, Hellenbrand WE. Endovascular stents for coarctation of the aorta: initial results and intermediate-term follow-up. J Am Coll Cardiol 2001;38:1518-23.
- Marx GR. "Repaired" aortic coarctation in adults: not a "simple" congenital heart defect. JAAC 2000;35:1003-6.
- Warnes CA, Williams RG, Bashore TM, Child JS, Connolly HM, Dearani JA, et al. ACC/AHA 2008 Guidelines for the Management

of Adults with Congenital Heart Disease: a report of the American College of Cardiology/American Heart Association Task Force on Practice Guidelines (writing committee to develop guidelines on the management of adults with congenital heart disease). *Circulation* 2008;118:e714-833.

– Warnes CA. Bicuspid aortic valve and coarctation: two villains part of a diffuse problem. *Heart* 2003;89:965-6.

– Warnes CA. The adult with congenital heart disease: born to be bad? *J Am Coll Cardiol* 2005; 46:1-8.

CHAPTER 2 - THERAPEUTIC INTERVENTIONISM: DUCTUS ARTERIOSUS, INTERATRIAL COMMUNICATION, INTERVENTRICULAR COMMUNICATION

Conclusions agreed after an extensive debate among many expert colleagues in the subject matter, based on the available evidence on the subject and the needs and possibilities of the environment.

OBJECTIVES

1. To unify opinions and behaviours before the patient with this cardiovascular disease.
2. To encourage the rational use of diagnostic and therapeutic resources, optimizing the quality of medical care.
3. To develop guidelines and set standards for clinical monitoring, prognostic assessment and the choice of appropriate treatment.
4. To emphasize the role and value of guidelines as an educational source, promoting through them the interexchange of experiences among experts and encouraging the development of new studies with appropriate methodology in the areas that require it.
5. These guidelines will not be dogmatic, but rather flexible and led to Argentine cardiologic community, for which should be adapted to current conditions of planning, provision and use of diagnostic and therapeutic resources in our country.

PATENT DUCTUS ARTERIOSUS

Definition of the problem in question

- Persistence of patency of the distal part of the sixth primitive aortic arch after neonatal period.
- This is the third congenital heart disease (CHD) more frequent (Carlgrén et al., 1959).
- It represents 12% of total CHD (Anderson et al., 1954).
- It is predominant in females, with a ratio 3:1 (Zetterquist et al., 1972).
- It has a 4.3% risk of recurrence (Nora et al., 1979).

Classification (Krichenko et al., 1989) (Figure 1)

- Type A (75%), funnel-shaped, developed and narrow aortic ampulla located in the pulmonary end.
- Type B: funnel-shaped, without aortic ampulla.
- Type C: a tubular shape.
- Type D: oval shape, with aortic and pulmonary

ampullae.

- Type E: rare shapes.

Indications for closure

- Closure with device: before patent ductus arteriosus, in > 1 year of age and in > 8kg (**Class I indication**).
 - Surgical closure in premature births and <8kg (**Class I indication**).
 - Other indications for closure with device with the same criteria (1, 2):
 1. Congestive heart failure in patients > 8kg.
 2. Bacterial endocarditis.
 3. Pulmonary arterial hypertension (PAH)*. Reversible with medical treatment.
 4. “Silent” patent ductus arteriosus (**Class IIb**).
- * Patent ductus arteriosus and PAH

Contraindicated (**Class III**) if:

- Pulmonary vascular resistance (PVR) > 8 U Wood.
- The strength ratio pulmonary / systemic resistance (Rp / Rs) > 0.4.
- The systolic pulmonary artery pressure (PAP) is > 60% systolic blood pressure (SBP), although without short circuit from right to left shunt.

To make occlusion test with balloon (hyperoxia - NO - sildenafil).

If with the occlusion test the PAP decreases <60% the SBP, it is possible the closure.

Guide: Anatomy / closure material

- Types A, D, E <2.5mm Gianturco Coils - Flipper - Nit Occlud.
- Types A, D, E > 2.5mm Amplatzer - Nit Occlud PDA-R.
- Types B, C: Amplatzer - Nit Occlud PDA-R.

Limitations for closure with device

They are indications for surgical closure (**Class I**):

- Premature births.
- Large ductus in patients <8kg (difficult by the size of the pods and devices in small anatomical dimensions. Multiple coils generate risk embolizations).
- Window ductus type (danger of excessive protrusion of the devices in the descending aorta and the left branch of the pulmonary artery).
- Large “long tubular” ductus (hard to stabilize the device).

Conclusions

- Percutaneous closure is the method of choice for

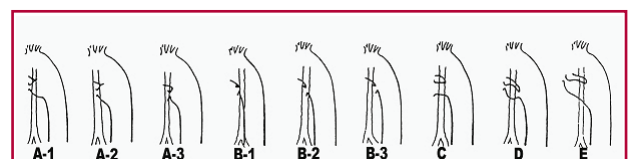


Fig 1. Classification of the ductus arteriosus.

closure of PDA in patients of almost all ages and types of anatomy.

- Fibrous coils in small ductus, coil-devices in small-moderate ductus and devices in moderate-large ductus.

CLOSURE FOR INTERATRIAL COMMUNICATIONS TYPE OSTIUM SECUNDUM

Interatrial communication (IAC) represents approximately 10% of congenital heart disease and is the most common congenital defect in adults.

Transcatheter closure for the treatment of ostium secundum defects is an alternative to traditional surgical closure for both children and adults. (3, 4)

80% of interatrial defects type ostium secundum are passible for closure with device. (5)

Indications

- IAC *ostium secundum* type (**Class I**).
- IAC patent foramen ovale type +
 1. With overload of flow (**Class I**).
 2. Stroke and aneurysm of interatrial septum (**Class IIa**).
 3. Recurrent Stroke:
 - With proper medical treatment and paradoxical emboli (**Class IIa**)
 - And atrial fibrillation (15% have patent foremen ovale closure) (**Class IIa**).
 4. Multiscreen oval fossa with overload (**Class I**).

Required edges

Measurement of edges

- ≥ 7 mm in all the periphery for devices > 10 mm.
- ≥ 5 mm in all the periphery for devices < 10 mm.
- Exception: aortic edge more than 3mm.

Measurement by 2D Echo and transthoracic Echo Doppler in pediatric patients and by transesophageal echocardiography (TEE) in adult patients

Methodology (Figure 2)

- Measure in mm the defect size in view of 4-chambers, minor axis and cava axis.
- Assess the extent of the edges: A coronary sinus (A), posteroinferior edge to inferior venae cavae (B), posterior edge to right superior pulmonary vein (C), posterosuperior edge to superior venae cavae (D), the anterosuperior edge to aorta. (E) and inferior to the atrioventricular valves. (F): to tricuspid (TV) and mitral valve (MV).
- Typically, the best multiplanar angle to see the guidance, the balloon and the device is between 40° and 60° in the mid-esophagus.

Size limit for device and amount to put

- IAC *ostium secundum* type: 40mm.
- Aortic edge limit not < 3 mm.
- How many devices to put: max 2.

We believe that the closure of the defect with the device is the treatment of choice before interatrial communication *ostium secundum* type, always that conditions are given to carry out.

These conditions in adult patients with indication of closure are:

- a. Defect diameter less than 40mm.
- b. Edges of the orifice over 5-7mm (as already mentioned) to the superior and inferior venae cavae, into the coronary sinus, into the right superior pulmonary vein to the atrioventricular valves and more than 3mm in the aortic border.

Exclusion criteria (5) (Class III)

- IAC *ostium primum* type.
- IAC with anomaly in pulmonary venous drainage.
- IAC with soft edges non-continents.
- Insufficient borders.
- Great defect for small atrium.
- Weight less than 10kg (relative).
- Small defects without overload or rate $Q_p / Q_s < 1.5 / 1$.
- They will also be sent to surgery cases with deficient edges (< 5 mm), except the (aortic)anterior edges in which the limit is 3mm.
- CardioSEAL / STARFLEX or Helex devices in children, the device-defect ratio < 1.8 was used as the cutoff value for the indication of percutaneous closure.

Device Types

- There are several types of devices (Figure 3): ASD Amplatzer, Occlutech-Figulla, CardioSEAL, Helex, Solysafe, PFM.
- Amplatzer: we may close defects in diameters from 4mm to 40mm.

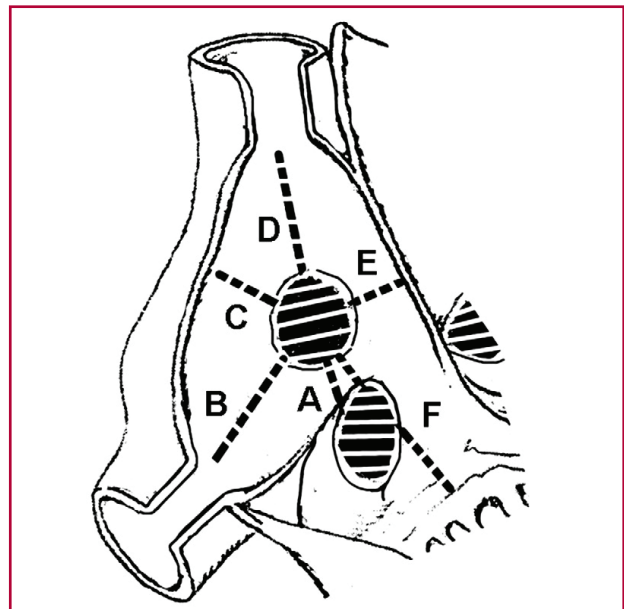


Fig 2. Edges

- Helex: we may only reach 20mm.

The measurement obtained from the defect (measured in 4-chambers in children or by TEE in adults) should be added to the edge size of the central retention device, Amplatzer type(7mm per side) and if the sum is greater than the total length of the septum should be excluded for device and lead to surgery for closure.

In the pediatric population, indications for closure are the same as in adults, but some conditions may differ:

- a. The interatrial septum length should be larger than the occluder disk belonging to the left atrium (excludes the possibility of using very large devices in small patients).
- b. The child should have a weight such that safely accepts placement of the transesophageal transducer to carry out simultaneous color Doppler echocardiogram, however, in cases with good window, the procedure may be carried out with transthoracic echocardiogram, although it is not ideal.

Relative contraindications (Class IIa)

- Defects with Qp / Qs <1.5, without overloaded.

It is indicated its closure before a history of systemic thromboembolic events, stroke, divers and hematologic disease.

Assesment of residual shunt by color Doppler through the imteratrial septum was defined as trivial (<1mm wide of the jet), small (1-2mm wide of colour jet), moderate (2-4mm wide of colour jet) or large (>4mm wide of colour jet).

Over 1,013 consecutive patients with IAC ostium secundum type, 80% of cases were passible to device closure, 10% was ruled out by transthoracic echo and another 10% by intraprocedural: 3.2% for inadequate edges, 4.1 % after measurement with ballon and 1.4% for technical failure. (5)

This study coincides with our experience of 412 patients selected by transthoracic echo, 33 patients (8%) were rejected intraprocedure: 7 by insufficient posteroinferior edge (relative to the inferior venae cavae), 7 insufficient posterosuperior edge, 9 by non soft edges continents, 3 for small left atrium for the device needed to close the defect and 7 large and remote defects.

The lack or deficient posteroinferior, posterosuperior, posterior or superior edge is an absolute contraindication for percutaneous closure of the IAC. (6)

The absence of the anterosuperior edge has not reduced the percentage of successful procedures, but carries the risk of aortic erosion, so it is required a size not less than 3mm to avoid this risk.

The morphology of the defect has not had a significant impact on the outcome of the procedure, since 80% of the cases have been passible to resolution by endovascular catheterization, either to the defect of central, multiple or with multiple fenestration location, but the final outcome depends on adequate knowledge of the morphology for the proper selection of device, and as well as the operator experience for a successful outcome of the procedure.

The Amplatzer device is the only used successfully before IAC ostium secundum type > 30mm and deficient anterosuperior edge, while the CS/SF occluder and cribiform Amplatzer show the best outcomes in multifenestrated defects.

Another alternative to multiple or multifenestrated defects is the use of two similar devices.

Selection Guidelines Device

Small to medium interatrial defects located in the central part of the septum may be treated with CS / SF or Amplatzer.

More recently, Helex devices have obtained similar outcomes.

For larger or medium, but central defects (18-38mm) it is recommended the Amplatzer device.

IAC with deficient anterior edge, only with Amplatzer.

Multifenestrated defects preferably with CardioSEAL (CS) or Solysafe (SF) and recently Amplatzer to cribiform IAC and Helex device. Multiple defects are treated in most cases with two Amplatzer devices.

Given the history of **cerebrovascular accident** (CVA) to demonstrate inverse *shunt* at atrial level: we should remember the embryology: and pathologic anatomy leads us to make tests to prove the reverse *shunt* in the atrium from a via placed in a lower limb, because the flow that comes from the upper limbs and enters through the SVC passes preferentially through the VT in the RV, while coming from the IVC is directed toward the foramen ovale. (7)

Belvis and et al. demonstrated by TEE with agitated bubble test previously, the reverse shunt (right to left) at the foramen ovale level by Valsalva move.

It is possible to estimate that the volume of the *shunt* is normal when within 3 heartbeats after injection

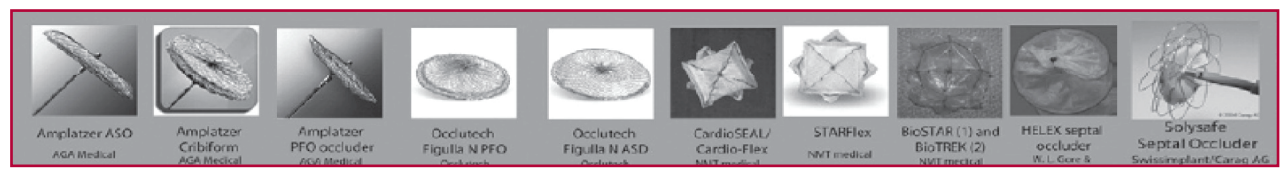


Fig 2. Edges

of saline solution previously agitated that forms microbubbles (MB) identifiable by echocardiography, they are recognized less than 3 MB in the left atrium (LA), small *shunt* when are recognized 3-10 MB, moderate to 11-25 MB and massive > 25 MB.

- Support for the confirmation of these findings to test with transcranial Doppler.
- The transcranial Doppler (8, 9) using the vertebralbasilar and/or right middle cerebral artery and with maneuvers is very useful for the diagnosis of paradoxical embolism.
- 1-10 MB: minimum *shunt*.
- 11-25 MB: moderate *shunt*.
- > 25 MB: massive *shunt*.

Atrial Septal Aneurysm (ASA): defect with *septum* aneurysm protruding above the plane of the atrial *septum* >15mm, (10) associated with atrial *septum* multifenestration (2.5%).

Patent foramen ovale (PFO) and stroke (11)

- It recognizes the presence of PFO in 14.9% of healthy patients.
- The presence of atrial *septum* aneurysm (ASA) is identified only 2.5% of healthy patients. (12)
- The presence of both PFO and ASA, is recognized at 4.2% of the normal healthy population, however, in patients with recurrent stroke, the incidence of PFO and ASA is much higher: 15.2%. (10)

Faced with cryptogenic stroke + PFO + atrial septal aneurysm (ASA) and paradoxical embolism, what is the most convenient behaviour?

Treatment: anticoagulants or antiplatelet agents. **ASA 300 mg + clopidogrel.** In these patients are carried out a clinical follow up and only if they have a new episode, it is indicated the closure device.

The **recurrence** of stroke (CVA) at 4 years before PFO is 2.3%, but with the concomitance of PFO and ASA, recurrence is extremely superior: 15.2%. (10)

Cerebro-vascular accident and percutaneous closure: the closure device has shown a smaller number of events (death, CVA and transient CVA) for those treated with antiplatelet (8.5% vs. 28.3%).

In patients with more than 1 episode, complete closure of PFO showed fewer episodes of recurrent and transient CVA than those treated only with antiplatelet (6.5% vs. 42.6%), although in both cases the difference was less significant compared to those treated with anticoagulation (A: 8.5% vs. 13.3% and B: 6.5% vs. 17.9%).

Before cerebro-vascular accident, the presence of isolated FO is not associated with an increased risk of recidive. But the presence of FO + ASA has a higher risk of recidive in patients <55 years of age, hence, endovascular closure will not be indicated in the first episode of CVA with PFO without ASA.

Indications for closure of patent foramen ovale (PFO) in patients <55 years of age

- **Cryptogenic "recurrent" stroke and PFO** despite adequate treatment with antiplatelet drugs or anticoagulants.
- **"Associated" PFO** with atrial septum aneurysm (ASA) to passage from right to left with maneuvers.

- **PFO with/without ASA and venous thromboembolic disease, with high risk of residue.**
- **PFO with ASA** and patient refusal to anticoagulation therapy.
- **Platypnea-orthodeoxia syndrome.**

Patent-cephalea FO (Class IIa) with aura: the mechanism of action is still debated.

Probably:

- Paradoxical embolism prevent degradation of vasoactive substances into the lungs.
- Hypoxia and ischemia may be the trigger for occipital cephalas.

The incidence of FO with right to left shunt in patients with focal cerebral ischemia is similar (35% vs. 41%). (13)

Foramen ovale in divers

The divers who become symptomatic before the decompression because PFO are recognized in 50% versus 20% in control patients, right to left shunt in divers (14, 15) is significantly higher than in control patients (49 of 59 vs. 12 of 25).

Device versus surgery (16)

1. The complication rate is 7.2% per device versus 24% for surgery (stroke, anemia, infections, etc.).
2. In the rescue surgery for adverse events: 0.83%.
3. No difference between surgical mortality (0.13%) and device closure (0.093%). (17)

Over 1,013 patients, 80% IAC ostium secundum type passible to percutaneous closure, (5) IAC operated (5) (n = 104, 0-14 years): 89% IAC venous sinus /7.2% other residual defects, arrhythmias (2 AVB), 0.8% embolization, mitral valve abnormalities.

Also with large defects in little children weighing less than 10kg it is preferred surgical approach to hemodynamic one because of its lower risk of adverse events, although in favorable cases it is possible hemodynamics closure. (18)

INTERVENTRICULAR COMMUNICATION

Indications

- Qp/Qs. ≥1.5
- Restrictive IVC + hemodynamic repercussion (LVDD > normal).
- Postsurgical residual IVC.
- Small IVC with previous endocarditis.
- Pulmonary hypertension? (good response to treatment with sildenafil).

Exclusion criteria

- Weight <5kg.
- Irreversible pulmonary vascular disease (PVR > 7 Wood).
- Aortic insufficiency with mild coronary prolapse.
- Extension to the inlet.
- Patients who have a contraindication to aspirin or antiplatelet.

It is associated with poor outcomes (19):

- Extension to the inlet.
- Aortic cusp prolapse.
- Weight <10kg (adverse events occur 58.5% vs. 25%).

Perimembranous IVC: morphological aspects of perimembranous defect

- By definition, a part of the edge of perimembranous defect (PM) is the central fibrous body area that holds the bundle of atrioventricular conduction.
- The other edges depend on the extension of the defect: proximity to the aorta, to the mitral or tricuspid valve.
- The recognition of the closeness or distance to these structures is important for device closure.

We do not recommend the closure device to:

- Doubly connected IVC.
- Hypoplasia or absent infundibular septum.
- Deficient aortic and pulmonary margin.
- Not in later IVC.

Nit Occlud indications

- Muscular or perimembranous IVC <8mm.
- Weight > 10kg.
- Qp / Qs > 1.6.
- Endocarditis.
- Progressive aortic insufficiency.
- Normal pulmonary vascular resistance <4 Wood U.

BIBLIOGRAPHY

- Lloyd TR, Beekman RH 3rd. Clinically silent patent ductus arteriosus. *Am Heart J* 1994;127:1664-5.
- Balzer DT, Spray TL, McMullin D, Cottingham W, Canter CE. Endarteritis associated with a clinically silent patent ductus arteriosus. *Am Heart J* 1993;125:1192-3.
- Chessa M, Carminati M, Butera G, Bini RM, Drago M, Rosti L, et al. Early and late complications associated with transcatheter occlusion of secundum atrial septal defect. *J Am Coll Cardiol* 2002;39:1061-5.
- Thomson JD, Aburawi EH, Watterson KG, Van Doorn C, Gibbs JL. Surgical and transcatheter (Amplatzer) closure of atrial septal defects: a prospective comparison of results and cost. *Heart* 2002;87:466-9.
- Butera G, Romagnoli E, Carminati M, Chessa M, Piazza L, Negura D, et al. Treatment of isolated secundum atrial septal defects: impact of age and defect morphology in 1,013 consecutive patients. *Am Heart J* 2008; 156:706-12.
- de Dios A, Granja M, Damsky Barbosa J, Loyarte A, Flores E, Vaccari M y col. Cierre de comunicación interauricular tipo ostium secundum su localización por transesofágico. *Solaci* 2008. *Archivos de Cardiología de México. XIV Congreso de la Sociedad Latinoamericana de Cardiología Intervencionista.* 2008;78(Supl 3):17 Abstract 45.
- Holmes DR Jr, Cohen HA, Ruiz C. Patent foramen ovale, systemic embolization, and closure. *Curr Probl Cardiol* 2009;34:483-530.
- Spencer MP, Moehring MA, Jesurum J, Gray WA, Olsen JV, Reisman M. Power m-mode transcranial Doppler for diagnosis of patent foramen ovale and assessing transcatheter closure. *J Neuroimaging* 2004;14:342-9.
- Del Sette M, Dinia L, Rizzi D, Sugo A, Albano B, Gandolfo C. Diagnosis of right to left shunt with transcranial Doppler and vertebrobasilar recording. *Stroke* 2007;38:2254-6.
- Mas JL, Arquizán C, Lamy C, Zuber M, Cabanes L, Derumeaux G, et al; Patent Foramen Ovale and Atrial Septal Aneurysm Study Group. Recurrent cerebrovascular events associated with patent foramen ovale, atrial septal aneurysm or both. *N Engl J Med* 2001;345:1740-6.
- Holmes D, Cohen H, Katz W, Reeder GS. Patent foramen ovale, systemic embolization and closure. *Current Prob Cardiol* 2004;29:56-94.
- Di Tullio MR, Sacco RL, Sciacca RR, Jin Z, Homma S. Patent foramen ovale and the risk of ischemic stroke in a multiethnic population. *J Am Coll Cardiol* 2007;49:97-802.
- Del Sette M, Angeli S, Leandri M, Ferriero G, Bruzzone GL, Finocchi C, et al. Migraine with aura and right-to-left shunt on transcranial Doppler: a case-control study. *Cerebrovasc Dis* 1998;8:327-30.
- Cantais EP, Louge P, Suppini A, Foster PP, Palmier B. Right to left shunt and risk of decompression illness with cochleovestibular and cerebral symptoms in divers: Case control study in 101 consecutive dive accidents. *Crit Care Med* 2003;31:84-8.
- Dowson A, Mullen MJ, Peatfield R, Muir K, Khan AA, Wells C, et al. Migraine Intervention With STARFlex Technology (MIST) trial: a prospective, multicenter, double-blind, sham-controlled trial to evaluate the effectiveness of patent foramen ovale closure with STARFlex septal repair implant to resolve refractory migraine headache. *Circulation* 2008;117:1397-404.
- Du ZD, Hijazi ZM, Kleinmann CS, Silverman NH, Larntz K. Comparison and surgical closure of secundum atrial septal defect in children and adults: results of a multicenter nonrandomized trial. *J Am Coll Cardiol* 2002;39:1836-44.
- DiBardino DJ, McElhinney DB, Kaza AK, Mayer JE Jr. Analysis of the US Food and Drug Administration Manufacturer and User Facility Device Experience database for adverse events involving Amplatzer septal occluder devices and comparison with the Society of Thoracic Surgery congenital cardiac surgery database. *J Thorac Cardiovasc Surg* 2009;137:1334-41.
- Fischer G, Smevik B, Kramer HH, Bjørnstad PG. Catheter-based closure of atrial septal defects in the oval fossa with the Amplatzer device in patients in their first or second year of life. *Catheter Cardiovasc Interv* 2009;73:949-55.
- Holzer R, de Giovanni J, Walsh KP, Tometzki A, Goh T, Hakim F, et al. Transcatheter closure of perimembranous ventricular septal defects using the Amplatzer membranous VSD occluder: immediate and midterm results of an international registry. *Catheter Cardiovasc Interv* 2006; 68:620-8.

CHAPTER 3 - MANAGEMENT OF PATIENTS WITH UNIVENTRICULAR HEART PHYSIOLOGY

This paper is about the pathologies or group of associated cardiovascular pathologies, in which conclusions were agreed after an extensive debate among many expert colleagues in the subject matter, the meeting outcome of the Pediatric Cardiology Council 2009-2010, based on the available evidence on the subject and the needs and possibilities of the environment.

UNIVENTRICULAR HEARTS

About 10% of congenital cardiac defects belong to the group functionally known as univentricular heart. The natural history is with high morbidity and mortality in neonatal and childhood. Only a minority of patients with an optimal balance between pulmonary and systemic circulation can survive to adulthood without surgical procedure. They are a group of congenital heart defects in which there is only one ventricle sufficiently developed or functional.

The patients with functionally univentricular hearts are a very heterogeneous group of congenital anatomical defects characterized by the dominance of

a ventricle, morphologically either left or right.

Two main concepts help to understand the functionality of these cardiopathies:

1. Anatomical concept

- A single full ventricle: with inflow tract, trabecular portion and outflow tract.
- A rudimentary ventricle, with severe hypoplasia or absence of one or more of the three portions.

2. Physiological concept

- A single ventricle or a single vessel for pulmonary and systemic circulation.
- Total mixed of blood returning to heart.
- To have an adequate O₂ saturation it is necessary to have more pulmonary systemic flow (Q_p/Q_s).

Since these defects are defined by the type of atrioventricular connection, there are three distinctly different anatomical forms (Figure 1):

1. Univentricular atrioventricular connection: where the two atrioventricular valves drain into the predominant ventricle, to what we call double-outlet right (DORV) or left (DOLV) ventricle (DOV). The left morphology is the most common.

2. Absence or severe stenosis of the left or right atrioventricular connection associated with severe hypoplasia of the respective ventricle:

- Tricuspid Atresia (TA).
- Mitral atresia (MA) with hypoplastic left ventricular (LV) or left ventricular hypoplasia syndrome (LVHS).
- Pulmonary atresia with intact septum with hypoplastic right ventricle.

3. Bilateral atrioventricular connection with marked hypoplasia of one of the ventricles (right or left), which makes impossible the biventricular correction:

- Imbalance AV channel (AVC).
- Complex Forms of:
 - a. Transposition of the great vessels (TGV).
 - b. Double outlet of right ventricle (DORV)
 - c. Truncus arteriosus (TA).
 - d. Pulmonary atresia with interventricular communication (PA + IVC).

In short, univentricular connections may be described according to the characteristics of the atrioventricular junction to a single functional ventricle as single ventricle (SV), double-outlet ventricular, single inlet or common inlet.

DEFINING THE PROBLEM IN QUESTION

In univentricular AV connection in double-inlet there are two separate atria and two AV valves (Figure 2).

The inlet septum is absent. Each atrium is connected through an AV valve with the same ventricular cavity, it is more often with left ventricular morphology, which is the dominant ventricle and a posterior location on anterior chamber [undeveloped ventricle of right type, output camera (OC) or rudimentary camera (RC)].

Excluding the mitral and tricuspid atresias,

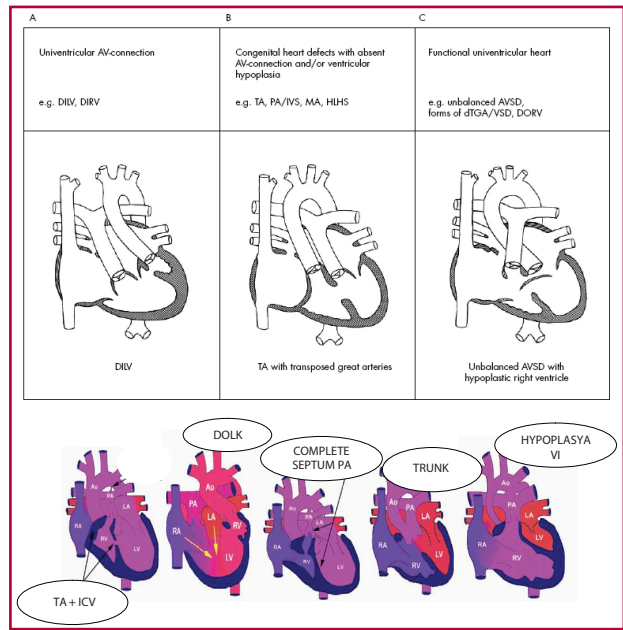


Fig 1. Anatomical forms.

this form is the most common in univentricular AV connections.

Large vessels are usually not normopposite (only 15% of cases).

In the **left single ventricle**, the connection with the right accessory chamber is carried out through a bulboventricular foremen, which often is small generating vessel stenosis related to the outlet chamber: pulmonary stenosis to normopposite vessels or subaortic stenosis to transposed vessels (most often).

It is defined bulboventricular wide foramen and is not restrictive when its surface is greater than 2 cm²/m² of corporal surface or when the relationship bulboventricular/ring foramen aortic diameter is greater than 0.8. Because the bulboventricular foramen does not have a circular shape, but tends to be elliptical, the calculation of the area should consider this aspect, so it is recommended to measure in it two diameters in two orthogonal planes by echocardiogram and then calculate the area and indexed by corporal surface area.

To **double-inlet left ventricle, the ventriculoarterial connection (VA)** usually is **discordant**, with the aorta emerging from a accessory chamber of right type. This type of ventriculoarterial connection was observed in 90% of cases of double-inlet left ventricle. In these cases, the bulboventricular foramen may be small, restrictive or semi-restrictive to flow, generating a subvalvular aortic obstruction and it is usually associated with coarctation of the aorta (CoA). Therefore, before a left univentricular heart is expected to find complete transposition of the great vessels (90%) with pulmonary stenosis (PS) in 40% of cases, subaortic stenosis (ESubAo) in a similar

percentage and CoA at 15 % (Figure 3).

It is less frequently that the great vessels may be normopposite (15% of cases) and the connection to the accessory right chamber through the restrictive bulboventricular foramen generate pulmonary stenosis.

When there is an AV valve atresia, right in the case of tricuspid atresia or left in ventricular hypoplasia left univentricular syndrome, univentricular AV connection is called of **single input** type (single patent AV valve). These forms of univentricular hearts are the most common and correspond to the **hypoplastic left heart syndrome** and **tricuspid atresia**.

In cases of univentricular AV connection for **common inlet**, the two atria are connected by a **single AV valve to main ventricle** that usually has right morphology and there is a small posterior accessory chamber. This type of univentricular heart is frequently observed in heterotaxy syndrome. When there is a wide interventricular communication (IVC) of input septum, the AV valve ring may not be properly aligned with the interventricular septum, so that the valve area straddles the interventricular septum. In these cases the 50% rule is applied: it is required that more than 50% of valve area in question, is connected with the adjoining chamber to allot it as input to that ventricle. This situation occurs in the **AV canal imbalance**, in which one ventricle is hypoplastic compared to the other, which is the “dominant.” In two thirds of the cases with atrioventricular canal imbalance, the dominant ventricle has right morphology. If the relationship between the AV valve areas (area of AV left/area valve of the right AV valve) is less than 67% to cases of dominant RV, the patient should be considered for univentricular repair.

There are other forms of congenital heart disease in which, despite the presence of two ventricles, biventricular correction carries a high risk due to **severe hypoplasia of one of the ventricles**, as some cases of pulmonary atresia with intact

interventricular septum, d- transposition of the great vessels with IVC and right ventricular hypoplasia and some forms of criss-cross hearts.

From the above, within the univentricular heart group, the following defects are included: mitral or tricuspid atresia, hypoplastic left ventricle, some forms of pulmonary atresia with complete interventricular septum, atrioventricular canal seriously imbalance, transposition of the great arteries with interventricular communication and right ventricular hypoplasia and others, such as certain varieties of criss-cross hearts in two floors or with straddling of atrioventricular valves that even with two ventricles, present severe technical-surgical risk for its biventricular correction.

UNIVENTRICULAR PHYSIOLOGY

1. The single ventricle is always overloaded, because it keeps the pulmonary flow (Qp) and the systemic one (Qs).
2. If cyanosis is mild, heart failure is higher.
3. If cyanosis is mild to moderate, heart failure is mild.
4. If cyanosis is severe, heart failure is higher, but by hypoxemia acidosis.

Clinical determinants according to pulmonary flow ratio (Qp) / systemic (Qs)

Table 1 shows the clinical determinants of the clinic according to ratio Qp / Qs.

Required conditions for treatment

For the success of this mitigation it is necessary that candidates have **adequate function of single ventricle without significant failure of AV valve or valves, low pressure and pulmonary resistance in normal lung architecture, absence of obstruction in the systemic circulation and an unrestricted interatrial communication(IAC)**. This mitigation is carried out in the best way in the preschool years, so until then the therapeutic objective will be focused on providing an adequate pulmonary vascular flow, with preservation of pulmonary arterial pressure and resistance within normal limits and with control of the signs of low cardiac output.

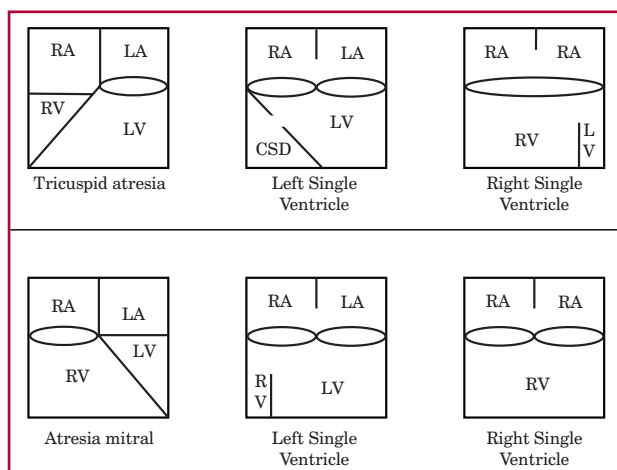


Fig 2. Univentricular AV connection types.

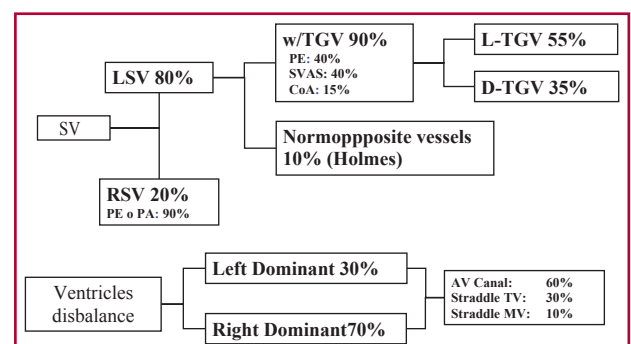


Fig 3. Frequency of univentricular heart defects.

CLINICAL STATEMENTS

Clinic

Univentricular heart clinic or single ventricle depends on:

- The presence of blockage in the outflow tract of the pulmonary flow (Q_p) or systemic (Q_s).
- The relationship between pulmonary and systemic resistance.
- The balance between pulmonary and systemic flow.
- The presence of preferential flows that reduce the mixture (> hypoxia).

You can find two different clinical situations in the context of a univentricular heart (Figure 4):

- A. Patients that suffer *mainly* from cyanosis.
- B. Patients that suffer *mainly* from heart failure, with associated mild to moderate cyanosis.

A. Patients who suffer mainly from cyanosis

Cyanosis is the most obvious clinical manifestation.

The patient presents a few days or weeks of life with progressive cyanosis as ductal constriction occurs.

Pulmonary outflow obstruction may be located at different levels (subvalvular, valvular or supra-valvular pulmonary) or, in cases where the pulmonary artery arises from a hypoplastic ventricular cavity with a communication between it and the main cavity, the obstruction may be at that level (bulboventricular foramen).

B. Patients who suffer mainly heart failure

Patients with pulmonary vascular flow unrestricted and without significant subaortic obstruction usually occur within a few weeks of life with signs of congestive heart failure that progresses as pulmonary vascular resistance decreases.

They present unsaturated mild tachypnea. It must be implemented for medical treatment of heart failure.

Those with aortic occlusion (due to restrictive bulboventricular foramen) associated or not with CoA, are present with poor peripheral perfusion and signs of low cardiac output when the ductus closes.

DIAGNOSIS

By Doppler echocardiography, it should be carried out sequential segmental analysis: the type of AV connection, the systemic and pulmonary venous drainage, size of inter atrial defect and other associated defects.

In the presence of stenosis or atresia of the atrioventricular valves they should be assessed the anatomy and function of these and the extent and hemodynamic impact of those injuries.

To Estimate pulmonary pressure and assess in associated injuries their location and severity: with pulmonary stenosis, the size of the pulmonary branches, with aortic stenosis location and severity, the position of the aortic arch and its integrity, the

Table 1. Clinical determinants according to Q_p / Q_s

Q_p/Q_s	PE	Saturation	Cyanosis	Heart Failure
> 3	No	90%	+/-	+++
2	Mild	85%	+	++
1	Moderate	80%	++	+
< 1	Severe	< 70%	+++	-
< 0.5	Very severe	< 60%	+++	++

position and size of supra-aortic trunks and the presence and size of the ductus.

Catheterization is carried out if echocardiography does not well define main aspects of the anatomy in order to decide the therapeutic behaviour. Catheterization contributes to providing information on situs, venous connections (systemic and pulmonary), AV connection and AV valves, ventricular morphology, venous obstruction (systemic and pulmonary), AV connection and relationships of the great vessels, pulmonary artery anatomy (Nakata, McGoon, arborization, collateral or fistulas, etc.) position of the aortic arch, ventricular function (Fey, rate mass / volume). It allows therapeutic procedures:

Faced with **restrictive interatrial defect**: septostomy (Park) or septoplasty (balloon).

- Faced with **ductus**: stent in dependent cardiopathies on ductus.
- In **pulmonary arteries**, dilatation (balloon - stent).
- In **small LSVC**: unblocking, closure (coils) of **collateral Ao-P**.
- In fenestration: closure or dilatation.
- In **pulmonary valve**: dilation and closure (residual flow) before CoA: dilation.

TREATMENT

The therapeutic objective for these patients is aimed at creating a balance of pulmonary and systemic flow to achieve a saturation of 82% concurrent with a degree of heart failure and mild cyanosis. It is created a system in which the systemic venous return flows through the lung, while pulmonary venous return makes it by the systemic blood pressure, avoiding volume overload and pressure and unsaturation in addition to protecting the single ventricle, atrioventricular valve and lung.

Therapeutic objective

- To create a system in which the systemic venous return actually passes through the lung and, the pulmonary venous return accesses to the periphery improving the saturation through the right ventricle bypass or the Fontan-Kreutzer surgery.
- $Q_p / Q_s = 1 / 1$.
- Normal systemic saturation without volumetric overload or pressure.
- Protection of single ventricle and lungs.

Fig. 4. Clinical situations in the univentricular heart.

CLINIC	
WITH PE: 60% (SIMILAR T. DE FALLOT)	WITHOUT PE: 40% (SIMILAR IVC + HF + HP)
Cyanosis Squats Without thoracic deformities Normal peripheral pulses Palpable R2 (L-Aorta), reinforced and single SS ejection (PE): > intensity and > duration: > Qp, < severity, < cyanosis Absent: > severity or PA SC = ductus o collaterals	Minimal or absence cyanosis Dyspnea, subcostal indrawing, malnutrition. Thoracic deformity. Active precordium. Congestive HF Diminished femoral pulses: CoA y palpable (?) reinforced and single (L-Aorta) R2 SS ejection + (relative PE) SS mesocardium ++ (ESubAo) R3 w/MDS- Gallop (apex) Venocapillary hypertension (pulmonary edema): pathology MV w/small IAC or obstructive TAPVC

- Protection of the AV valve.
Surgical treatment involves three stages. This requires recognizing what is the patient's hemodynamic status, mainly if he suffers from cyanosis or heart failure or both.
The three stages are:
- Newborn to 6 months of age: to regulate pulmonary and systemic flow. Prevention of pulmonary hypertension and cardiomyopathy.
- Six months to 2 years of age: to derive the venous return from the SVC to the pulmonary artery (Glenn).
- From age 2 years to derive the venous return from the SVC and the IVC to the pulmonary artery (Fontan-Kreutzer).

A. Patients who suffer mainly from cyanosis

In the first stage

Initial treatment is aimed at management of hypoxia, initially to preserve ductal patency when the pulmonary flow is dependent on the ductus (for example, pulmonary atresia or critical pulmonary stenosis associated with univentricular heart).

By the administration of **prostaglandins** to maintain ductal patency. In these cases it is also important to ensure a good mix at atrial level and if it is not appropriate, it should be carried out a **balloon atrioseptostomy**.

Then, the pulmonary flow is assured by carrying out a **systemic-pulmonary anastomosis** modified Blalock-Taussig type or central anastomosis. In some highly selected patients, after 3 months may be carried out a bidirectional cavopulmonary anastomosis (bidirectional Glenn).

B. Patients who suffer mainly heart failure

In the first stage

Initial treatment is directed to **medical** management of heart failure. The Rashkind atrioseptostomy has the same indications as in the previous group.

The natural mitigation is **surgical banding (Class IIa)** of the pulmonary artery trunk. The pulmonary artery banding is usually performed between 2 and 8

weeks of age to protect the pulmonary vascular bed of hypoflow.

Otherwise they will develop irreversible histological changes characteristic of hypertensive pulmonary vascular disease. In addition to restricting the vascular pulmonary flow, trunk banding of the pulmonary artery decreases the pressure in the pulmonary circuit, preparing the patient for the second and third surgical stages.

This procedure is problematic in patients with aorta, which is originated from a hypoplastic ventricle.

The pulmonary artery banding may be carried out only if the normal aortic arch and bulboventricular foramen is wide. If there is CoA and bulboventricular foramen is wide (its surface is greater than 2cm²/m² of the corporal surface or relationship bulboventricular foramen diameter / aortic annulus exceeds 0.8), it may be carried out surgical repair of coarctation and pulmonary artery banding. Banding should be adjusted enough to ensure a low distal pulmonary pressure at 4 months of life, at the time of bidirectional Glenn. It may also be opted for the transection and suture of the pulmonary artery by adding a systemic-pulmonary anastomosis (**Class I or IIa**).

When aortic arch is normal and there is subaortic blockage, it may be chosen between the Damus-Kaye-Stansel intervention (terminolateral anastomosis between the pulmonary trunk and ascending aorta associated with systemic-pulmonary anastomosis) or carried out the extension of the bulboventricular foramen and the chamber of subaortic outlet accompanied by banding the trunk of the pulmonary artery (**Class I**).

In neonates with left ventricular hypoplasia syndrome, Norwood modified surgery is carried out as a first surgical stage (**Class I**). The objectives of the Norwood modified procedure are: to provide adequate systemic cardiac output by releasing the left ventricular outflow blockage, maintain the right functional single ventricle as the systemic ventricle and to ensure adequate pulmonary flow.

Newborn and unweaned baby: balance Qp / Qs

1. Severe lung blockage with cyanosis subclaviopulmonar anastomosis.

2. Unobstructed pulmonary heart failure, pulmonary artery banding.
3. With aortic valve blockage and pulmonary hypertension with heart failure: the Norwood surgery (aortopulmonary anastomosis and subclavian pulmonary anastomosis).

Mortality with neonatal palliative procedures is significant and requires careful follow up to control, especially the distortion of the pulmonary branches, pulmonary pressure level, the poor or excessive functioning of systemic-pulmonary fistulas, the occurrence of aortic recoarctation and subaortic blockage development.

Hybrid procedures (banding of both branches with stent placement in the ductus) have shown benefit for the recovery of patients in shock, patients with diminutive ascending aorta, septic patients or patients who have a contraindication to extracorporeal circulation, as bridge to the Norwood surgery in the first month of life or as initial mitigation followed by a combination of Norwood and Glenn surgery at 4-6 months.

In some cases of restrictive foramen ovale that does not provide an adequate balance Q_p / Q_s , it is used the Rashkind balloon septostomy.

C. Patients who suffer from heart failure and cyanosis

In this category are the following types of patients:

1. Those with single ventricle with obstructive TAPVR (usually visceral heterotaxias) with or without pulmonary stenosis. In these patients with a very poor prognosis should be corrected TAPVR (preferably with sutureless technique) and regulate pulmonary flow.
2. In patients with mitral atresia, restrictive foramen ovale or intact interatrial septum with or without hypoplasia syndrome of LV should be carried out an extension of FO by hemodynamics or surgery and palliation, according to their pathology of base.
3. In the single ventricles with double inlet ventricle with transposed vessels in R and complete transposition physiology should be carried out a FO extension by hemodynamics or surgery to improve mixing and palliation according to the size of the bulboventricular foramen.

Those with the Ebstein anomaly with neonatal symptomatology: in these patients with a very poor prognosis should be corrected the Ebstein anomaly or carry out the RV exclusion with the Starnes technique.

Treatment

For the success of a palliative procedure it is necessary that candidates have a **proper function of single ventricle without significant failure of AV valve or valves, low pressure and pulmonary resistance in normal lung architecture, absence**

of blockage of the systemic circulation and an unrestricted interatrial communication (IAC).

This mitigation is carried out in the best way in preschool age, so until then the therapeutic objective will be focused on providing adequate pulmonary vascular flow, with preservation of pressure and pulmonary vascular resistance within normal limits and with control of low cardiac output signs (Figure 5).

Second stage (bidirectional-Glenn cavopulmonary anastomosis)

The second stage in the management of patients with univentricular AV connection is a bidirectional cavopulmonary anastomosis or modified bidirectional Glenn shunt, where the right superior vena cava (SVC) is connected directly to the right pulmonary artery.

In a patient with bilateral SVC, each SVC is anastomosed to the respective homolateral PA.

Bidirectional Glenn surgery should be carried out between 3 and 6 months of life.

Objectives

1. To Preserve adequate pulmonary vasculature in the third stage and eliminate the overload volume of single ventricle (40% of the systemic venous return circulates to the pulmonary vascular tree without going through the single ventricle).
2. Preoperative assessment: anatomical and functional assessment of the patient.
3. To Ensure the presence of an interatrial communication (IAC) is not restrictive.
4. To discard obstructive pulmonary venous drainage, which in case to exist they would complicate cavopulmonary shunt functionality and the patient's life.

To indicate bidirectional Glenn surgery in a patient with anatomic or functional single ventricle, the patient should have:

- Sinusal rhythm
- Right ventricular function;
- Absence of significant insufficiency of AV valve because it increases the end diastolic pressure of single ventricle, and this causes pulmonary hypertension;
- Absence of obstruction in the pulmonary venous drainage;
- Absence of obstruction in the pulmonary arteries (PA mean pressure below 18mm Hg);
- Low pulmonary vascular resistance (less than 4 irreversible Wood/m² units);
- Unrestricted IAC.

It should also be evaluated the presence of recoarctation in those cases associated with coarctation of the aorta corrected during the neonatal stage. Gradients above 15mm Hg should be treated aggressively to preserve ventricular function optimally.

Systemic venous return anomalies should be assessed, such as the existence of a left SVC, in which case there will be to derive it to the left pulmonary

branch as well do the same with the right superior venae cavae (bilateral superior cavopulmonary connection (BSCPC)).

It is also important to rule out the existence of an interruption of the inferior venae cavae with continuation through the azygous vein, since in these cases we should preserve the azygous to carry out BSCPC.

This analysis anatomophysiological required to consider the patient with single ventricle candidate to the Glenn surgery is carried out through the complementation of different imaging techniques such as Doppler echocardiography, magnetic resonance imaging (MRI) and cardiac catheterization.

Supplementary tests

Doppler echocardiography, MRI and cardiac catheterization.

They provide the presurgical information necessary before the achievement of the cavopulmonary shunt:

- Assessment of the anatomy of the pulmonary branches: it is extremely important to know their size, there are several indexes to determine it.
- Assessment of pressure and pulmonary vascular resistance: mean pulmonary pressures over 18mm Hg or pulmonary vascular resistance greater than 4 non-irreversible Wood/m2 U contraindicate the achievement of the Glenn surgery.
- Assessment of ventricular function.
- Assessment of the AV valve: severe valvular insufficiency may require surgical intervention at the time of the Glenn procedure.
- Assessment of the presence of recoarctation in the case prior systemic outflow blockage: gradients over 15mm Hg should be treated aggressively to preserve ventricular function optimally.
- To discard systemic venous return anomalies (existence of a left superior venae cavae, in which case will be to derive it to the left pulmonary branch as well do the same with the right superior venae cavae (bilateral superior cavopulmonary derivation.)

- It is also important to rule out the existence of an interruption of the inferior venae cavae with continuity through the azygous vein, since in these cases we should preserve the azygous vein to carry out the surgery (double bilateral Glenn: BSCPC).
- Rate Q_p / Q_s .

Second stage of palliative surgery

Partial bypass of the RV: (Glenn Classic, bidirectional Glenn).

- Pulsatility: antegrade (with or without banding)
- Contralateral ASP (especially plastic pulmonary branches)

Restrictive BVF: Stansel or partial resection.

High risk factors (Class III)

- Nakata <120 mm2/m2.
- Severe ventricular dysfunction.
- Severe stenosis of pulmonary branches with distal hypoplasia.
- Significant insufficient AV valve (closure if the other is normal: annuloplasty, valve replacement).

Third surgical stage (total bicavopulmonar anastomosis: Fontan-Kreutzer)

In all patients with univentricular AV connection, the final common via for surgical palliation is the modified Fontan-Kreutzer procedure or total bicavopulmonar anastomosis (**Class Ia**), in which the entire systemic venous return drains passively into the pulmonary arterial circuit and the functional ventricle is reserved as a systemic pump.

This mitigation is carried out best in the preschool years, so until then the therapeutic objective will be focused on providing adequate pulmonary vascular flow, with preservation of pulmonary arterial pressure and resistance within normal limits and with control of the low cardiac output signs.

The palliative surgical procedure reduces ventricular overhead and eliminates arterial oxygen unsaturation in a patient with univentricular heart. This concept may be achieved through different surgical techniques and basically consists on that only the pulmonary venous flow returns to the functional single ventricle, while the entire systemic venous flow, avoiding the right ventricle, reaches the pulmonary circuit.

At present, the patient who already has a bidirectional Glenn surgery (2.nd stage) is connected him/her the flow of inferior venae cavae (IVC) to the right pulmonary artery, either through a lateral atrial tunnel or an interatrial conduit or through an extracardiac conduit. These non-valved conduits connect the suprahepatic IVC to the pulmonary arteries. Generally a fenestration remains, which is a small intentional IAC 3 to 5mm which allows a continuous circuit from right to left to atrial level, generating a slight unsaturation of arterial blood. The objective of the fenestration is to provide a continuous preload to the systemic ventricle. Before the third

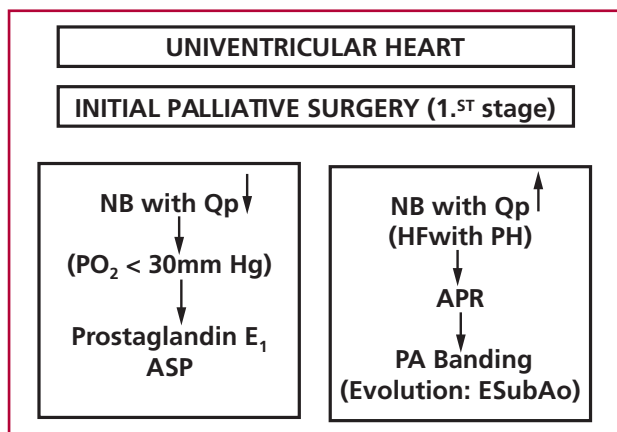


Fig 2. Initial palliative surgery.

surgical stage, the functional single ventricle “full” by both the pulmonary venous return as by the systemic (IVC). Fenestration makes easier the transition to the type **Fontan- Kreutzer** circulation .

The disadvantages of fenestration is a discrete arterial unsaturation of the patient and an increased likelihood of thromboembolic events.

For this third stage surgery will be successful, the patient should observe the following requirements:

1. Normal systolic ventricular function (preserved ventricular contractility).
2. Normal diastolic ventricular function, low ventricular filling pressure and high ventricular distensibility.
3. Unrestricted interatrial communication (IAC).
4. Low pulmonary arterial pressure and low pulmonary vascular resistance.
5. Absence of significant regurgitation of the atrioventricular and sigmoid valves
6. Absence of obstruction to the inlet and outlet of venous systemic or pulmonary return:
 - a. Absence of mitral stenosis or pulmonary veins.
 - b. Absence of valvular or subvalvular aortic stenosis.
 - c. Absence of coarctation of the aorta.
 - d. Absence of pulmonary hypertension.
 - e. Absence of stenosis in the circuit and cavopulmonary connections.
7. Sinusal rhythm or atrioventricular synchrony.

Total right ventricular bypass, definitive palliative surgery (Class I)

Choussat criteria

- 4-15 years of age.
- Sinusal rhythm.
- Normal drainage of the venae cavaes.
- Normal volume of the RA.
- PA mean pressure <15mm Hg.

- PAR <4 U/m2.
- Rate PA / Ao > 0.75.
- Normal ventricular function.
- Without MI.
- Without injuries shorts.

Surgical techniques

1. Auriculopulmonar

- Fontan-Kreutzer

2. Bicavopulmonar

- Intra-atrial lateral tunnel
- Central Tunnel
- Extracardiac tunnel

What would be in theory the ideal RV total bypass? Anyone that could offer most of the following requirements:

1. To have the heart chambers without overload of pressure or volume.
2. Not to have sutures in the right atrium to prevent arrhythmias.
3. maintain a laminar flow without losing energy.
4. to be biocompatible and go with somatic growth.
5. To maintain a homogeneous distribution of pulmonary blood flow to both lungs.
6. To keep the atria at low pressures to prevent hypertrophy, enlargement and atrial fibrosis with the consequent development of tachyarrhythmias.
7. To keep the coronary venous return at low pressures.
8. To maintain a central venous pressure less than 12mm Hg.

From the foregoing, it follows that the total bypass with extracardiac conduit would be the best technique that better fulfill with these expectations.

In table 2 are detailed the surgical risk factors in the total bypass of RV

Table 2. Total bypass of RV: VD: surgical risk factors

Factors	Absence (Class I)	Moderate (Class IIa)	High (Class IIb)
Age	< 2 years	< 1.5 years	< 1 year
PA mean pressure	< 15mm Hg	15-18mm Hg	> 18mm Hg
McGoon	> 2.4	1.8-2.4	< 1.8
Nakata	> 250 mm2/m2	200-250 mm2/m2	< 200 mm2/m2
PAR	< 2 Word U	2-3 Word U	> 3 Word U
RA Pressure- LA Pressure	< 6mm Hg	6-12mm Hg	> 12mm Hg
PFD	< 10mm Hg	10-14mm Hg	> 14mm Hg
Fey	> 60%	45-60%	< 45%
AV failure	No - Mild	Moderate	Severe
Heterotaxy	No	Polysplenia	Asplenia
Banding	No	Yes	Yes + stenosis branches
PE	No	Light-moderate	Severe
Restrictive BVF	No	< 30mm Hg	> 30 mm Hg
Left AV valve	Normal	Stenosis	Atresia

Poor outcomes in the total bypass of RV before:
Transpulmonary gradient (RA Pr – LA Pr) > 6mm Hg:
 1. Poor development of the pulmonary arteries.
 2. Pulmonary embolism.

Giant right atrium due to:

1. Arrhythmias.
2. Thrombotic complications.
3. Compression of the right pulmonary veins.

Short circuit from right to left:

1. Leak in a patch.
2. Fenestration.
3. Pulmonary AV fistula.
4. Small IAC.

Thromboembolism:

1. Pulmonary: atrial flutter.
2. Systemic IDC

Arrhythmias:

1. Sinusal nodule dysfunction.
2. Junctional tachycardia,
3. and supraventricular.

Protein-losing enteropathy (by chronic venous hypertension):

1. Hypoproteinemia.
2. Hypoalbuminemia.
3. Chronic edema.
4. Pleural and pericardial effusion.
5. Ascites.

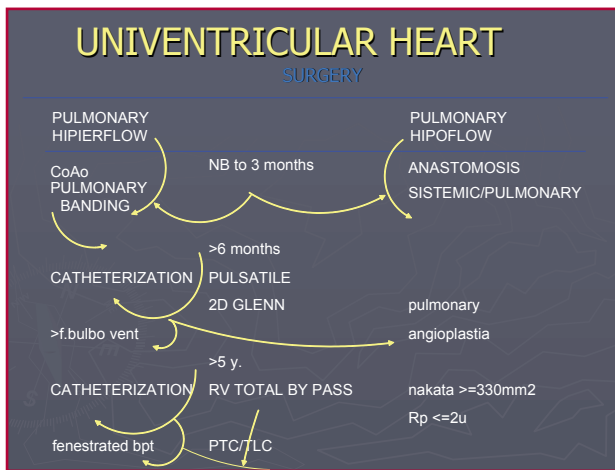


Fig 6. Surgery in univentricular heart.

UNIVENTRICULAR HEART Behaviour- Algorithms			
Op ↑		Op ↓	
AOS	SURGERY	AOS	SURGERY
<4 years: no	banding + CoA	no	ASP
yes	ASP + Stansel with Ao hypoplasia arch Ao + Ao arch	yes	ASP with Ao hypoplasia arch + Ao arch
4 months-2 years: prior catheterization		4 months-2 years: prior catheterization	
Pulsatile 2D Glenn Stansel Plastic AV valve		Pulsatile 2D Glenn BVF resection Plastic pulmonary branches	
2-5 years (according to saturation): prior catheterization Total Bypass with/without fenestration			

Fig 7. Behaviour - univentricular heart algorithms.

BEHAVIOUR- ALGORITHMS IN THE UNIVENTRICULAR HEART (Figures 6 and 7)

- <4 months: Banding/ anastomosis / septostomy.
- 4 months and 2 years: partial bypass.
- 2-5 years: total bypass.

RECOMMENDED BIBLIOGRAPHY

- Anderson PA, Sleeper LA, Mahony L, Colan SD, Atz AM, Breitbart RE, et al; Pediatric Heart Network Investigators. Contemporary outcomes after the Fontan procedure: a Pediatric Heart Network multicenter study. *J Am Coll Cardiol* 2008;52:85-98.
- Blafox AD, Sleeper LA, Bradley DJ, Breitbart RE, Hordof A, Kanter RJ, et al; Pediatric Heart Network Investigators. Functional status, heart rate, and rhythm abnormalities in 521 Fontan patients 6 to 18 years of age. *J Thorac Cardiovasc Surg* 2008;136:100-7.
- Bove EL, de Leval MR, Migliavacca F, Balossino R, Dubini G. Toward optimal hemodynamics: Computer modeling of the Fontan circuit. *Pediatr Cardiol* 2007;28:477-81.
- Ghanayem NS, Berger S, Tweddell JS. Medical Management of the Failing Fontan. *Pediatr Cardiol* 2007;28:465-71.
- Huddleston CB. The Failing Fontan: Options for surgical therapy. *Pediatr Cardiol* 2007;28:472-6.
- Hirsch JC, Ohye RG, Devaney EJ, Goldberg CS, Bove EL. The lateral tunnel Fontan procedure for hypoplastic left heart syndrome: Results of 100 consecutive patients. *Pediatr Cardiol* 2007;28:426-32.
- Kaulitz R, Hofbeck M. Current treatment and prognosis in children with functionally univentricular hearts. *Arch Dis Child* 2005;90:752-62.
- Ohye RG, Bove EL. The Fontan procedure: Three decades of progress. *Pediatr Cardiol* 2007;28:421.