

Aortic valve replacement using Ross procedure: 13-years experience

PABLO ROURA, CAROLINA SALVATORI, CLAUDIO E. LÓPEZ, EDUARDO GUEVARA^{MTSAC}, CARLOS RODRIGUEZ CORREA,
ROBERTO R. FAVALORO^{MTSAC}

Received: 19/11/2009
Accepted: 01/07/2010

Address for reprints:

Dr. Pablo Roura
Belgrano 1746- 1º Piso
(1093) Ciudad Autónoma de
Buenos Aires
e-mail: proura@ffavaloro.org

SUMMARY

Background

Ross procedure for the treatment of aortic valvular heart disease has been used for decades. Despite its promising results, certain doubts have limited its massive use; being durability one of the main causes of concern.

Objective

To analyze Ross procedure results in our center.

Material and Methods

This is a retrospective cohort study. A number of 198 patients underwent Ross surgery from July 1995 to May 2008; in all of them the technique of aortic root replacement was used. Associated events with the valve were analyzed by the method of Kaplan-Meier. For the analysis of the variables log-rank test and Cox model were used.

Results

Mean age was 39 ± 13 years; 77% were male. The surgery was indicated due to aortic stenosis (58%) and aortic regurgitation (42%). Hospital mortality was of 2.5% (5 patients). The 10-year follow-up was complete in 93% for the first 165 patients. Survival at 10 years was of 94.8% (HF 95% 89-98). Freedom of endocarditis at 10 years was of 95% (HF 95% 84-98) and the freedom of events related to the valve at 10 years was of 91% (HF 95% 86-96). Five patients needed reoperation, 4 of them due to autograft dysfunction and other valves disease.

Conclusions

Ross surgery is a surgical technique with a low rate of events at 13 years and should be considered for the treatment of aortic valve disease in chosen patients.

REV ARGENT CARDIOL 2010;78:485-491

Key words

> Aortic valve replacement- Ross surgery- Ross procedure- Pulmonary autograft.

BACKGROUND

Aortic valve replacement by the patient's own pulmonary valve, associated with the implantation of a pulmonary homograft to restore the right ventricle outflow, was described by Donald Ross in 1967 as a surgical alternative for the treatment of aortic valvular disease. (1) This technique provides the only living valve replacement and with potential capacity of reproducing most of the functions of a native aortic valve. It shows a good hemodynamic profile, low risk of endocarditis, low thrombogenicity, no anticoagulant treatment needed, and autograft growth capacity. (2-4) There are certain doubts that have limited its massive use. First, it is a technically demanding procedure.

Second, there are some doubts regarding the durability of the autograft, with the future possibility of reoperations. (5-7) Several surgical techniques for the implantation of the pulmonary autograft have been described and maybe this explains the differences announced regarding complications. (8-10)

The objective of this study was to evaluate hospital results and the remote evolution of Ross surgery in our center.

MATERIAL AND METHODS

Population

This is a retrospective cohort study. The information was transferred to a cardiovascular database by two encoders

and validated by medical control and auditory.

Between July 1995 and May 2008, a total of 198 patients underwent Ross procedure with aortic root replacement technique. Mean age was 39 ± 13 years and 77% (n= 152) of the patients were male. All the patients were informed about the surgical procedure. The clinical characteristics of the population are summarized in Table 1. The surgery was indicated based on the recommendations for the management of valvular diseases, elaborated by the American College of Cardiology and the American Heart Association (ACC/AHA). (11) The aetiology of the aortic valvular dysfunction is described in Table 1.

Echocardiographic evaluation and follow-up

All the patients were evaluated before the surgery by transthoracic colour Doppler echocardiography with Sonos 1500, 2500 and 5000 equipment (Hewlett Packard, Andover, MA, USA). In all the patients an intraoperative transesophageal echocardiogram was performed.

During the follow-up, the patients were clinically evaluated by transthoracic colour Doppler echocardiography between the first and sixth postoperative month, and then annually. The echocardiographic evaluation included a detailed morphologic and functional analysis of the pulmonary autograft and homograft. Regurgitation severity was defined: 0= absent; 1= mild; 2=moderate; 3= moderate-severe. A regurgitation >2 was considered as a significant autograft and homograft dysfunction, and a pulmonary peak gradient > 30mm Hg as homograft stenosis.

Hospital mortality was defined as it occurred during hospitalization or within 30 days of the surgery. The

events considered in the follow-up were death, freedom from reoperation, freedom from autograft and homograft dysfunction and freedom from endocarditis or thromboembolic events.

The follow-up at 10 years was complete in 93% for the first 165 patients.

Surgical technique

In all the patients the aortic root replacement technique was used, with separated Tycron 4-0 stitches at aortic ring level. (30) For the reimplantation of the coronary ostium a continuous Prolene 5-0 or 6-0 suture and continuous 5-0 suture for aortic anastomosis was used. For the pulmonary homograft a continuous Prolene 4-0 suture for the proximal suture and Prolene 5-0 for the distal one was used. During the first phase of this series non specific efforts to fit the aortic ring diameter with the pulmonary autograft were made. In later phases particular attention was paid on the adequate fitting of these structures, according to Elkins technique. (12, 13) Pulmonary valves were replaced with cryopreserved pulmonary homografts.

The surgery was carried out using extracorporeal circulation with membrane oxygenator, moderate hypothermia (28 °C) and myocardial protection with antegrade and retrograde blood cardioplegia.

All the patients, except 14, were operated by the same surgeon; this allowed a consistent graft technique.

Statistical analysis

Numerical variables are expressed as mean and standard deviation. Categorical variables are described in relative proportions. To compare proportions the chi-square method was used. Associated events with the valve (death, reoperation, endocarditis, thromboembolism and bleedings) were analyzed by Kaplan-Meier method.

RESULTS

Surgery and early evolution

In 22 patients it was necessary to carry out an associated procedure to the one of aortic valve replacement (Table 2). Clamp aortic time was of 140 ± 30 minutes and extracorporeal circulation 187 ± 44 minutes.

Mortality at 30 days was of 2.5% (5/198). Three of the patients who died had antecedent of previous cardiac surgery and one of them was undergoing his

Table 1. Population clinical characteristics (n=198)

Characteristics	n (%)
Age (years)*	39 ± 13 (16-65)
Male	152 (77)
NYHA Functional class	
- I-II	144 (73)
- III-IV	54 (27)
Previous cardiac surgery	14 (7)
LV Ejection fraction (%)*	55 ± 12 (30-70)
- Normal	38 (19)
- Mild	126 (64)
- Moderate	34 (16)
- Severe	-
Aortic valve disease	
- Stenosis	115 (58)
- Regurgitation	83 (42)
Etiology	
- Bicuspid aortic valve	148 (75)
- Rheumatic	19 (10)
- Active endocarditis	4 (1,2)
- Prosthetic dysfunction	6 (3)
- Myxomatous	4 (1,2)

* Values expressed as mean ± standard deviation (range)

Table 2. Combined or isolated Ross surgery (n = 198)

Surgery	n (%)
Ross (isolated)	148 (90)
Ross + myomectomy	3 (1,5)
Ross-Konno	3 (1,5)
Ross + mitral plastic	3 (1,5)
Ross + mitral and tricuspid plastic	1 (0,5)
Ross + mitral valve replacement	1 (0,5)
Ross + mitral commissurotomy	2 (1)
Ross + closure of IVC	1 (0,5)
Ross + ascending aorta replacement	3 (1,5)
Ross + MRS	5 (2,5)

IVC: Interventricular communication. MRS: Myocardial revascularization surgery.

second reoperation. In two patients death was due to cardiogenic shock and multiple organic failure, while in the remaining patients death was related to sepsis. One of them evolved with mediastinitis and endocarditis, with echocardiographic documentation of homograft and autograft affection. Postoperative complications are shown in Table 3.

Remote follow-up

Median follow-up was of 69.8 months. Survival at 10 years was of 94.8% (HF 95%) (Figure 1). Freedom from events related to the valve was of 91% (HF 95%, 86-96) at 10 years. (Figure 2).

Late events

During the follow-up 5 patients died. One of these deaths was related to the valve in one patient rehospitalized due to early bacterial endocarditis 45 days after Ross surgery. Echocardiographic compromise of the homograft and autograft was observed. The patient was reoperated and died during the postoperative due to refractory sepsis. The causes of those deaths unrelated to the valve included a suicide after 2 years of the surgery, one sudden death after Ross surgery and one pneumonia. It was impossible to establish the cause of death in one patient.

There were no thromboembolic events or bleedings during the follow-up period.

Freedom from endocarditis at 10 years was of 95% (HF 95%, 84-98). Four patients developed homograft bacterial endocarditis. One of them is the patient mentioned above in whom homograft and autograft compromise was detected. The three remaining patients showed exclusive homograft affection and good evolution with medical treatment was observed.

Autograft function

Freedom from significant autograft dysfunction was of 89.9% (HF 95%, 82-97) at 10 years (Figure 3). While analyzing the incidence of this complication,

Table 3. Early postoperative complications (n = 198)

Complication	n (%)
Reoperation (bleeding)	12 (7)
Low cardiac output syndrome	24 (12)
Intraaortic balloon counterpulsation	7 (3,5)
Complete AV block	10 (5)
Permanent pacemaker	2 (1)
Cerebrovascular accident	2 (1)
ARF	25 (12)
Dialysis	2 (1)
Prolonged ventilation	12 (7)
Sepsis	2 (1)
Mediastinitis	1 (0,5)

Complete AV block: Complete atrioventricular block. ARF: Acute renal failure

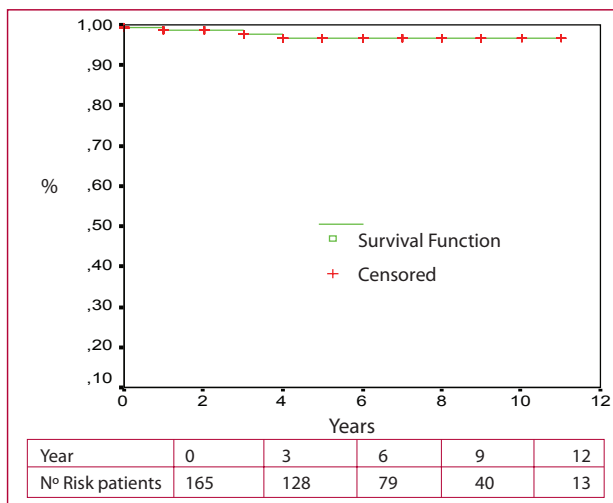


Fig. 1. Remote survival

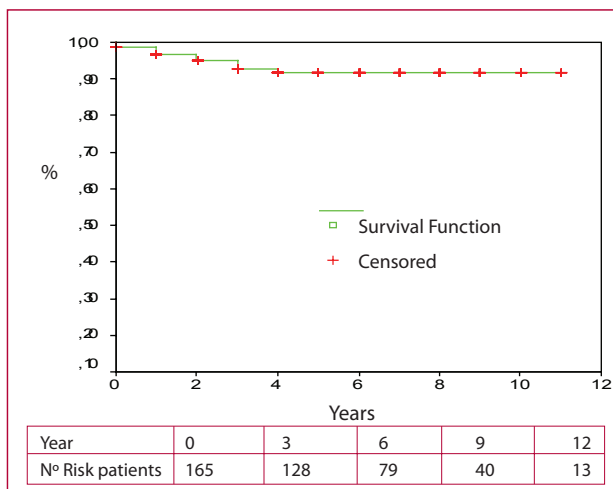


Fig. 2. Survival with no events associated with the valve (death, reoperation, endocarditis, thromboembolism, bleeding).

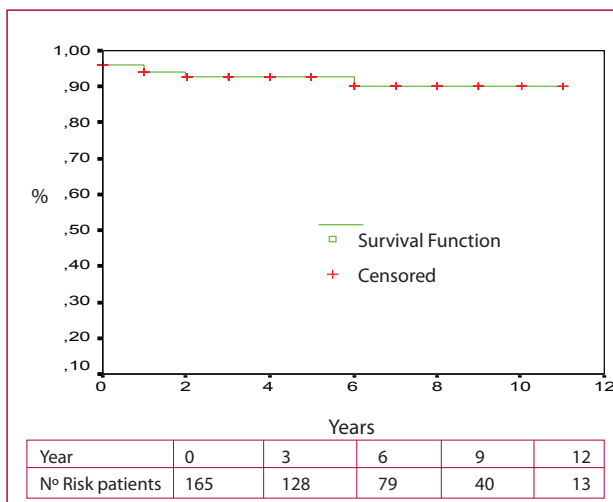


Fig. 3. Survival with no significant autograft dysfunction

according to the preoperative valvular affection, it was evident that those patients with aortic regurgitation showed higher tendency to develop it than those with aortic stenosis. The difference did not reach statistical significance ($p=0.063$), probably due to the low rate of such event. Only one patient with aortic stenosis developed significant dysfunction of the autograft during the follow-up. Ross surgery had been performed in 1998 and the significant autograft dysfunction was seen in the second year after the surgery. The exact mechanism of the autograft dysfunction was impossible to establish and in that moment the diameter of the aortic neo-root was of 40 mm. The patient refused the indication of reoperation and now he is classified as functional class II of the NYHA, under psychiatric treatment with diagnosis of bipolar disorder. The six remaining patients had aortic regurgitation as preoperative valve disease. One of them had a traumatic lesion of the pulmonary valve during Ross surgery. Although the autograft was repaired before the reimplantation in aortic position, the patient evolved with severe aortic regurgitation after the third month of the surgery and was reoperated after a year of the first procedure. Three of the patients who underwent Ross surgery in the initial phase of this study, during which it was not essential the fitting of aortic and pulmonary rings, developed early and significant autograft dysfunction. Two of these patients refused the indication of reoperation and were not taken into account in the follow-up. The third of them is now asymptomatic, active, with preserved left ventricular systolic function and under strict cardiologic and echocardiographic monitoring. The remaining two patients developed late aortic regurgitation, which was associated with progressive dilatation of the aortic neo-root; both of them were reoperated. A valve preservation procedure was ruled out due to the finding of significant valvular affection in both cases. One of them was reoperated 22 months after Ross surgery and a Bentall-DeBono procedure was performed due to the finding of thickened and retracted valves. In the remaining patient a Freestyle prosthesis was implanted 11 years after Ross surgery and at the moment of the surgery the patient presented ring dilatation and thickening of the free edge of the autograft valves.

Taking into account the technical complexity of Ross surgery, and therefore, the level of learning it requires, the incidence of significant dysfunction of the autograft was compared in terms of time. Between 1995 and 1999 a total of 78 patients were operated, while between 2000 and 2006 a total of 87 patients were operated. Although the observed differences did not have statistical significance, the incidence of significant autograft dysfunction was higher in the initial phase of our series, maybe related to the considerable level of learning needed.

No association between the development of significant autograft dysfunction and the presence of bicuspid aortic valve was observed.

Homograft function

During the follow-up period, four patients presented a peak gradient at the level of the homograft > 30 mm Hg. None of them showed symptoms and no evidences of right ventricular dysfunction during a stress echo with exercise were observed. In one patient, in whom the homograft was replaced, the indication of reoperation was related to the development of severe mitral regurgitation and no to homograft stenosis. The decision of replacement during the mitral surgery was based on the presence of a peak gradient of 32 mm Hg, associated with a diameter of the pulmonary homograft of 21 mm at body level, which was of 26 mm at the moment of implantation. Other three patients developed significant homograft dysfunction, with moderate to severe pulmonary insufficiency. None of them needed reoperation, they are asymptomatic and under strict monitoring.

Reoperation

Freedom from reoperation at 10 years was of 95% (HF 95%, 84-98). During the follow-up, five patients needed reoperation. One of them had an iatrogenic lesion of the pulmonary valve during Ross surgery; it was patient number 8 of the series and it was considered a technical mistake. Two patients developed severe dysfunction of other valves with no evidences of autograft or homograft severe affection; both of them with diagnosis of rheumatic valve disease. The first patient developed recurrent mitral regurgitation, after a reparative surgery at the moment of Ross surgery two years before. In the second a progression of the rheumatic valve disease with the development of severe tricuspid and mitral insufficiencies was observed. When the reoperation was indicated, the autograft showed moderate to severe dysfunction, so for that reason it was replaced in the same surgery. The patient underwent a triple valve replacement with mechanical prosthesis at 42 months of the initial surgery. The two remaining patients developed severe aortic regurgitation with dilatation of the aortic neo-root, belatedly in relation to Ross surgery. Both of them underwent an autograft replacement; the first patient underwent a Bentall-DeBono procedure and to the second one a Freestyle prosthesis was implanted, as it was already mentioned.

DISCUSSION

It is widely recognized that valvular diseases represent an important health problem. Aortic valve disease is not an exception and, in fact, is valve disease the one that more often requires surgery. This is due to the high incidence of rheumatic cardiopathy in those developing countries and the increase of the "degenerative" ways of valvular disease associated with the increasing population longevity. (2) This is seen in a sustained increase of valvular intervention procedures. (14)

Aortic valve replacement has demonstrated to have a beneficial benefit in the natural history of

this disease. However, the events associated with prosthesis should be taken into account, in particular thromboembolic and bleeding, associated with mechanical prosthesis and its anticoagulation, and the possible need of reoperation in bioprostheses. (15-20) So much so that the standard of survival after an aortic valve replacement seems to be lower than the one observed in control populations, age-adjusted; (21) this would be associated with valve replacement.

Ross procedure (1) was performed for the first time in 1967 as a surgical alternative for the treatment of aortic valve disease. Is the only "living" valve replacement with the capacity of own regeneration. It has a good hemodynamic profile and provides an excellent quality of life. (31) Most surgical series have communicated a low hospital mortality, (10, 22, 23) similar to the one of our series and to the mortality of 2.5% published in the Ross International Register. (24) Remote survival was also excellent; Chippiani et al. communicated a survival at 10 years of $95.7\% \pm 2.1\%$, (22) similar to the survival at 10 years (95.4%) published by Yacoub (10) and, once more, comparable to that of our series. Despite these encouraging results, there are two important facts that cause concern. First, it is a demanding procedure and requires a considerable level of learning. Second, there is certain uncertainty regarding autograft and homograft durability.

The incidence of autograft dysfunction varies according to the considered series. The reason of this difference would probably correspond to multiple factors, one of them perhaps is the surgical technique used. (10, 23, 25-27) The initial descriptions considered the autograft subcoronary implantation; then the total replacement of the aortic root and the technique of inclusion of pulmonary autograft in the aortic root were added. Beyond the technical complexity of Ross surgery; when evaluating remote results, one of the variables we should consider is the autograft technical consistency. This would probably explain the different prevalence of autograft dysfunction observed among centers in which all the surgeries are carried out by the same surgeon, in contrast to those that are performed by different surgeons. (10, 28) It has been speculated about the existence of a bicuspid aortic valve and the risk of developing autograft dysfunction. (8, 29, 30) Nowadays, most of the authors coincide that the presence of a bicuspid aortic valve is not a contraindication to carry out Ross surgery. In fact, this surgical procedure is possible, whenever the pulmonary valve is normal and the aortic root is not severely dilated.

Although in our series the majority of the patients who needed a reoperation had aortic valve insufficiency as the basic valve disease, the indication for surgery was not associated with autograft dysfunction. In fact, in half of the cases the indication of reoperation was associated with the development of severe valve dysfunction of other valve due to progressive rheumatic cardiopathy.

Limitations

The main limitation is because the follow-up was complete in 93% of the cases, with the possible loss of some late event. As it was mentioned, two patients refused the indication of reoperation due to autograft dysfunction and were not taken into account in the follow-up; being operated, the rate of reoperation would have been higher.

CONCLUSIONS

Ross surgery is associated with an excellent survival in our center, with similar results to those communicated by pioneering groups. It should be considered in patients with life expectancy higher than 20 years and do not want, or cannot, receive anticoagulant treatment; young patients with an active lifestyle or patients who perform certain professional activities with high risk of traumatism. Is the ideal surgical option in women of reproductive age, taking into account the associated risks with the anticoagulant treatment during pregnancy.

The main concern cause is the possibility of autograft and homograft late dysfunction. According to this possibility, a close monitoring of our population is necessary.

RESUMEN

Reemplazo valvular aórtico utilizando la cirugía de Ross: 13 años de experiencia

Introducción

El procedimiento de Ross para el tratamiento de la valvulopatía aórtica se ha utilizado durante décadas. A pesar de sus resultados alentadores, ciertos interrogantes han limitado su uso masivo; su durabilidad es uno de los principales motivos de preocupación.

Objetivo

Analizar los resultados de la cirugía de Ross en nuestro centro.

Material y métodos

El presente es un estudio de cohorte retrospectivo. De julio de 1995 a mayo de 2008, 198 pacientes fueron sometidos a cirugía de Ross; en todos ellos se empleó la técnica de reemplazo de la raíz aórtica. Los eventos asociados con la válvula se analizaron con el método de Kaplan-Meier. Para el análisis de las variables se emplearon el log-rank test y el modelo de Cox.

Resultados

La edad media fue de 39 ± 13 años; el 77% eran hombres. La cirugía fue indicada por estenosis aórtica (58%) e insuficiencia aórtica (42%). La mortalidad hospitalaria fue del 2,5% (5 pacientes). El seguimiento a 10 años fue completo en el 93% para los primeros 165 pacientes. La supervivencia a los 10 años fue del 94,8% (IC 95% 89-98). La libertad de endocarditis a los 10 años fue del 95% (IC 95% 84-98) y la libertad de eventos relacionados con la válvula a los 10 años fue del 91% (IC 95% 86-96). Cinco pacientes requirieron reoperación, 4 de ellos por disfunción del autoinjerto y enfermedad de otras válvulas.

Conclusiones

La cirugía de Ross es una técnica quirúrgica con una tasa baja de eventos a los 13 años y debe ser considerada para el tratamiento de la enfermedad valvular aórtica en pacientes seleccionados.

Palabras clave > Reemplazo valvular aórtico - Cirugía de Ross - Procedimiento de Ross - Autoinjerto pulmonar

BIBLIOGRAPHY

- Ross DN. Replacement of aortic and mitral valves with a pulmonary autograft. *Lancet* 1967;2:956-8.
- Yacoub MH, Cohn LH. Novel approaches to cardiac valve repair: From structure to function: Part I. *Circulation* 2004;109:942-50.
- Simon P, Aschauer C, Moidl R, Marx M, Keznickl FP, Eigenbauer E, et al. Growth of the pulmonary autograft after the Ross operation in childhood. *Eur J Cardiothorac Surg* 2001;19:118-21.
- Moidl R, Simon P, Aschauer C, Chevtchic O, Kuplik N, Rodler S, et al. Does the Ross operation fulfill the objective performance criteria established for new prosthetic heart valves? *J Heart Valve Dis* 2000;9:190-4.
- Carr-White GS, Kilner PJ, Hon HJ, Rutledge T, Edwards S, Burman ED, et al. Incidence, location, pathology, and significance of pulmonary homograft stenosis after the Ross operation. *Circulation* 2001;104:116-20.
- Takkenberg JJ, Dossche KM, Hazekamp MG, Nijveld A, Jansen EW, Waterbolk TW, et al. Report of the Dutch experience with the Ross procedure in 343 patients. *Eur J Cardiothorac Surg* 2002;22:70-7.
- Kouchoukos NT, Masetti P, Nickerson NJ, Castner CF, Shannon WD, Davila-Roman VG. The Ross procedure: Long-term clinical and echocardiographic follow-up. *Ann Thorac Surg* 2004;78:773-81.
- David TE, Omran A, Ivanov J, Armstrong S, de Sa MPL, Sonnenberg B, et al. Dilatation of the pulmonary autograft after the Ross procedure. *J Thorac Cardiovasc Surg* 2000;119:210-20.
- Takkenberg JJ, van Herwerden LA, Galema TW, Bekkers JA, Kleyburg-Linkers V, Eijkemans MJ, et al. Serial echocardiographic assessment of neo-aortic regurgitation and root dimensions after the modified Ross procedure. *J Heart Valve Dis* 2006;15:100-7.
- Yacoub MH, Klieverik LM, Melina G, Edwards SE, Saratchandra P, Bogers JJ, et al. An evaluation of the Ross operation in adults. *J Heart Valve Dis* 2006;15:531-9.
- American College of Cardiology; American Heart Association Task Force on Practice Guidelines (Writing Committee to revise the 1998 guidelines for the management of patients with valvular heart disease); Society of Cardiovascular Anesthesiologists, Bonow RO, Carabello BA, Chatterjee K, de Leon AC Jr, Faxon DP, Freed MD, et al. ACC/AHA 2006 guidelines for the management of patients with valvular heart disease: a report of the American College of Cardiology/American Heart Association Task Force on Practice Guidelines (writing Committee to Revise the 1998 guidelines for the management of patients with valvular heart disease) developed in collaboration with the Society of Cardiovascular Anesthesiologists endorsed by the Society for Cardiovascular Angiography and Interventions and the Society of Thoracic Surgeons. *J Am Coll Cardiol* 2006;48:e1-148.
- Northrup WF 3rd, Kshetry VR. Implantation technique of the aortic homograft root: Emphasis on matching the host root to the graft. *Ann Thorac Surg* 1998;66:280-4.
- Elkins RC, Knott-Craig CJ, Howell CE. Pulmonary autografts in patients with aortic annulus dysplasia. *Ann Thorac Surg* 1996;61:1141-5.
- Edwards MB, Taylor KM. A profile of valve replacement in the UK (1986-1997): a study from the UK Heart Valve Registry. *J Heart Valve Dis* 1999;8:697-701.
- Cannegieter SC, Rosendaal FR, Briet E. Thromboembolic and bleeding complications in patients with mechanical heart valve prosthesis. *Circulation* 1994;89:635-41.
- Krian A, Matloff J, Nicoloff D. Advancing the technology of bileaflet mechanical heart valve prosthesis. Springer, London, Heidelberg, Steinkoff, Darmstadt, 1998:11-22.
- Jaffe WM, Coverdale HA, Roche AH, Whitlock RML, Barratt-Boyes BG. Rest and exercise hemodynamics of 20-23 mm allografts, Medtronic intact (porcine) and St-Jude Medical valves in aortic position. *J Thorac Cardiovasc Surg* 1990;100:167-74.
- Sanders SP, Levy RJ, Freed MD, Norwood WI, Castaneda AR. Use of Hancock porcine xenografts in children and adolescents. *Am J Cardiol* 1980;46:429-38.
- Rahimtoola SH. Choice of prosthetic heart valve for adult patients. *J Am Coll Cardiol* 2003;41:893-904.
- Bach D. Choice of prosthetic heart valves: Update for the next generation. Viewpoint and Commentary. *J Am Coll Cardiol* 2003;42:1717-9.
- Kvidal P, Bergstrom R, Horte LG, Stahle E. Observed and relative survival after aortic valve replacement. *J Am Coll Cardiol* 2000;35:747-56.
- Chiappini B, Absil B, Rubay J, Noirhomme P, Funken AC, Verhelst R, et al. The Ross procedure: Clinical and echocardiographic follow-up in 219 consecutive patients. *Ann Thorac Surg* 2007;83:1285-9.
- Chambers JC, Sommerville J, Stone S, Ross D. Pulmonary autograft procedure for aortic valve disease. Long-term results of the pioneer series. *Circulation* 1997;96:2206-14.
- Oury JH, Hiro SP, Maxwell JM, Limberti JJ, Duran CM. The Ross procedure: current registry results. *Ann Thorac Surg* 1998;66:S162-5.
- Kouchoukos NT, Davila-Roman VG, Spray TL, Murphy SF, Perrillo JB. Replacement of the aortic root with a pulmonary autograft in children and young adults with aortic valve disease. *N Engl J Med* 1994;330:1-6.
- Elkins RC. The Ross operation: a 12-year experience. *Ann Thorac Surg* 1999;68:S14-8.
- Böhm JO, Botha CA, Rein J-G, Roser D. Technical evolution of the Ross operation: midterm results in 186 patients. *Ann Thorac Surg* 2001;71:S340-3.
- Sievers HH, Hanke T, Stierle U, Bechtel M, Graft B, Robinson D, et al. A critical reappraisal of the Ross operation. Renaissance of the subcoronary implantation technique? *Circulation* 2006;114:I504-11.
- Bogers AJ, Kappetein AP, Roos-Hesselink J, Takkenberg JJ. Is a bicuspid aortic valve a risk factor for adverse outcome after an autograft procedure? *Ann Thorac Surg* 2004;77:1998-2003.
- Favaloro R, Stutzbach P, Gomez C, Machain A, Casabe H. Feasibility of the Ross procedure: its relationship with the bicuspid aortic valve. *J Heart Valve Dis* 2002;11:375-82.
- Notzold A, Huppe M, Schmidtke C, Blomer P, Uhlig T, Sievers HH. Quality of life in aortic valve replacement: Pulmonary autografts versus mechanical prosthesis. *J Am Coll Cardiol* 2001;37:1963-6.