

## Cocaine-induced Pneumopericardium

ELIO MARTÍN GUTIÉRREZ<sup>1</sup>, J. MARTÍNEZ BAÑOS<sup>2</sup>, J.M. GALBIS CARVAJAL<sup>2</sup>, O. GIL ALBAROVA<sup>1</sup>

We present the case of a 21-year-old man with oppressive retrosternal pain, dyspnea and typical vegetative clinic, as well as subcutaneous emphysema in the supraclavicular space and neck with extension to the jaw; all this in relation to the fact that the patient had consumed cocaine an hour before the episode. He had no important medical background, except for his usual consumption of cocaine. Studies showed normal results; in the semi-quantitative analysis of toxics in urine, high levels of cocaine metabolites (+++) were detected and the chest x-ray in a posteroanterior view (Figure 1) showed the presence of pneumopericardium, pneumomediastinum and subcutaneous emphysema in accordance with the aforementioned clinical findings, as well as absence of pneumothorax and pericardial effusion. The CT scan corroborated these findings ruling out the esophageal or tracheal condition as potential origins (Figure 2); on the other hand, the electrocardiogram showed a compatible ST-segment elevation with presence of acute pericarditis.

The patient remained in observation to check the evolution, begin the medical treatment and perform a serial enzymatic procedure. When he was admitted into the emergency department, only mobilization of CK (142 UI/L) was produced; presenting a plateau after 6 hours (136 UI/L) and a fall after 12 hours (84 UI/L); there was no mobilization of CK-MB or TnI (0.0 UI/L).

The hemodynamic stability was stable at every moment, with initial systolic hypertension during his stay at hospital. The chest x-ray, which was performed 12 hours after his admission to the emergency department, showed stability in the findings with no progression of the pneumopericardium.

Once the treatment with NSAIDs began (Ibuprofen 600 mg every 6 hrs) and after observation, the patient was discharged 22 hours after the beginning of the episode. Once the appropriate medical piece of advice was carried out, the patient continued the anti-inflammatory treatment at home and, three days

later, he was called for an ambulatory examination.

In the last two years, admissions to the emergency department related to health problems due to the consumption of cocaine have increased, showing the real problem about the abuse of this drug<sup>1</sup> in our society and, particularly, the importance of harmful effects that this drug has over the cardiovascular system. (2,3) As regards pneumopericardium/pneumomediastinum, six cases of this strange clinical manifestation, all of them with an evolution and treatment similar to the exposed case, have been registered in our center in the last two years.

The etiopathogenesis<sup>4</sup> is not totally known but it may respond to alveolar pressure due to regional spasm which causes a precise alveolar rupture with escape of aerial content that dissects perivascular and peribronchial spaces going into the pericardium, with an irritant behavior of the serous membrane and, as a consequence, the relevant acute pericarditis. Severe pneumopericardium and cardiac tamponade<sup>5</sup> are less frequent and if they are present, they appear during the first hours. In the revised bibliography (Medline® of the last 20 years), most of the cases belong to iatrogenesis related to surgical and endoscopy procedures or mechanical ventilation among others (30 cases); open or non-open traumatism (28 cases); stomach or esophageal perforation secondary to a peptic or tumoral disease (28 cases); infections (13 cases); toxins (3 cases) and idiopathic conditions (10 cases). However, only 3 cases of pneumopericardium secondary to an asthmatic crisis have been described. (6,7) Some of the cases<sup>8</sup>, which were registered in the bibliography and that were also associated with the consumption of toxics (mainly cocaine), are consequence of mechanical ventilation applied to the critical state secondary to the consumption of the drug. The cases of spontaneous onset are scarce.

Finally, the incidence of pneumopericardium in consumers of cocaine is unknown but, due to its peculiarity, we should probably interpret it as the tip of the iceberg of a huge public health problem.

---

Institutional affiliation

<sup>1</sup> Service of Cardiac Surgery. Cardiovascular Institute. Consortium University General Hospital of Valencia.

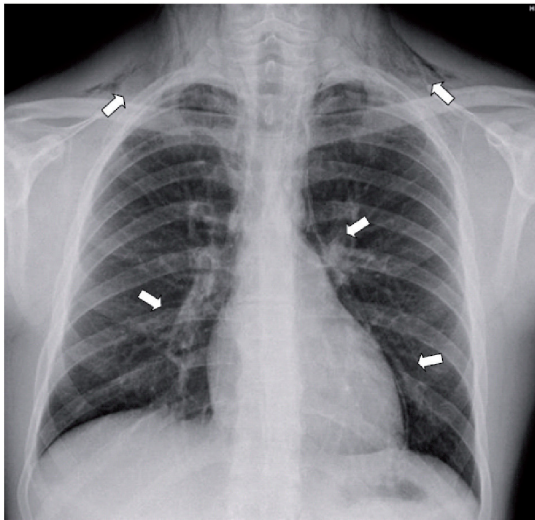
<sup>2</sup> Service of Thoracic Surgery. Consortium University General Hospital of Valencia.

**Address for reprints:**

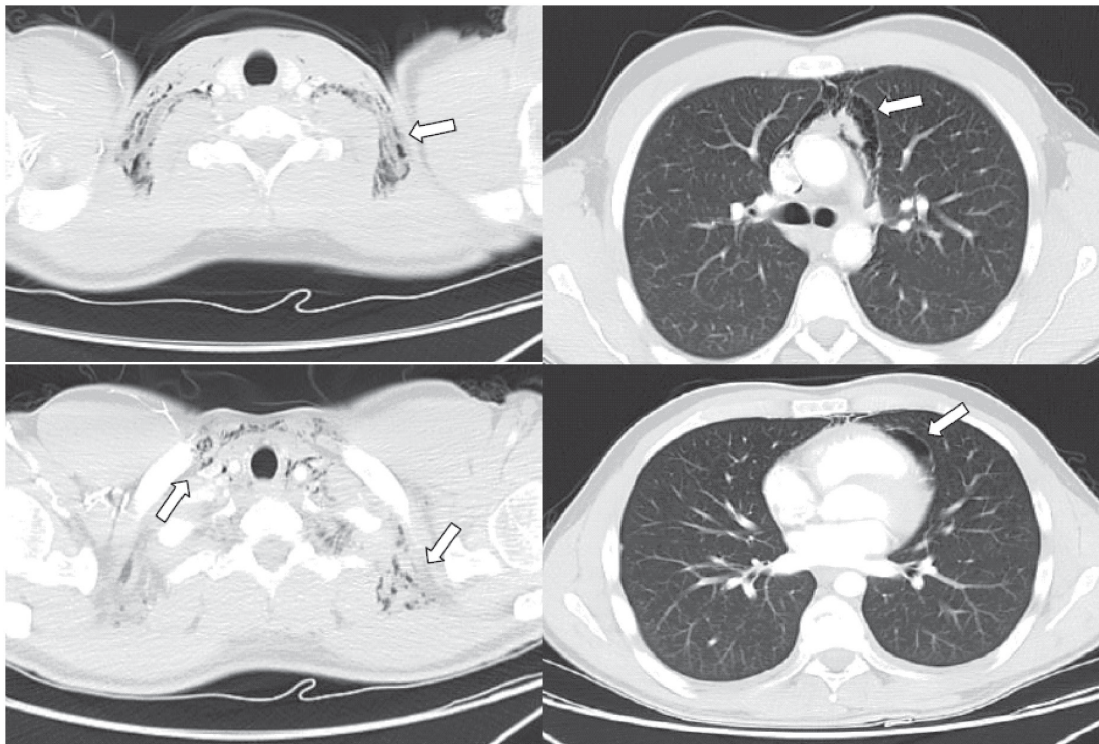
Dr. Elio Martín Gutiérrez. Service of Cardiac Surgery. Cardiovascular Institute. Consortium University General Hospital of Valencia.

Av. Tres Cruces, 2. 46014, Valencia, Spain.

E-mail: elio.m@comv.es



**Fig. 1 and 2.** Findings from simple chest x-ray and CT studies in the mediastinal and pulmonary parenchymal windows that show the pneumopericardium with dissection of the anterior mediastinal space (pneumomediastinum) and its progression due to the anatomical continuity towards the cells of cervical spaces in the way of subcutaneous emphysema (white arrows)



## BIBLIOGRAPHY

1. Pollin W. The danger of cocaine. *JAMA* 1985; 254: 98.
2. Redkalla SH, Hale S, Kloner RA. Cocaine induced heart diseases. *Am Heart J* 1990; 120: 1403-8.
3. Mouhaffel AH, Madu EC, Satmary WA, Fraker TD Jr. Cardiovascular complications of cocaine. *Chest* 1995; 107: 1426-34.
4. Muñoz Ávila JA, Jiménez Murillo LM, Montero Pérez FJ, Calderón de la Barca Gázquez JM, Berlango Jiménez A, Durán Serantes M, et al. Pneumopericardium: review of the literature. *Rev Clin Esp* 1994; 194: 926-8.
5. Álvarez L, Blondiau JV, Scherpings P, Musch W, Creplet J, Malarme M. Pneumopericardium: a race against time! Case report and literature review. *Rev Med Brux* 1996; 17: 143-6.
6. Stack AM, Caputo GL. Pneumomediastinum in childhood asthma. *Pediatr Emerg Care* 1996; 12: 98-101.
7. van der Klooster JM, Grootendorst AF, Ophof PJ, Brouwers JW. Pneumomediastinum: an unusual complication of bronchial asthma in a young man. *Neth J Med* 1998; 52: 150-4.
8. Adrouny A, Magnusson P. Pneumopericardium from cocaine inhalation. *N Engl J Med* 1985; 313: 48.