

Iatrogenic Hydropneumopericardium after Pericardiocentesis

CRISTINA MORENO AMBROJ¹, ELISA BLANCO GONZÁLEZ¹, TERESA OLÓRIZ SANJUÁN¹, MARÍA C FERRER GRACIA¹, JOSÉ G GALACHE OSUNA¹, JOSÉ A DIARTE DE MIGUEL¹, JUAN SÁNCHEZ-RUBIO LEZCANO¹

Received: 05/07/2010

Accepted: 03/28/2011

Address for reprints:

Cristina Moreno Ambroj
C/ Felisa Galé, nº 46, 3ªA. 50014.
Zaragoza. Spain
E-mail: crystynama@hotmail.com
Phone number: 0034 976 478292 /
0034 615 219487
Fax number: 0034 976 562565

SUMMARY

Hydropneumopericardium is defined by the accumulation of serous fluid and gas in the pericardial sac. It is uncommon in adults, usually associated with favorable outcomes; yet, it may be severe occasionally.

We present the case of a kidney transplant patient who developed cardiac tamponade requiring pericardiocentesis. Several days after the procedure, the patient presented chest pain due to iatrogenic hydropneumopericardium. Image tests are essential to make this diagnosis.

REV ARGENT CARDIOL 2011;79:278-280.

Key words > Pericardial effusion. Cardiac tamponade. Pericardiocentesis. Pneumopericardium.

CASE REPORT

A 54-year old man was admitted to the Department of Nephrology due to progressive dyspnea on minimal effort associated to yellowish-white expectoration and deterioration of his general health status.

He had a history of insulin-dependent diabetes mellitus, kidney transplantation 11 years before due to diabetic nephropathy with kidney failure treated with rapamycin (sirolimus) and corticosteroids, multivessel coronary artery disease without possibilities of revascularization, with a left ventricular ejection fraction < 20%. The patient had been followed-up with serial echocardiograms in the last five years to moderate to severe chronic pericardial effusion. Physical examination and laboratory tests were normal. The chest-X ray revealed the presence of heart enlargement and a small left-sided pleural effusion.

A diagnosis of sirolimus-induced pneumonitis was suspected and the patient underwent a chest computed tomography (CT) scan, which showed a very large pericardial effusion with a thick visceral pericardium layer. There was also bilateral pleural effusion which was larger on the left and multiple centrilobular ground-glass opacities suggestive of sirolimus-induced pneumonitis. The echocardiogram showed left ventricular dilation (end-diastolic diameter: 6 cm) with global hypokinesia (LVEF20-25%), and severe pericardial effusion with signs of hemodynamic instability.

As the patient presented clinical deterioration, a pericardiocentesis was performed and 180cm³ of serous fluid were obtained. Pericardial fluid analysis showed nonspecific results. The chest-X ray after the pericardiocentesis showed reduction in the cardiac silhouette and the echocardiogram demonstrated mild pericardial effusion.

Six days after undergoing pericardiocentesis, the patient presented sharp pain on the left side of the

chest. Chest-X ray and CT scan revealed the presence of hydropneumopericardium (Figures 1 and 2).

The echocardiogram showed the presence of moderate to severe pericardial effusion without hemodynamic compromise; contrast-enhanced echocardiography demonstrated air bubbles in the entire pericardial sac.

As the patient remained clinically and hemodynamically stable no other invasive procedures were planned. The air in the pericardium gradually reabsorbed and five days later the echocardiogram showed mild to moderate pericardial effusion with reduction in the content of air.

However, four days later another echocardiogram revealed the presence of severe pericardial effusion with signs of hemodynamic involvement. Yet, the patient was clinically stable. A pleuropericardial window was performed.

Seven months after the intervention the echocardiograms confirm the absence of fluid in the pericardial sac.

DISCUSSION

Several cases of pneumopericardium have been reported, yet hydropneumopericardium is an uncommon condition.

Most cases of pneumopericardium are described in newborns undergoing mechanical ventilation due to respiratory distress. (1)

In adults this is an exceptional finding due to multiple etiologies:(1)

- Most cases are iatrogenic secondary to endoscopies, endotracheal intubation, sternal puncture, coronary artery bypass graft surgery, thoracocentesis or pericardiocentesis, as in the case here described. (2)

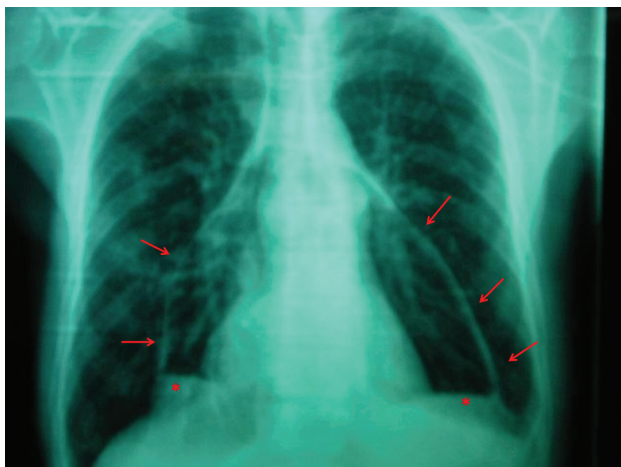

Fig. 1. Posteroanterior chest-X ray. The radiolucent band corresponds to air (arrows) surrounding the cardiac silhouette separating both pericardial layers, with opacity corresponding to fluid (asterisks) in the lower part of the pericardial sac.

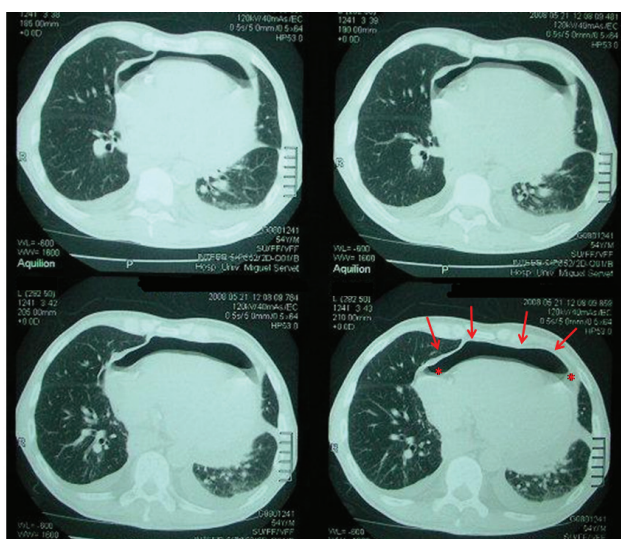


Fig. 2. Chest computed tomography scan. Note the presence of air (arrows) in the most anterior part of the pericardial sac (with the patient in the supine position) associated to small amount of pericardial fluid (asterisks), bilateral pleural effusion and parenchymal opacities in the right superior lobe with signs of infective bronchial compromise.

- Alveolar rupture due to increased alveolar pressure (asthma, mechanical ventilation, cocaine inhalation, cough or intense exercise) with air accumulating within the mediastinum which may exceptionally progress into the pericardial sac. (5)
- Idiopathic.

The clinical manifestations are pleuropericardial chest pain or dyspnea; cardiac tamponade may occur in severe cases. Occasionally, a mill-wheel murmur is present at auscultation.

The chest-X ray demonstrates the typical radiolucent band surrounding the cardiac silhouette, frequently associated with signs of pneumomediastinum. CT scan is useful to determine the etiology and to make the differential diagnosis with pneumomediastinum: the air level modifies with the patient in the supine position in cases of pneumopericardium but not of pneumomediastinum. Echocardiography demonstrates air-fluid interface in the pericardial sac in patients with hydropneumopericardium.

Most cases resolve with support measures; yet, some patients may experience hemodynamic instability with risk of mortality.

RESUMEN

Comportamiento de la presión pulmonar y función del ventrículo derecho intraesfuerzo

El hidroneumopericardio se define por la presencia de líquido y aire en la cavidad pericárdica. Se trata de una afección infrecuente en los adultos, habitualmente asociada a buen pronóstico, pero que puede resultar potencialmente grave. Presentamos el caso de un paciente trasplantado renal que debutó con taponamiento cardíaco y que precisó pericardiocentesis; varios días después, presentó un cuadro de dolor torácico debido a un hidroneumopericardio iatrogénico. Las pruebas de imagen son claves en la obtención de este diagnóstico.

Palabras clave > Derrame pericárdico - Taponamiento cardíaco - Pericardiocentesis - Neumopericardio

BIBLIOGRAPHY

- Open or closed chest traumas with air entering through a hole in the chest wall to the pericardial sac or via a ruptured hollow viscus.
- Perforation of a hollow viscus adjacent to the heart leading to fistulas from the pericardium to the esophagus, stomach or bronchial tree as a complication of neoplasms or peptic ulcer. (3)
- Opportunistic infections due to gas-producing microorganism (purulent hydropneumopericardium). (4)

1. Montiel Trujillo A, Ruiz Ruiz M, Jiménez Navarro M, Gómez Doblas JJ, Rueda Calle E, de Teresa E. Neumopericardio en un paciente asmático. Descripción de un caso y revisión de la bibliografía. *Rev Esp Cardiol.* 1999;52:1015-8.
2. Benedik J, Uchtyl B, Cemosek J. Pneumopericardial tamponade after coronary artery bypass operation. *Eur J Cardiothorac Surg.* 2002;21:585-6.
3. Grandhi TM, Rawlings D, Morran CG. Gastropericardial fistula: a case report and review of literature. *Emerg Med J.* 2004;21:644-5.
4. Van Ede AE, Meis JF, Koot RA, Heystraten FM, de Pauw BE. Pneumopericardium complicating invasive pulmonary aspergillosis: case report and review. *Infection.* 1994;22: 102-5.
5. McEachern RC, Patel RG. Pneumopericardium associated with face-mask continuous positive airway pressure. *Chest.* 1997;112:1441-3.