

Acute Mitral Regurgitation Secondary to Anteromedial Papillary Muscle Rupture.

GABRIEL PÉREZ BAZTARRICA¹, FERNANDO SORIA², ESTELA REOLÓN^{3†}

Acute mitral regurgitation is a serious complication of acute myocardial infarction, but with a lower incidence of 1% in association with reperfusion therapies. (1) However, the anteromedial muscle rupture is less frequent. The images that are presented, correspond to a 66 years old patient with history of hypertension, former smoking and chronic stable angina in functional class II with myocardial perfusion with lateral ischemia. The patient was admitted to our center with symptoms of acute myocardial infarction, lateral ST elevation type with anterior subendocardial compromise. He underwent a primary angioplasty to the circumflex artery (in cinecoronariography also showed serious compromise of anterior descending artery in the middle third and the right coronary artery in the third proximal-medial joint, also severe). In turn, Doppler echocardiography revealed lateral akinesia and severe anterior hypokinesia from basis to top, valvular regurgitations were not visualized. On the sixth day of hospitalization he had symptoms of cardiogenic shock and new regurgitation heart murmur in mitral focus in a Doppler echocardiogram, in which it was found severe mitral regurgitation because anterior papillary muscle rupture (Figure 1). For his hemodynamic stabilization, he required high doses of inotropic, MRA and intra-aortic balloon counterpulsation. Emergency replacement of the valve was carried out with mechanical prosthesis and miocardic revascularization (MADA-PVCD). In the anatomical part of the valve and subvalvular apparatus it was confirmed complete necrotic rupture of anteromedial papillary muscle (Figure 2).

Secondary acute mitral regurgitation to necrotic compromise is one of the causes of cardiogenic shock in patients enrolled in acute myocardial infarction. Among the mechanisms that cause valvular regurgitation are included ischemic dysfunction or papillary muscle rupture. As the incidence of acute mitral regurgitation in coronary post-angioplasty in the context of an acute myocardial infarction with ST elevation is 0.26%. (2) The complete rupture of the anteromedial papillary muscle due to its double irrigation (left anterior descending and circumflex), is uncommon (between 13% and 27% of cases). (3, 4) The clinical presentation ranges from acute pulmonary edema to cardiogenic shock.

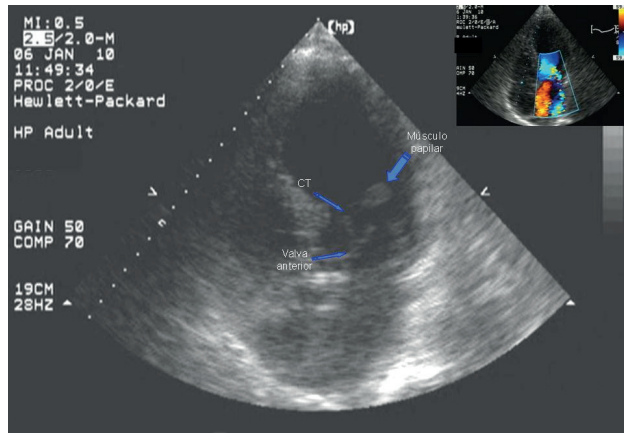


Fig. 1.

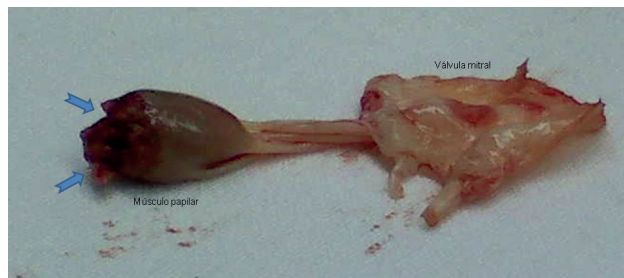

Fig. 2.

Transthoracic echocardiogram is useful to confirm and assess the severity of mitral regurgitation, whereas TEE has sensitivity and specificity for diagnosing muscle rupture. However, in our case, both the assessment of mitral regurgitation as the source of this by papillary muscle rupture were carried out through transthoracic echocardiogram. Once the diagnosis was set up, surgical treatment (valve replacement or plastic associated with myocardial revascularization surgery, according to each case) of emergency is a priority and carries a mortality approaching 50%. (1-5) In our case, the patient developed in the postsurgical with multiorgan dysfunction and death.

BIBLIOGRAPHY

1. Thompson C, Buller C, Sleeper L, Antonelli T, Webb J, Jaber W, Abel J, Hochman J. Cardiogenic shock due to acute severe mitral regurgitation complicating acute myocardial infarction: a report from the SHOCK trial registry. *J Am Coll Cardiol* 2000;36:1104-9.
2. French J, Hellkamp A, Armstrong P, Cohen E, Kleiman N, O'Connor C, et al. Mechanical complications after percutaneous coronary intervention in ST-elevation myocardial infarction (from APEX-AMI). *Am J Cardiol* 2010;105:59-63.
3. Barbour D, William R. Rupture of a left ventricular papillary muscle during acute myocardial infarction: analysis of 22 necropsy patients. *J Am Coll Cardiol* 1986;8:558-65.
4. Lorusso R, Gelsomino S, De Cicco G, Beghi C, Russo C, De Bonis M, Colli A, Sala A. Mitral valve surgery in emergency for severe acute regurgitation: analysis of postoperative results from a multicentre study. *Eur J Cardio-Thoracic Surg* 2008; 33:573-82.
5. Caballero-Borrego J, Hernández-García J, Sanchis-Fores J. Complicaciones mecánicas en el infarto agudo de miocardio. ¿Cuáles son, cuál es su tratamiento y qué papel tiene el intervencionismo percutáneo? *Rev Esp Cardiol* 2009; 9(Supl):62C-70C.