

## Conservative Management of Projectile Impact on the Heart. Two Consecutive Cases

JUAN G. CÓRDOBA SORIANO<sup>1</sup>, VÍCTOR M. HIDALGO OLIVARES<sup>1</sup>, ANTONIA TERCERO MARTÍNEZ<sup>1</sup>, MOISÉS BARAMBIO RUIZ<sup>1</sup>, RAFAEL SÁNCHEZ INIESTA<sup>2</sup>, FRANCISCO M. SALMERÓN MARTÍNEZ<sup>1</sup>

Received: 07/20/2011

Accepted: 08/11/2011

### Address for reprints:

Dr. Juan G. Córdoba Soriano  
C/Marqués de Villares nº 67 - 1º E  
CP 02003, Albacete (España)  
e-mail: jgcordobas@hotmail.com

### ABSTRACT

Cardiac shotgun injuries affecting the heart, pericardium and great vessels are occasionally encountered in clinical practice. Specifically in Spain, pellet wounds from hunting accidents have increased. The treatment of these injuries is not standardized due to the small number of cases treated in each particular center. We present two consecutive cases of cardiac pellet-gun related injuries treated at our institution with a conservative approach, and favorable outcome.

REV ARGENT CARDIOL 2012;80:247-249.

**Key words** > Heart - Wounds and Injuries

**Abbreviations** >

HECG	Electrocardiogram	CT	Computed tomography
TTE	Transthoracic echocardiography		

### BACKGROUND

As many Spanish people are fond of hunting, cardiac shotgun injuries affecting the heart, pericardium and great vessels are occasionally encountered in the clinical practice in Spain. Treatment of these injuries is not standardized due to the small number of cases treated in each specific center, obstructing the development of studies with an acceptable number of patients. We describe two recent consecutive cases of cardiac injury caused by projectile impact due to hunting accidents that were successfully managed with a conservative approach at our institution.

### METHODS

#### Case 1

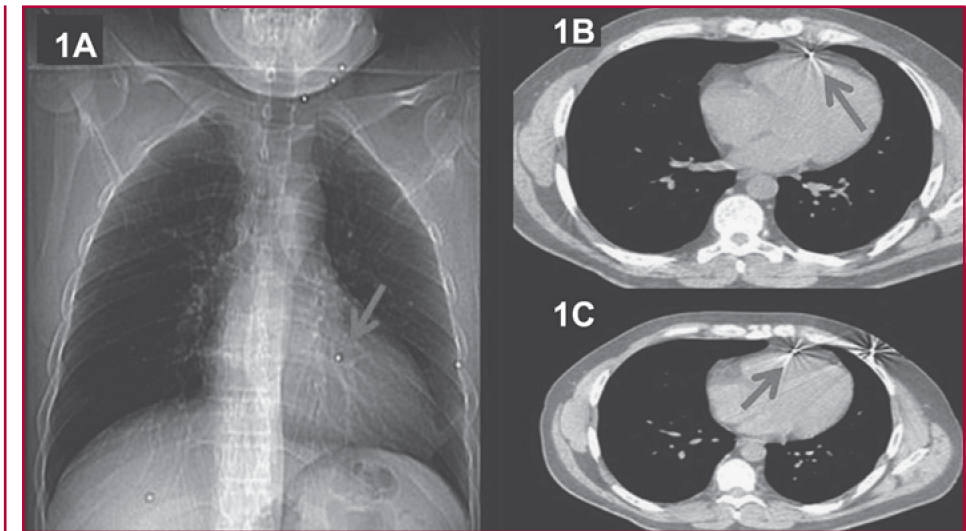
A 43-year old man was admitted to the hospital due to the impact of multiple pellets on the head, neck, thorax and abdomen. He was hemodynamically stable and had no signs of respiratory involvement; he only complained of pain at the sites of skin injury caused by the shots. He had no fever, jugular engorgement or pulsus paradoxus. Cardiac rhythm was normal and there were no heart murmurs or rub. Pulmonary auscultation was normal, and projectile entrance orifices were the only abnormality on physical examination. Chest-X ray (Figure 1 A) showed a normal cardiothoracic index, absence of signs of pneumothorax and seven metallic densities, one of them over the cardiac silhouette. The electrocardiogram (ECG) indicated sinus rhythm with

a heart rate of 80 beats per minute with discrete J-point elevation in the right precordial leads. Biomarkers of myocardial damage were normal. Transthoracic echocardiography (TTE) revealed the presence of mild pericardial effusion (anterior wall: 2 mm, posterior wall: 3mm) with no signs of hemodynamic involvement and intense reverberation in the anterolateral wall of the left ventricle. An iodinated contrast-enhanced computed tomography (Figure 1 B and C) was performed. Metallic densities were seen at the inner corner of left eye, between the left carotid artery and left jugular vein, in the left anterior hemithorax and in the abdominal wall. There were no signs of complications at these sites. A pellet was observed in the mediastinum embedded in the parietal pericardium, with minimal effusion and absence of signs of pneumothorax. The patient was admitted to the Department of Cardiology for observation of the clinical outcome and was managed with a conservative approach. He remained asymptomatic, with no chest pain or arrhythmias. Serial ECGs were not different from the first record. An echocardiogram performed five days after hospitalization showed absence of pericardial effusion. The foreign body remained in the same place.

#### Case 2

A 55-year old man was admitted to the hospital due to impact of multiple pellets on the head, neck, thorax, abdomen and limbs. He was also hemodynamically

**Fig. 1. A.** Chest X-ray. Seven metallic densities are seen, one of them over the cardiac silhouette. **B and C.** CT. Metallic density in contact with the parietal pericardium (arrows).



stable and had no signs of respiratory failure on admission. The physical examination showed skin wounds due to pellet impact. There were no signs of cardiac tamponade, and no rub or heart murmurs at auscultation. The chest-X ray (Figure 2 A) showed a normal heart size and multiple metallic densities on the upper limbs, head, neck and three over the cardiac silhouette. The ECG was within normal ranges and cardiac enzymes were normal. The CT scan (Figure 2 D) demonstrated the presence of pellets in multiple levels, including two in the heart, and TTE (Figure 2 B and C) showed one pellet embedded in the interventricular septum and another at the site of implantation of the lateral border of the tricuspid valve, without pericardial effusion and normal valve function. Monitoring with a conservative treatment was decided. No arrhythmias were detected. The TTE performed on the sixth day showed absence of effusion with the pellets in the same place.

#### Therapeutic approach

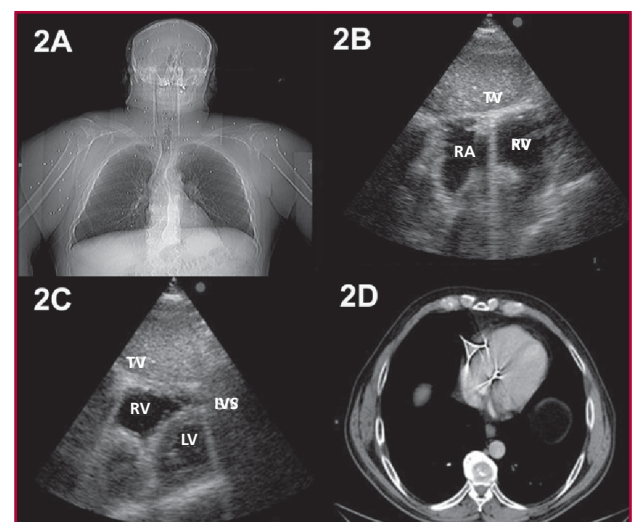
After discussing both cases with clinicians and surgeons, a conservative strategy was decided for both patients due to the absence of complications and symptoms. After one year, both patients continue follow-up at the cardiology outpatient clinic. The foreign bodies remain in the same place and the patients are free of complications and symptoms.

#### DISCUSSION

Management of this type of cases is still controversial. (1-3) Surgery is indicated when life-threatening complications develop, as cardiac tamponade or erosion and bleeding. (2) Late complications depend on pellet type, size and location; the most common are persistent chest pain, pericarditis, embolization, endocarditis, sepsis, intracardiac fistulas and cardiac neurosis. (2-4) Patients with pericardial involvement frequently undergo surgery to prevent symptoms or complications. In the study by Symbas et al. (2),

35 out of 40 patients with pericardial involvement underwent surgery. In the remaining five patients, two presented pericarditis, one chest pain and one died due to cardiac tamponade 11 days after unsuccessful surgery. Willemsen et al. (3) described another case of intrapericardial air gun pellet that underwent surgery after developing ventricular tachycardia two days after hospitalization.

In our patients, the absence of complications during hospitalization (8 and 7 days, respectively) and the resolution of the minimal pericardial effusion led us to adopt a conservative approach. At present, both



**Fig. 2. Case 2. A.** Chest X-ray. Multiple metallic densities are seen on the upper limbs, head, neck and some over the cardiac silhouette. **B and C.** TTE, subcostal view. Reverberation artifacts at the level of the interventricular septum and at the site of implantation of the lateral border of the tricuspid valve. **D.** CT. Metallic densities at the level of the interventricular septum and the tricuspid valve. RA: Right atrium. IVS: Interventricular septum. RV: Right ventricle. LV: Left ventricle. TV: Tricuspid valve.

patients are asymptomatic. Following a bibliographic survey, (5) management of this condition could be summarized as follows (5): 1) symptomatic patients or those with complications as arrhythmias, infection, fistulas, cardiac tamponade or cardiac neurosis should be operated on. 2) Asymptomatic patients with risk of infection, embolism, sepsis or erosion should be operated on. 3) Asymptomatic patients without associated risks factors may be treated conservatively, particularly if the pellets are completely embedded in the myocardium or in the pericardium as these cases are at low risk of complications.

---

## RESUMEN

### **Impacto de perdigón sobre el corazón: dos casos consecutivos tratados en forma conservadora**

Esporádicamente se presentan en la práctica clínica casos de heridas por arma de fuego que afectan el corazón, el pericardio y los grandes vasos. En el caso concreto de España, la afición a la caza hace que se atiendan pacientes

con impacto de perdigones por accidente. El tratamiento de este tipo de traumatismo no está estandarizado, debido fundamentalmente a los pocos afectados tratados en cada centro particular. En esta presentación se describen dos casos consecutivos atendidos en nuestra institución por impacto de perdigón sobre estructuras cardíacas y cuya evolución fue satisfactoria con tratamiento conservador.

**Palabras clave** > Corazón - Heridas y traumatismos

---

## REFERENCES

1. Cañas A, Almodóvar LL, Lima PP, Buendía JA. Perdigón cardíaco en el septo interventricular. *Rev Esp Cardiol* 2007;60:994-5.
2. Symbas PN, Picone AL, Hatcher CR, Vlais-Hale SE. Cardiac missiles. A review of the literature and personal experience. *Ann Surg* 1990;211:639-46.
3. Willemsen P, Kuo J, Azzu A. Dysrhythmia from an intrapericardial air gun pellet: a case report. *Eur Cardio-Thorac Surg* 1996;10:461-2.
4. Klein JA, Nowak JE, Sutherell JS, Wheeler DS. Nonsurgical management of cardiac missiles. *Pediatr Emer Care* 2010;26:36-8.
5. Actis Dato GM, Arslanian A, Di Marzio P, Filosso PL, Ruffini E. Posttraumatic and iatrogenic foreign bodies in the heart: Report of fourteen cases and review of the literature. *J Thorac Cardiovasc Surg* 2003;126:408-14.