Endoleak: Complication of Endovascular Treatment after Abdominal Aortic Aneurysm

SILVIA V. AGOSTINO, ROBERTO SOUTO, RICARDO BEIGELMAN[MTSAC]

These images (Figures 1 to 2) correspond to an 80-year-old patient who underwent infrarenal abdominal aortic aneurysm repair using a stent-graft.

Endoleaks after endovascular repair are classified into 5 types: (1)

- Type I: at the proximal, distal, or iliac occluder attachment sites.
- Type II: lumbar collateral vessels, inferior mesenteric, middle sacral, or hypogastric artery, or polar arteries (simple: one patent vessel; complex: two or more vessels).
- Type III: graft body (disconnection of the modules, manufacturing failures).
- Type IV: stent-graft porosity.
- Type V or endotension: enlargement of the sac without detectable endoleak.

The following causes are considered: a) poor surgical technique, and b) angulation of the aneurysm neck, calcification, and mural thrombi. (2, 4) The echo-Doppler is an appropriate technique for the systematic follow-up of aortic stent-grafts, together with the selective use of CT scan when ultrasound results are unclear. (4)

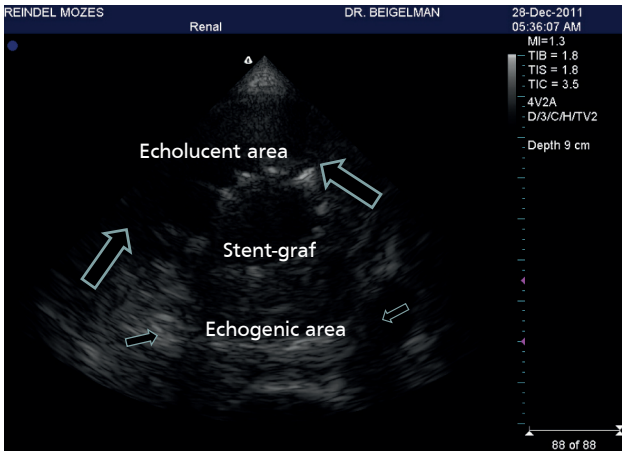

Fig. 1. Two-dimensional ultrasound with zoom in the cross-sectional view: the ultrasonographic difference between the anterior (hemorrhagic) and posterior (thrombosed) walls of the aneurysm is clearly observed.

Fig. 2. Portal phase CT scan; a radiodense image is observed between the arrows, corresponding to the hemorrhage inside the aneurysm.

Video annex. Abdominal aorta color Dopple ultrasound showing endoprosthesis and an important passage of blood flow, in red, through a 3.1 to 3.5 mm in diameter leak, toward the anterior wall of the aneurysm.

REFERENCES

1. Cuenca-Manteca JP, Linares-Palomino LM, Salmerón-Febrés E, Ros-Díe. Diagnóstico y tratamiento de las endofugas. Acuerdos y desacuerdos. Angiología 2008;60:S25-9.

2. Hobo R, Kievit J, Leurs LJ, Buth J; EUROSTAR Collaborators. Influence of severe infrarenal aortic neck angulation on complications at the proximal neck following endovascular AAA repair: a EUROSTAR study. J Endovasc Ther. 2007;14:1-11. http://doi.org/d87wms

3. Maeso-Lebrun J, Clará A, Escudero-Rodríguez JR, Gestro-Castromil R, Gómez-Palonés FJ, Riambau-Alonso V, et al. Tratamiento endovascular de la patología aneurismática de la aorta abdominal. Angiología 2007;59 (Supl 1):S3-28.

4. Johnson BL, Dalman RL. Duplex surveillance of abdominal aortic stent grafts. Semin Vasc Surg. 2001;14:227-32. http://doi.org/btrvgv

Conflict of interest

None declared

Rev Argent Cardiol 2012;80: 375. http://dx.doi.org/10.7775/rac.es.v80.i5.1714

Echo Doppler Unit - Hospital Municipal Héctor Dagnillo
[MTSAC] Full Member of the Argentine Society of Cardiology
E- mail: rlbeigelman@yahoo.com.ar