

Endovascular Repair of Type IV Thoracoabdominal Aneurysms

LUIS M. FERREIRA, SERGIO ESCORDAMAGLIA, JOSÉ N. ALLENDE, JULIO ROSEMBERG, CARLOS INGINO^{MTSAC}, A. RICARDO LA MURA

Received: 03/25/2012
Accepted: 05/10/2012

Address for reprints:

Dr. Luis M. Ferreira
Clínica La Sagrada Familia - ENERI
José Hernández 1642
(1426) CABA
Phone-Fax number +5411 6343-7800
e-mail: drferreira@yahoo.com

ABSTRACT

Background

Type IV thoracoabdominal aortic aneurysms are characterized by involvement of the visceral aortic segment which determines the lack of a proximal aortic neck suitable for the implantation conventional stents. Fenestrated stents have been specially developed for these cases. We describe the experience of a surgical center using fenestrated stents in six patients. All the stents were successfully implanted, respecting 20 visceral vessels. This approach is a valid alternative for patients who are at high risk for conventional surgery.

REV ARGENT CARDIOL 2012;80: 372-374. <http://dx.doi.org/10.7775/rac.v80.i5.1017>

Key words > Aortic aneurysm, thoracic - Stents

BACKGROUND

The lack of a proximal aortic neck suitable for endograft attachment is currently the main anatomical reason to exclude patients from endovascular repair of abdominal aortic aneurysms using conventional stent-grafts. Several studies have demonstrated that the presence of proximal neck dilatation, neck angulation, short neck length, neck thrombus or a funnel-shaped aortic neck are related with insufficient attachment in terms of quality and time and associated with a greater incidence of proximal endoleak, stent-graft migration and even aneurysm rupture. (1-3) Conversion to conventional open aortic repair of type IV thoracoabdominal aneurysms are associated with a high rate of complications, including mortality. (4-6)

Fenestrated stent-grafts (with orifices in the Dacron graft that allow the connection with the visceral arteries) have been developed to improve proximal implantation of the device, incorporating the visceral segment of the aorta to the usual zone of deployment, sealing and shear strength. This technique has proved to be feasible, safe and effective at the mid-term. (7)

The experience of a surgical team with endovascular repair of complex aortic aneurysms is described.

METHODS

Six patients underwent endovascular repair using custom made fenestrated stent-grafts (Cook Medical, Bloomington, Ind). Endografts were made in Australia based on the information obtained from high resolution computed tomography

images (Figure 1).

All the patients were previously studied with high resolution computed tomography angiography (CTA) and were classified according to the morphology of the aneurysm as unsuitable for conventional endovascular grafting of infrarenal aneurysms. Computed tomography scans were used for center line of flow analysis and multiplanar reconstruction to design and customize the devices. Small (6 mm in diameter) and large (8 mm in diameter) fenestrations and scallops were constructed as options for the device design. Patency, branches distribution, their positions according to the clock face, and height and size of each vessel to be preserved were evaluated.

The following are some of the essential technical aspects of device implantation: under local or regional anesthesia, both femoral arteries were exposed. A stiff guide-wire was introduced via the femoral artery assigned for navigation and deployment of the proximal fenestrated segment, and an introducer with hemostasis valve (20 Fr a 22 Fr Check-Flo, Cook Medical) was advanced via the contralateral access to introduce the fenestrated device. The fenestrated segment was introduced and orientated with the help of anterior and posterior opaque gold markers present in each fenestration. The proximal component was partially deployed and the fenestrations were aligned with the corresponding visceral ostium. Then, guide-wires were inserted in all the fenestrations and the corresponding visceral arteries through sheaths and catheters placed in the contralateral access. Once all the fenestrations had been cannulated and aligned, the endograft was fully deployed by removing the posterior diameter-reducing tie that kept the stent-graft partially closed, pushing off the top cap and releasing the graft attachment.

Balloon expandable stents –mostly covered stents - (Ad-

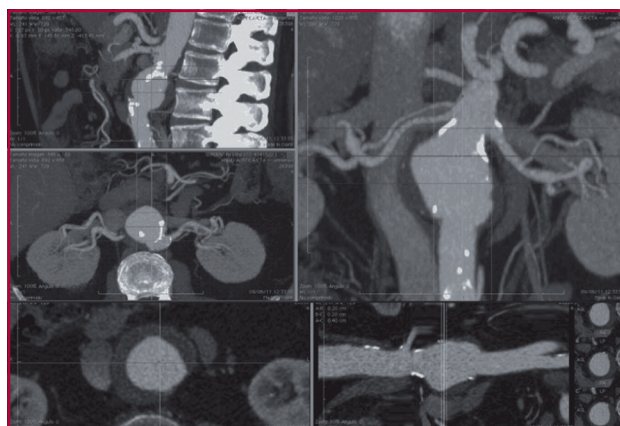


Fig. 1. High resolution computed tomography angiography images used to design the fenestrated endograft.

vanta V12, Atrium, Hudson, NH, USA), were implanted; 20% of each stent covered the corresponding visceral artery.

The distal branched component was then fully released. Finally, an angiography was performed to verify patency of the vessels and aneurysm exclusion.

Computed tomography angiography was performed at one and six months for patients' follow-up. Patients with kidney failure underwent computed tomography scan and Doppler ultrasound of the abdominal aorta and its branches.

RESULTS

The six patients included in this study are the first ones treated with this technique. All of them were men, with an average age of 73 years (65 to 85 years). The average size of the aneurysm was of 59 mm (range 54 to 74 mm). All patients had either a proximal neck size < 5 mm or the neck was absent.

All the stent-grafts were successfully implanted. Twenty visceral arteries (mean, 3 per patient) were preserved. Both renal arteries and the superior mesenteric artery were most commonly included. In one case, it was not possible to cannulate one main renal artery and a conduit was used to cannulate an accessory renal artery.

No deaths were reported. There was no need to make any reintervention and all the preserved branches were patent at the first CT scan. No endoleaks were detected.

Twenty visceral arteries were preserved by the fenestrations, including 10 renal arteries using small fenestrations, five superior mesenteric arteries and four celiac trunks with large fenestrations and three scallops. AdvantaV12TM covered stents were used to fix and seal the fenestrations (14 stents) while balloon expandable stents were used for fixation and alignment (7 stents).

The average duration of the procedure was of 340 minutes (range, 270-450 minutes). Three patients required therapy with blood substitutes.

Mean stay at the intensive care unit was of 3.8 days (range, 3-5 days) and total average in-hospital stay was of 5.6 days (range 5-11 days).

All the patients were followed-up with computed tomography with or without contrast material and Doppler ultrasound. The studies performed at one month determined the patency of all the visceral arteries and the absence of endoleaks (Figure 2).

DISCUSSION

The risk of surgical treatment of abdominal aortic aneurysm (type IV thoracoabdominal aneurysm) with involvement of the visceral arteries or close to the origin of these vessels is high. Conventional repair (4-6) or hybrid procedures have been described (8, 9); yet, the incidence of complications is high, even in high-volume surgical centers.

According to the current guidelines of the AHA, open or endovascular repair of abdominal aortic aneurysms have the same class of recommendation, and the choice of the technique depends on the arterial anatomy and on physician's and patient's preferences. (10) However, the benefit of endovascular treatment compared to open aortic repair is even greater in patients with thoracic or thoracoabdominal aneurysms. In these patients, implantation of fenestrated or branched stent-grafts is a less aggressive option. (11-13)

Yet, five essential requirements are necessary to use this technique: adequate anatomy, experienced treatment team, technology in diagnostic images, logistics and high investment costs.

Anatomic issues, such as visceral aortic segments with severe tortuosities or calcifications, possibilities of embolism, stenosis of the visceral branches, or accessory renal branches may complicate surgery. The presence of a previous conventional graft or endograft may make the procedure difficult and a conduit could be needed.

Our center has important experience with implantation of conventional endovascular stent-grafts. In addition, one of our members received training in thoracoabdominal aneurysms in the Cleveland Clinic under the program "International Guess Scholarship", American College of Surgeons.

Our diagnostic imaging technology ensures safer procedures. Computed tomography angiography im-

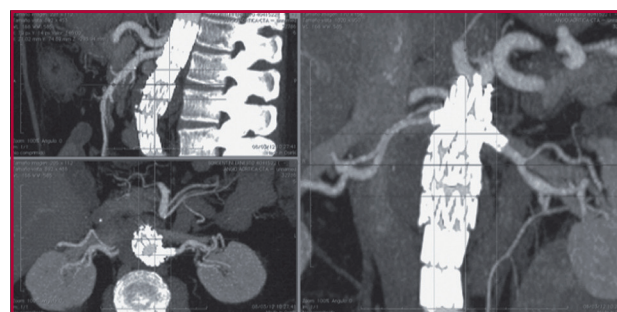


Fig. 2. Computed tomography image showing exclusion of the aneurysm with patent visceral branches.

ages and images analysis with specialized software (CTexpressorOsirix) allow a better visualization and understanding the arterial anatomy.

Several aspects related to logistics should be discussed. Time is the most limiting issue. As endograft making may take several weeks, other techniques such as chimney grafts, (14) snorkel, (15), sandwich or octopus technique have been developed. Also, fenestrations can be made in the operation room. All these techniques use off-label devices. Yet, the complications of these procedures may be insoluble or even lethal. For these reason, we prefer to use commercially available endografts in elective procedures.

CONCLUSIONS

This experience is the most important carried out in our country by a single surgical team. In these patients, in whom conventional treatment has high technical risk, endovascular approach is a less invasive and safe technique. However, it requires technical and technological support. This approach needs greater technology, training, specific materials and perioperative care, that surpass conventional endovascular treatment of aortic aneurysms.

RESUMEN

Tratamiento endovascular de los aneurismas toracoabdominales tipo IV

Introducción

Los pacientes con aneurismas toracoabdominales tipo IV se caracterizan anatómicamente por la presencia de una dilatación aórtica visceral que determina la falta de un cuello proximal aórtico adecuado para el anclaje de las endoprótesis convencionales. Para tal fin existen injertos especialmente diseñados con fenestraciones. En esta comunicación se describe la experiencia de un grupo quirúrgico en la utilización de endoprótesis fenestradas. Fueron tratados seis pacientes. Todas las endoprótesis fueron implantadas con éxito, respetando 20 vasos viscerales. Este abordaje constituye hoy una alternativa válida para el tratamiento de este grupo de pacientes candidatos a cirugía convencional de alto riesgo.

Palabras clave > Aneurisma de la aorta torácica - Stents

Conflicts of interest

None declared

REFERENCES

1. Bastos Gonçalves F, Verhagen HJ, Chinsakchai K, van Keulen JW, Voûte MT, Zandvoort HJ, et al. The influence of neck thrombus on clinical outcome and aneurysm morphology after endovascular aneurysm repair. *J Vasc Surg* 2012;56:36-44. <http://doi.org/jjc7>
2. Hobo R, Kievit J, Leurs LJ, Buth J; EUROSTAR Collaborators. Influence of severe infrarenal aortic neck angulation on complications at the proximal neck following endovascular AAA repair: a EUROSTAR study. *J Endovasc Ther* 2007;14:1-11. <http://doi.org/d87wms>
3. Thomas B, Sanchez L. Proximal migration and endoleak: impact of endograft design and deployment techniques. *Semin Vasc Surg* 2009;22:201-6. <http://doi.org/c3hghm>
4. Chong T, Nguyen L, Owens CD, Conte MS, Belkin M. Suprarenal aortic cross-clamp position: a reappraisal of its effects on outcomes for open abdominal aortic aneurysm repair. *J Vasc Surg* 2009;49:873-80. <http://doi.org/bvnm6q>
5. Knott AW, Kalra M, Duncan AA, Reed NR, Bower TC, Hoskin TL, et al. Open repair of juxtarenal aortic aneurysms (JAA) remains a safe option in the era of fenestrated endografts. *J Vasc Surg* 2008;47:695-701. <http://doi.org/b3g6cj>
6. Wong DR, Parenti JL, Green SY, Chowdhary V, Liao JM, Zarda S, et al. Open repair of thoracoabdominal aortic aneurysm in the modern surgical era: contemporary outcomes in 509 patients. *J Am Coll Surg* 2011;212:569-79. <http://doi.org/d934mz>
7. Greenberg RK, Sternbergh WC 3rd, Makaroun M, Ohki T, Chuter T, Bharadwaj P, et al; Fenestrated Investigators. Intermediate results of a United States multicenter trial of fenestrated endograft repair for juxtarenal abdominal aortic aneurysms. *J Vasc Surg* 2009;50:730-737.e1.
8. Chaudhry T, Hobbs SD, Pinkney T, Orme R, Fox AD. Spleno-renal bypass facilitating endovascular stenting of a juxta-renal aortic aneurysm in a high risk patient. *Eur J Vasc Endovasc Surg* 2008;35:452-4. <http://doi.org/fm98df>
9. Patel HJ, Upchurch GR Jr, Eliason JL, Criado E, Rectenwald J, Williams DM, et al. Hybrid debranching with endovascular repair for thoracoabdominal aneurysms: a comparison with open repair. *Ann Thorac Surg* 2010;89:1475-81. <http://doi.org/cjrbdd4>
10. Rooke TW, Hirsch AT, Misra S, Sidawy AN, Beckman JA, Findeiss LK, et al; Society for Cardiovascular Angiography and Interventions; Society of Interventional Radiology; Society for Vascular Medicine; Society for Vascular Surgery. 2011 ACCF/AHA Focused Update of the Guideline for the Management of Patients with Peripheral Artery Disease (updating the 2005 guideline): a report of the American College of Cardiology Foundation/American Heart Association Task Force on Practice Guidelines. *J Am Coll Cardiol* 2011;58:2020-45. <http://doi.org/b2sqjh>
11. Linsen MA, Jongkind V, Nio D, Hoksbergen AW, Wisselink W. Pararenal aortic aneurysm repair using fenestrated endografts. *J Vasc Surg* 2012;56:238-46. <http://doi.org/fznvhq>
12. Malina M, Resch T, Sonesson B. EVAR and complex anatomy: an update on fenestrated and branched stent grafts. *Scand J Surg* 2008;97:195-204.
13. Bakoyiannis CN, Economopoulos KP, Georgopoulos S, Klonaris C, Shialarou M, Kafeza M, et al. Fenestrated and branched endografts for the treatment of thoracoabdominal aortic aneurysms: a systematic review. *J Endovasc Ther* 2010;17:201-9. <http://doi.org/dz2mpg>
14. Lee JT, Greenberg JI, Dalman RL. Early experience with the snorkel technique for juxtarenal aneurysms. *J Vasc Surg* 2012;55:935-6. <http://doi.org/fzk3mw>
15. Moulakakis KG, Mylonas SN, Avgerinos E, Papapetrou A, Kakisis JD, Brountzos EN, et al. The chimney graft technique for preserving visceral vessels during endovascular treatment of aortic pathologies. *J Vasc Surg* 2012;55:1497-503. <http://doi.org/fxvrnd>