

Unconventional Applications of Endovascular Devices in Acquired Structural Cardiopathies.

JOSÉ A. G. ÁLVAREZ^{MTSAC,1,2}, JOSÉ L. ALONSO^{1,2}, GUSTAVO A. LEIVA^{1,2}, †, PABLO BAGLIONI^{1,2}, MARÍA L. FERNÁNDEZ RECALDE⁴, CARLOS RIVAS³, OSVALDO D. MANUALE⁴, GUILLERMO MIGLIARO^{1,2}, ALEJANDRA MORALES LEZICA³, ALBERTO SCIEGATA^{1,2}

Received: 09/06/2012
Accepted: 09/20/2012

Address for reprints:
Dr. José A. G. Álvarez
E-mail address: jagalvarez@intramed.net

ABSTRACT

In recent years, several devices for the treatment of congenital or acquired structural cardiopathies have been designed and introduced in clinical practice. But beyond their formal indications, in situations where conventional surgical treatment has a high risk, off-label use of these devices has been reported with increasing frequency and encouraging results.

This work presents four cases of patients with low prevalence disorders who were treated with percutaneous Amplatzer® devices for indications other than those for which they were designed. An aortic paravalvular leak, an acquired Gerbode defect, an aorta to right atrium fistula and a mitral paraprosthetic leak were respectively closed with devices for vascular occlusion, atrial septal defect closure, ductus arteriosus closure and treatment of muscular interventricular communication.

In all cases the treatments were effective and patients had a favourable outcome without requiring new surgical interventions.

We conclude that, irrespective of the indications for which they were designed, the use of Amplatzer® devices in selected pathologies is a good therapeutic alternative in the hands of experienced teams in this type of treatment.

REV ARGENT CARDIOL 2013;81:147-151. <http://dx.doi.org/10.7775/rac.v81.i2.1617>

Key words

> Septal Occluder Device - Mitral Valve Regurgitation - Aortic Valve Regurgitation

Abbreviation

FC	Functional Class	PFO	Patent foramen ovale
FDA	Food and Drug Administration	RA	Right atrium
IAC	Interatrial communication	RV	Right ventricle
IVC	Interventricular communication	TEE	Transesophageal echocardiogram
LV	Left ventricle	TTE	Transthoracic echocardiogram

BACKGROUND

Amplatzer® devices designed for the treatment of structural cardiomyopathies are widely used in clinical practice. They consist of a self-expandable double disk, connected to a central core whose diameter meets the diameter of the abnormal communication to be treated.

Another feature is that they employ low-profile introducers. The method is by percutaneous implantation under fluoroscopic guidance. Their structure allows recovery and repositioning until successful deployment and release from the delivery system.

The first Amplatzer® device was designed for closure of interatrial septal defects (ISD) of the type ostium secundum, and under the name of Amplatzer Septal Occluder (ASO) it received CE marking in 1998 and the approval of the Food and Drug Administration (FDA) in December 2001. Years later, a similar device but with larger discs was approved for the treatment of multifenestrated ISD. The Amplatzer® device for ductus arteriosus closure (Amplatzer Duct Occluder, ADO), which has a single retention disk connected to a smaller diameter cone, received CE marking in February 1998 and FDA approval in May 2003. (1, 2)

^{MTSAC} Full Member of the Argentine Society of Cardiology

† To apply as Full Member of the Argentine Society of Cardiology

¹ Department of Hemodynamics and Interventional Cardioangiology, Hospital Alemán

² Department of Hemodynamics and Interventional Cardioangiology, Hospital Británico de Buenos Aires

³ Department of Cardiology, Hospital Alemán

⁴ Department of Cardiology, Hospital Británico de Buenos Aires

Recently, similar structural devices with a different morphology have been admitted for endovascular treatment of ventricular septal defect (VSD), patent foramen ovale (PFO) and peripheral vessel occlusions.

Beyond the situations for which they are designed and approved, there are references in the literature of a number of low-prevalence diseases that can be treated with these devices.

In this communication, we present four cases of acquired structural cardiopathies in adults which were resolved by using off-label Amplatzer® devices. (Author's note. Off-label: alternative or unplanned use not considered by manufacturing specifications.)

CASE REPORT 1

Aortic paravalvular leak closure

A 69 year-old man on chronic hemodialysis treatment with severe aortic valve regurgitation due to infective endocarditis underwent aortic valve replacement with a mechanical prosthesis in addition to coronary artery by-pass surgery. Postoperatively, he progressed to left-sided heart failure and left ventricular dilation.

Transesophageal echocardiography (TEE) revealed aortic reflux to the left ventricle (LV) caused by paravalvular leak located at the level of the medial transverse section. Because of patient multiple comorbidities, endovascular leak closure was performed with a 4 mm Amplatzer® Vascular Plug II device introduced percutaneously through the femoral artery.

After twelve months, the patient is stable with no signs of heart failure and the last control TEE shows a normally positioned device without significant reflux (Figure 1).

Comments

Aortic paravalvular leaks occur in 7% to 10% of patients undergoing prosthetic aortic valve replacement, and are more frequent in the supra-annular position, usually located in the posterior quadrant. (3, 4) Most are asymptomatic and about 5% are clinically significant, causing left ventricular dilation, congestive heart failure and hemolysis. Surgical resolution of these defects is still today the first choice of treatment, but it entails high mortality. (5) Percutaneous closure using Amplatzer devices has been reported in recent years in a selected group of patients with high surgical risk. Mortality rate associated with this procedure is approximately 2%. (6)

CASE REPORT 2

Left ventricular-right atrial communication closure (Gerbode defect)

A 54 year-old man diagnosed with native valve bacterial endocarditis underwent aortic valve replacement surgery. Two weeks after surgery he presented with severe aortic regurgitation secondary to periprosthetic leak, and was reoperated by Bentall surgery with valve homograft. He developed right heart failure refractory to medical treatment. A TEE revealed a 0.24 cm² leak that generated a high-speed flow between the left ventricle (LV) and right atrium (RA) at the level of the membranous septum above the tricuspid valve, with right atrial, right ventricular and inferior vena cava dilation. These findings were confirmed by magnetic resonance imaging with gadolinium. Due to the high surgical risk entailed by a third intervention, percutaneous septal closure was performed with a 4 mm Amplatzer Septal Occluder device (Figure 2).

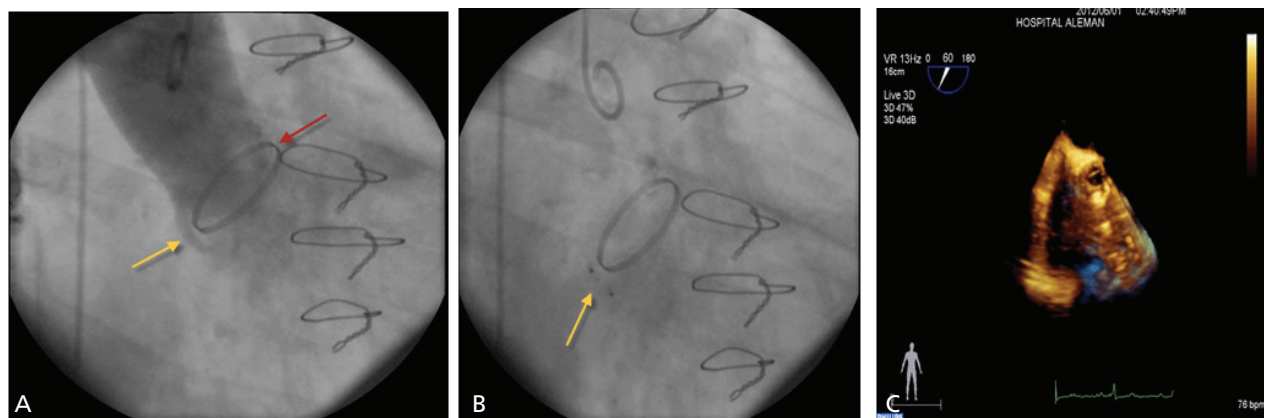


Fig. 1. Aortic paravalvular leak. **A.** Angiography showing the prosthesis in the aortic position and the paravalvular leak. **B and C.** Angiography and 3D-transesophageal echocardiography of the deployed Amplatzer Vascular Plug II ® occluding the paravalvular leak trajectory (arrows).

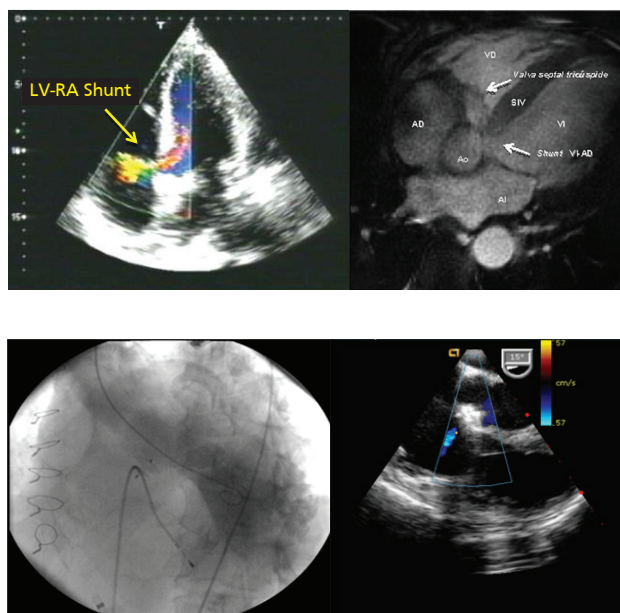


Fig. 2. Gerbode defect. **A.** Left: Four-chamber view of transesophageal echocardiogram showing the shunt from the left ventricle (LV) to the right atrium (RA) (arrow). Right: Four-chamber view of cardiac magnetic resonance image in white blood sequences, showing the shunt from the LV to the RA (arrow). RV: Right ventricle, IVS: interventricular septum. Ao: Aorta. LA: left atrium. **B.** Left: Angiographic image showing the Amplatzer® device correctly positioned with absence of contrast passage from the LV to the RA. Right: Transesophageal echocardiography in parasternal long axis view showing absence of shunt and interference in aortic and tricuspid valve functioning.

Thirty months after the procedure, the patient is asymptomatic and without signs of clinical heart failure. Transthoracic echocardiogram (TTE) shows good biventricular function, no residual leak and a normally functioning valve.

Comments

Left ventricular-right atrial communication (Gerbode defect) is produced by an interatrioventricular membranous septal defect. In its congenital form, the communication is often associated with the abnormal septal leaflet of the tricuspid valve. In the acquired form, usually secondary to infectious endocarditis, myocardial infarction or trauma in aortic or mitral valve replacement, the defect is in the atrioventricular portion of the membranous septum and the tricuspid valve is structurally normal.

Percutaneous closure with this type of devices is a previously described therapeutic option to conventional surgery. (7) The main elements to consider in these cases are the possibility of atrioventricular conduction disorders and device interference with mitral and tricuspid valve functioning. It is essential to perform TEE during the procedure to assess the degree of residual shunt and the possible involvement of neighboring valve structures.

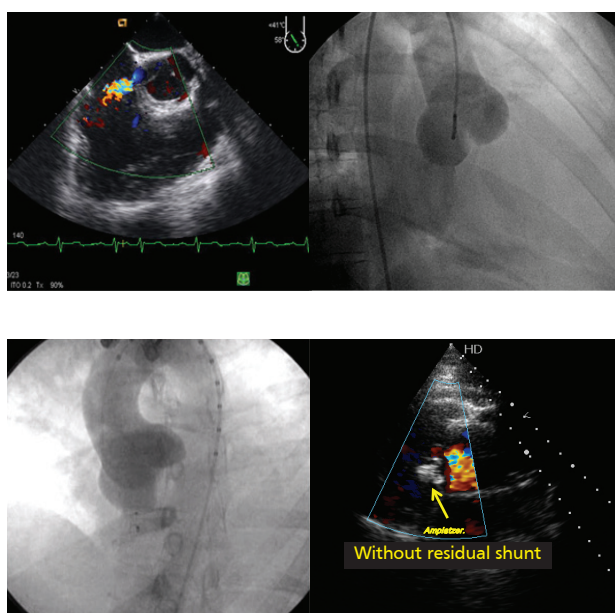


Fig. 3. Aorto-right atrial fistula. **A.** Left: Transesophageal echocardiography at the aortic level showing leak from the aorta to the right atrium. Right: Angiographic image showing aneurysmal dilation of the sinus of Valsalva and right atrial filling through the fistula. **B.** Left: Deployed Amplatzer® device with absence of contrast passage into the right atrium. Right: Transesophageal echocardiogram showing the position of the Amplatzer® device (arrow) and the absence of residual shunt.

CASE REPORT 3

Aorto-right atrial fistula

A 22 year-old woman, with a history of classical Ehlers-Danlos type (I-II) syndrome presented with dyspnea on exertion functional class (FC) III of one month evolution. An initial ambulatory ETT showed slight right atrial (43 mm) and right ventricular (30 mm) dilation, and a high-velocity shunt to the RA. Transesophageal echocardiography revealed a non-coronary sinus of Valsalva aneurysm fistulized to the RA (type IV), associated with PFO and atrial septal aneurysm (ASA). Due to the symptoms and right atrial and right ventricular volume overload, percutaneous fistula closure with Amplatzer Duct Occluder I (ADO I) was performed.

Eighteen months after the procedure the patient is asymptomatic without clinical signs of right atrial and right ventricular overload. Control TTE evidenced a normoimplanted device without residual shunt or aortic regurgitation and with slight dilation of the RV (Figure 3).

Comments

The Ehlers-Danlos syndrome involves a group of inherited disorders that result in connective tissue weakening. There are seven types of syndrome, one of which, the vascular (type IV), usually presents with rupture of arteries and bowel: The classical type I-II

of our patient may have vascular complications which are generally rare.

Sinus of Valsalva aneurysms are usually congenital (0.14% to 3.5% of all congenital heart defects) by incomplete fusion of the distal bulbar septum that separates the aorta from the pulmonary artery and attaches to the anulus fibrosus of the aortic valve, or acquired by trauma, endocarditis or degenerative diseases. Most often they involve the non-coronary sinus and the right coronary sinus. These aneurysms are usually asymptomatic and develop symptoms when they break into one of the heart chambers, most commonly the RA or RV. (8)

Surgery has been the conventional treatment of choice. Percutaneous closure has been described with Amplatzer® devices mostly for ductus closure but also for IAC. In our case an Amplatzer® Duct Occluder, introduced via femoral vein puncture, was used. (9) It is essential to ensure the correct positioning of the device, without involvement of the aortic valve or the coronary ostia.

CASE REPORT 4

Closure of paraprosthetic mitral valve leak

A 74 year old man, with a history of coronary revascularization surgery in addition to mitral valve replacement with a biological prosthesis, developed immediate postoperative mediastinitis requiring prolonged antibiotic therapy and reconstructive thoracic epiploasty. Within six months he presented episodes of heart failure with partial response to standard medical therapy. Transthoracic echocardiography revealed a paraprosthetic mitral leak with a moderate regurgitation jet into the left atrium. Transesophageal echocardiography showed normal prosthetic mitral valve functioning with leak between the mitral annulus and the interatrial septum, situated in the posteromedial quadrant, of 5.5 mm maximum diameter, and paraprosthetic regurgitation jet. Due to high surgical risk, percutaneous closure of the defect was performed

with an Amplatzer® Muscular VSD Occluder with the aid of three-dimensional TEE imaging (Figure 4). Eight months after the procedure, the patient has dyspnea FC I, with no signs of heart failure, and the ETT shows the correct functioning of the mitral prosthesis and the aortic valve with no paravalvular reflux.

Comments

Paraprosthetic mitral leak occurs in 5% to 17% of patients treated with valve replacement surgery, and is more prevalent in patients with a history of infective endocarditis and extensive annulus calcification. These leaks are generally small and mildly symptomatic, but sometimes they present with complications such as hemolytic anemia or congestive heart failure. (10) Conventional surgery remains the treatment of choice to correct these defects, but mortality is > 10% in published series. (11) Percutaneous closure has become a therapeutic option in patients with high surgical risk. (6)

DISCUSSION

Percutaneous devices to treat certain structural defects are widely used worldwide, having replaced in some pathologies conventional surgical treatment.

The first device to be approved by the FDA was the Amplatzer® Septal Occluder (AGA Inc) designed for the closure of ostium secundum type atrial septal defect. Models with similar structure but different morphology were subsequently introduced for closure of ductus arteriosus, muscular and membranous IVC, PFO and peripheral vessel occlusion.

However, there are other less common diseases whose treatment is possible by using these Amplatzer® devices, in situations different from those for which they were originally designed.

Off-label prescription of drugs and devices is a common practice in contemporary medicine. Lack of instructions for a particular procedure or condition does not imply that its use is forbidden, but that there is insufficient evidence to support its safety and efficacy in that situation. (12)

Fistulas between the aorta and the RA and the acquired Gerbode defect are very low-prevalence diseases requiring surgical treatment. The literature, however, reports some cases of successful percutaneous interventions by using off-label Amplatzer® devices. Aortic and mitral paravalvular fistulas in patients with mechanical and biological prosthetic valves are more common, but in general these patients are not treated because of the high risk involved in reoperation, with the associated impact of lower survival in patients with greater volume overload. In these cases, percutaneous closure is possible, even using devices that are not designed for the treatment of these pathologies.

In all these cases, the therapeutic decision should be taken by a team formed by a clinical cardiologist,

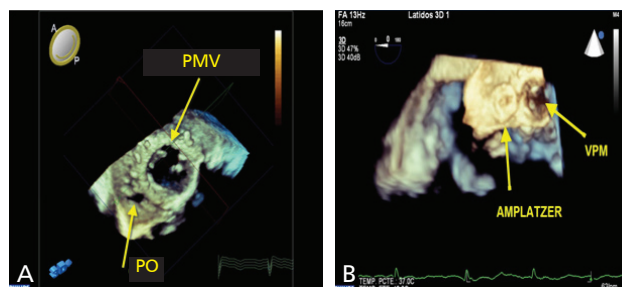


Fig. 4. A Mitral paravalvular leak. **A.** Three-dimensional echocardiographic image of the prosthetic mitral valve (PMV) and the paraprosthetic orifice (PO) responsible for the leak. **B.** Left: Final x-ray image of the deployed Amplatzer® device. Right: Three-dimensional echocardiographic image of the deployed Amplatzer® device (top view).

a cardiac surgeon and an interventional cardiologist with experience in percutaneous treatment of congenital heart disease, and the patient should be informed about the risks and probabilities of success of all possible treatments. It is essential to have high resolution radiographic and ultrasound images to approach this practice and in this sense, three-dimensional TEE is a useful tool both during planning and the procedure, especially when assessing the possible interference of the devices with adjacent structures (valvular and coronary) before deployment. Supported by a team thus formed, and even though there is no comparative surgery versus percutaneous treatment study for any of the four situations mentioned, the percutaneous approach appears as an alternative with less morbidity, especially in patients who have already been submitted to conventional surgery. A larger number of cases and long-term monitoring are necessary to establish long-term success of these procedures.

CONCLUSION

Use of off-label Amplatzer® devices is a therapeutic option to conventional surgery in certain low prevalence diseases when there is an increased surgical risk. The success rate is high and the morbidity associated with the procedure is low. The approach with high quality radiological and ultrasound imaging and a team of highly trained professionals in the percutaneous treatment of structural heart disease is essential. The addition of new specially designed devices will certainly improve results and extend their therapeutic spectrum.

RESUMEN

Aplicaciones no convencionales de dispositivos endovasculares en cardiopatías estructurales adquiridas

Introducción

En los últimos años se han diseñado e introducido en la práctica clínica habitual diversos dispositivos para el tratamiento de cardiopatías estructurales congénitas y adquiridas. Pero más allá de sus indicaciones formales, la utilización off-label de estos dispositivos en situaciones en las que el tratamiento quirúrgico convencional tiene un riesgo elevado se ha comunicado cada vez con más frecuencia con resultados alentadores.

En esta comunicación se presentan cuatro casos de pacientes con patologías de baja prevalencia que fueron tratados por vía endovascular con dispositivos Amplatzer® por

fuera de las indicaciones para las que fueron diseñados. Una fuga paravalvular aórtica, un defecto de Gerbode adquirido, una fistula de la aorta hacia la aurícula derecha y una fuga paraprotésica mitral se cerraron con dispositivos para oclusión vascular, para el cierre de comunicación interauricular, para el cierre de conducto arterioso y para el tratamiento de comunicaciones interventriculares musculares, respectivamente.

En todos los casos los tratamientos fueron efectivos y los pacientes evolucionaron favorablemente sin requerir nuevas intervenciones.

Se concluye que la utilización de dispositivos Amplatzer® en patologías seleccionadas más allá de las indicaciones para las que fueron diseñados es una alternativa terapéutica válida en manos de equipos experimentados en este tipo de tratamiento.

Palabras clave > Dispositivo ocluser septal - Insuficiencia de válvula mitral - Insuficiencia de la válvula aórtica

Conflicts of interest

None declared.

REFERENCES

1. Disponible en <http://www.ec.europa.eu/CEmarking>. Consultado el 20/06/2012
2. Disponible en <http://www.fda.gov/> Consultado el 20/06/2012
3. Dávila-Román VG, Waggoner A, Kennard E, et al. Prevalence and Severity of Paravalvular Regurgitation in the Artificial Valve Endocarditis Reduction Trial (AVERT) Echocardiography Study. *J Am Coll Cardiol* 2004;44:1467-72. <http://doi.org/b7mqkc>
4. Ionescu A, Fraser AG, Butchart EG. Prevalence and clinical significance of incidental paraprosthetic valvar regurgitation: a prospective study using transoesophageal echocardiography. *Heart* 2003;89:1316-21. <http://doi.org/ff77gz>
5. Akins CW, Bitondo JM, Hilgenberg AD, Vlahakes GJ, Madsen JC, MacGillivray TE. Early and late results of the surgical correction of cardiac prosthetic paravalvular leaks. *J Heart Valve Dis* 2005;14:792-9.
6. Ruiz C, Roubin G, Cohen H, et al. Clinical outcomes in patients undergoing percutaneous closure of periprosthetic paravalvular leaks. *J Am Coll Cardiol* 2011;58:2210-7. <http://doi.org/bh5vm8>
7. Trehan V, Ramakrishnan S, Goyal NK. Successful device closure of an acquired Gerbode defect. *Catheter Cardiovasc Interv* 2006;68:942-5. <http://doi.org/fp8k6z>
8. Sakakibara S, Konno S. Left ventricular-right atrial communication. *Ann Surg* 1963;158:93-9. <http://doi.org/dqbf9>
9. Abidin N, Clarke B, Khattar R S. Percutaneous closure of ruptured sinus of Valsalva aneurysm using an Amplatzer occluder device. *Heart* 2005;91:244. <http://doi.org/b3nxxh>
10. Remadi JP, Bizouarn P, Baron O, Al Habash O, Despins P, Michaud JL, Duveau D. Mitral valve replacement with the St. Jude Medical prosthesis: a 15-year follow-up. *Ann Thorac Surg* 1998;66:762-7. <http://doi.org/b3nr27>
11. Expósito V, García-Camarero T, Bernal J, Arnáiz E, Sarralde A, García I, Berrazueta J, Revueltab J. Reintervenciones múltiples sobre la válvula mitral: 30 años de experiencia. *Rev Esp Cardiol* 2009;62:929-32. <http://doi.org/d25sz3>
12. s. *Law Med Ethics* 2009;37:476-86. <http://doi.org/dfp88x>