

Endovascular Repair of Aortic Pseudoaneurysm as Late Complication of Aortic Coarctation Surgery

To the Editor

Coarctation of the aorta represents 5% to 8% of all cardiovascular malformations.

Surgery is the treatment of choice for this disease, though late complications as aortic dissection or rupture of pseudoaneurysms may develop. The latter are not uncommon and occur in 7% to 38% of patients undergoing surgery, with a reoperation mortality that varies from 14% to 24% according to different registries.

CASE REPORT

A 61-year old female patient was admitted to the internal medicine ward due to hemoptysis. She was a former smoker and had a history of hypertension, dyslipidemia, rheumatoid arthritis and coronary artery disease which was currently asymptomatic under medical treatment. She had been submitted to surgery for coarctation of the aorta in Brazil in 1988, without further data on this procedure.

A computed tomography scan of the thorax was performed showing a saccular dilatation in the posterior aspect of the aortic arch, with a diameter of approximately 7 cm, visualization of the true lumen inside the sac and thickened wall with localized thrombosis. The rest of the descending aorta was normal. A weak opacity resembling a pulmonary interstitial infiltrate was adjacent to the mentioned formation.

Fiberoptic bronchoscopy did not demonstrate any active bleeding site.

The patient was admitted to the coronary care unit with diagnosis of aortic disease.

An aortogram showed a 25×65 mm pseudoaneurysm of the descending aorta in front of the site of surgical repair, just below the origin of the left subclavian artery but without involving it (Figure 1). The visceral vessels and both iliac and femoral axes were patent and did not have significant lesions. The thoracic aorta was dilated (44 mm) but without evidence of aortic dissection.

After clinical and surgical evaluation, endovascular repair of the aortic pseudoaneurysm was decided.

Following implantation of a Hercules stent graft of 32 × 80 mm, the pseudoaneurysm was excluded (Figure 2) with minimal periprosthetic leak that was resolved with a second balloon inflation. Correct positioning of the stent graft was verified, with expanded coarctation site and disappearance of the aortic pressure gradient.

The patient had favorable clinical outcome without complications and was discharged on day 4.

At the long-term 8-month follow-up, the patient remained asymptomatic and a computed tomography

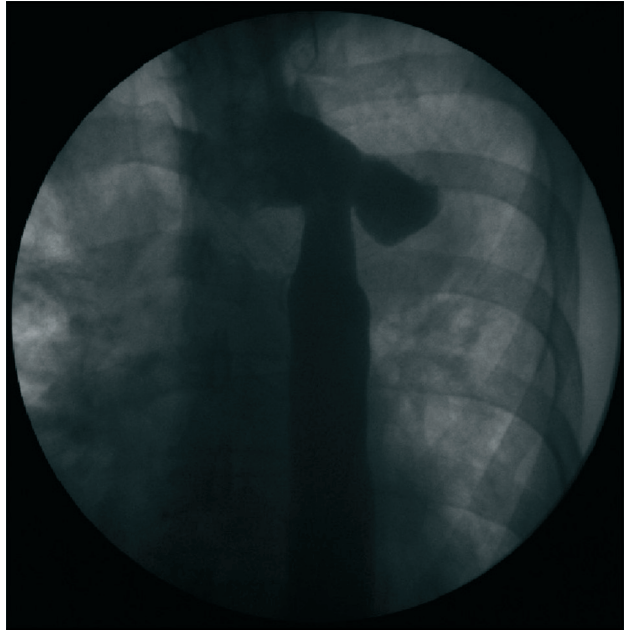


Fig. 1. Diagnostic aortogram showing pseudoaneurysm of the aorta in front of the site of the aortic coarctation surgical repair.

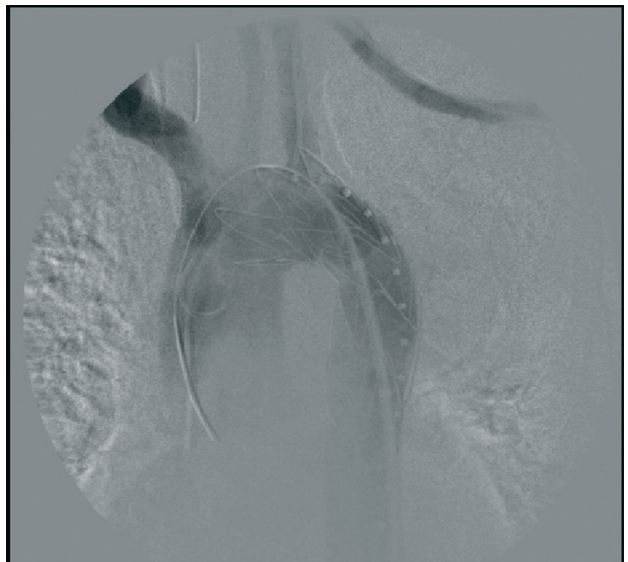


Fig. 1. Complete exclusion of the pseudoaneurysm after stent graft implantation.

angiography showed absence of complications associated with the procedure.

DISCUSSION

Among the traditional surgical techniques for the

treatment of aortic pseudoaneurysms, direct anastomosis has the lowest long-term incidence of complications.

A conservative approach is not recommended for treating complications, as Knyshov et al. reported 100% rupture rate of aortic aneurysms after 15 years, while Cohen et al. described a mortality rate of 7% due to aortic complications after aortic coarctation surgery.

Aortopulmonary fistula (APF) is the main complication of aneurysms or pseudoaneurysms, producing episodes of massive hemoptysis which may have fatal consequences if the expectoration of blood is > 600 ml.

The pathophysiological mechanism of APF is elicited by compression of the airway or pulmonary parenchyma by the pseudoaneurysm. This generates a local inflammatory response and pressure necrosis which, in turn, increases the inflammatory process. Adhesions develop and the lung suffers chronic pulsatile erosion applying tension on the pseudoaneurysm wall, which becomes critical, and finally ruptures into the airway.

Symptoms include dyspnea, coughing, hypoxemia, signs and symptoms of anemia, respiratory infections and hemoptysis. This is the most frequent symptom of pseudoaneurysms due to small APFs, which are commonly occluded by a clot that when lysed or displaced produces hemoptysis. These episodes may occur several times until the size of the communication increases and massive hemoptysis develops.

According to Picicche et al. and to Milano et al., urgent treatment should be based on the history of previous surgery, hemoptysis, presence of pulmonary infiltrates in the chest-X ray or pulmonary hemorrhage visualized in a chest computed tomography scan and presence of a pseudoaneurysm.

In this case, the disease was managed with a rapid and safe approach, avoiding the risks of performing a reoperation and thus decreasing significantly the incidence of immediate and late complications.

In addition, as hospital stay was shorter, it was possible to reduce risks and costs related to hospitalization.

**Dr. Álvaro E. Bordenave, Dr. Sergio D. Zolorsa,
Dr. Sebastián A. Rizzzone, Dr. Daniel L. Di Nanno,
Dr. Fabián Paetz and Dr. Víctor Lamelza**

Dr. Sebastián A. Rizzzone
Uspallata 3400 - CABA, Argentina
e-mail: sebastianrizzzone@yahoo.com.ar

REFERENCES

1. Bustamante N, Bochinfuso M, Rottino S, Medeat N, Uribe Echeverría A, Guzmán L. Fístulas aortapulmonar luego de 15 años de reparación de coartación de aorta. *Rev Fed Argent Cardiol* 2005;34:270-5.
2. Cohen M, Fuster V, Steele PM, Driscoll D, McGoon DC. Coarctation of the aorta. Long-term follow-up and prediction of outcome after surgical correction. *Circulation* 1989;80:840-5. <http://doi.org/fnwtem>
3. García-Pavia P, Goicolea Ruigomez J, López-Minguez J, Fresneda

Roldan P. Tratamiento endovascular de complicaciones tardías tras la reparación quirúrgica de la coartación aortica. *Rev Esp Cardiol* 2010;63:473-7. <http://doi.org/fxcx7j>

4. Gawenda M, Aleksic M, Heckenkamp J, Krüger K, Brunkwall J. Endovascular repair of aneurysm after previous surgical coarctation repair. *J Thorac Cardiovasc Surg* 2005;130:1039-43. <http://doi.org/b8mjqr>

5. Kishche S, Akin I, Ince H, Rehders T. Reparación mediante implantación de stents en enfermedades agudas y crónicas de la aorta torácica. *Rev Esp Cardiol* 2008;61:1070-86. <http://doi.org/bwx9cm>

6. Knyshov GV, Sitar LL, Glagola MD, Atamanyuk MY. Aortic aneurysms at the site of the repair of coarctation of the aorta: a review of 48 patients. *Ann Thorac Surg* 1996;61:935-9. <http://doi.org/fdm34q>

Rev Argent Cardiol 2013;81:420-421 - <http://dx.doi.org/10.7775/rac.v81.i5.3145>

Brugada-type Electrocardiographic Pattern Unmasked by Fever... and Something Else

To the Editor

Brugada syndrome (BS) is characterized by a distinctive electrocardiographic pattern in right precordial leads and risk of sudden death (SD) due to polymorphic ventricular tachycardia or ventricular fibrillation. Brugada syndrome is transmitted via an autosomal dominant inheritance pattern with more than 100 different mutations in the SCN5A gene encoding the cardiac sodium channel which produce a decrease in transmembrane sodium currents. (1) Three different ECG patterns have been described: type I, characterized by a descending ST-segment elevation ≥ 2 mm, with negative T wave in right precordial leads (coved-type ST-segment elevation); type II, characterized by ST-segment elevation ≥ 2 mm with positive T wave (saddle-back type ST-segment elevation) and type III, defined as any of the two previous types if ST-segment elevation is ≤ 1 mm. Type I is the only one that is considered diagnostic of the disease. However, the electrocardiogram (ECG) can vary in the same patient at different times not only across the different patterns, but also be temporarily normal. (2) It is well known that sodium channel blockers potentiate these electrocardiographic abnormalities. Moreover, other situations and drugs, such as electrolyte disturbances, cocaine abuse and tricyclic antidepressants can produce ST-segment elevation in these patients. (1-3) Body temperature is another important modulator of sodium channels, and fever can not only unmask silent forms of BS but also increase the risk of ventricular arrhythmias. (4-6)

CASE REPORT

A 64 year-old man presented to the Emergency Department due to stabbing chest pain on the right side suggestive of pleuritic pain of 24-hour duration, with a feeling of abnormal body temperature and dyspnea. At admission, the patient had mild tachypnea, low-grade fever of 37.4 °C and basal crackles in the up-

per right field. The chest X-ray showed a consolidation of the upper right lung lobe. The laboratory tests showed leukocytosis with granulocyte predominance (white blood cells $15850/\text{mm}^3$ with 88% granulocytes), hypoxemic respiratory failure (pO_2 57 mm Hg, pCO_2 27 mm Hg, pH 7.44) and normal electrolytes (Na 138 mEq/L, K 4.8 mEq/L). A computed tomography angiography ruled out pulmonary embolism. Of importance, the patient had a history of paroxysmal atrial fibrillation without structural heart disease which had been treated with flecainide (half tablet orally bid) and nebivolol (half tablet daily) for the last two years. In a recent medical visit he was asymptomatic with an ECG only showing incomplete right bundle

branch block. The ECG at admission showed ST-segment elevation in right precordial leads suggestive of Brugada-type I pattern (Figure 1 A). The patient received continuous monitoring and was treated with antibiotics, antipyretics and O₂. A new ECG recorded 12 hours later while the patient was afebrile and with 96% O₂ saturation showed Brugada-type III pattern (Figure 1 B) that had disappeared at discharge (Figure 1 C).

DISCUSSION

Brugada syndrome was first described in 1992 and its prevalence has been estimated in approximately 5/10000 inhabitants, being the cause of up to 20% SD that occur in normal hearts. (1) As the ECG pattern varies with time and can even be transiently normal, a sodium channel blocker challenge test is recommended in patients with inconclusive ECG. Intravenous flecainide is generally used and the diagnosis of BS is made when type I pattern develops or becomes more evident. Several factors modify the ECG pattern in these patients. (1, 3, 6) Experimental studies have demonstrated that, in some SCN5A mutations, the activity of cardiac sodium channels is temperature-dependent, and hence increased temperature accentuates the premature inactivation of these channels. (4) In our case, the patient had been medicated with oral flecainide for two years without presenting electrocardiographic abnormalities. A Brugada-type ECG pattern was only unmasked during mild fever and hypoxemic respiratory failure.

**Dr. Rebeca González, Dr. Jesús Zarauza,
Dr. María José Rodríguez Lera, Dr. Josefina Pérez**
Hospital Sierrallana
Emergency and Cardiology Service
Cantabria, España

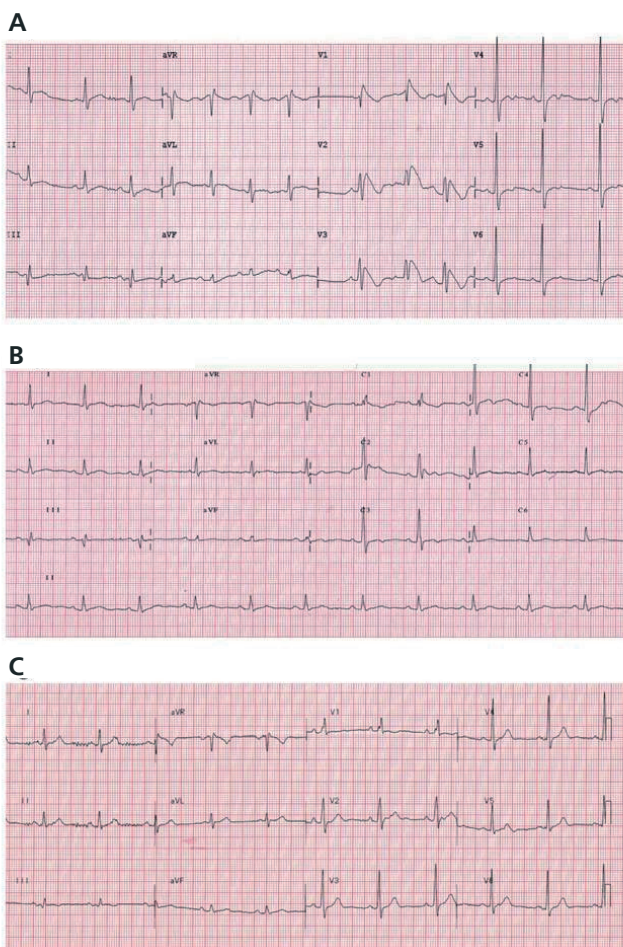


Fig. 1. Electrocardiographic evolution. A. First ECG recorded when the patient arrived at the Emergency Department, showing ST-segment elevation $\geq 2\text{mm}$ in right precordial leads with negative T wave compatible with coved type ST-segment elevation or type I Brugada pattern. B. The following morning, the ECG had ST-segment elevation $< 2\text{mm}$ with negative T wave in V1 and positive T wave in V2 (saddle-back type pattern), suggestive of type III Brugada pattern. C. ECG before discharge, showing nearly normal repolarization in the same leads.

REFERENCES

1. Benito B, Brugada J, Brugada R, Brugada P. Síndrome de Brugada. *Rev Esp Cardiol* 2009;62:1297-315. <http://doi.org/d5j8m2>
2. Wilde AA, Antzelevitch C, Borggrefe M, Brugada J, Brugada R, Brugada P, et al. Proposed diagnostic criteria for the Brugada syndrome. *Eur Heart J* 2002;23:1648-54.
3. Fish J, Antzelevitch C. Role of sodium and calcium channel block in unmasking the Brugada syndrome. *Heart Rhythm* 2004;1:210-7. <http://doi.org/fbd64q>
4. Erdogan O, Hunuk B. Frequency of Brugada type ECG pattern in male subjects with fever. *Int J Cardiol* 2013;165:562-3. <http://doi.org/nmh>
5. Kumar V, Patel N, Van Houzen N, Saini N. Brugada-type electrocardiographic changes induced by fever. *Circulation* 2013;127:2145-6. <http://doi.org/nmj>
6. Dumaine R, Towbin JA, Brugada P, Vatta M, Nesterenko DV, Nesterenko VV, et al. Ionic mechanisms responsible for the electrocardiographic phenotype of the Brugada syndrome are temperature dependent. *Cir Res* 1999;85:803-9. <http://doi.org/nmk>