

Heart Failure I: How to Diagnose it

The heart works like a pump. It receives the blood that has flowed throughout the body, and with its contraction will pump it again to repeat the circuit. Heart failure (HF) occurs when the heart is unable to perform this action. The accumulation of blood in the veins leads to increased venous pressure and contributes to the passage of fluid into the tissues (edema), both in the legs and lungs, causing dyspnea (shortness of breath). Longer life expectancy is accompanied by an increased incidence of HF because this disease is the final stage of other conditions that have improved their prognosis (myocardial infarction, diabetes, and hypertension). It is estimated that a 40 year-old person has a 20% risk of developing HF during his or her lifetime.

CAUSES

About half of the patients with HF have a cardiovascular disease that explains its occurrence, usually a previous myocardial infarction. For the rest of the patients, causes include hypertension, diabetes, heart valve disease or diseases of the heart muscle (cardiomyopathies), and in a similar proportion the causes are unidentified (idiopathic).

SYMPTOMS

Heart failure symptoms include shortness of breath (dyspnea) due to buildup of fluid in the lungs (pulmonary edema). According to the severity of HF, it is possible to feel shortness of breath when running, walking, performing slight physical efforts (bathing), or even at rest, being unable to lie flat in bed or waking up at night due to shortness of breath (Table 1). The higher the NYHA functional class, the greater the severity of HF. Generalized swelling (edema) begins in the ankles, but it may occur throughout the body, including abdominal bloating (ascites), dilated jugular veins, and significant body weight gain. Weakness and tiredness, and also palpitations (feeling of rapid or irregular heartbeat) are common symptoms.

DIAGNOSIS

The diagnosis of HF is done with the clinical history and the physical examination. Additional tests (including electrocardiography, chest X-ray, color echo-Doppler, and magnetic resonance imaging) are used to confirm the clinical diagnosis and reveal the origin or cause of HF, as well as to assess whether the HF is accompanied of "altered" (Figure 1) (failure of the heart muscle to contract) or "preserved" ventricular function (failure of the heart to relax).

PROGNOSIS

The inclusion of "pharmacologic" and "nonpharmacologic" therapies helps HF patients to achieve compensation (that the edema disappears) and lead an almost normal life.

NONPHARMACOLOGIC THERAPY

Cooperative work among the medical team, the patient and the family is essential in HF. Hygienic-dietary measures are one of the main nonpharmacologic therapies. They include: 1) sodium restriction in the diet, which should be stricter as the disease progresses; 2) weight monitoring for early detection of fluid retention (for instance, 2 kg increase in 48 hours); 3) supervised regular exercise, which helps improve quality of life; 4) influenza and pneumococcal vaccination; 5) the patient and his or her family should understand that taking other medications (analgesics to reduce pain) may worsen HF

DIAGNOSIS

HF is a major challenge for cardiologists in the XXI century, and for HF patients to understand and follow nonpharmacologic measures and adhere to drug treatment translates into a full life without limiting symptoms.

Table 1. New York Heart Association Classification

Functional class	Activity
I	Without dyspnea on ordinary exertion
II	Dyspnea on ordinary exertion
III	Dyspnea on minimal exertion
IV	Dyspnea at rest

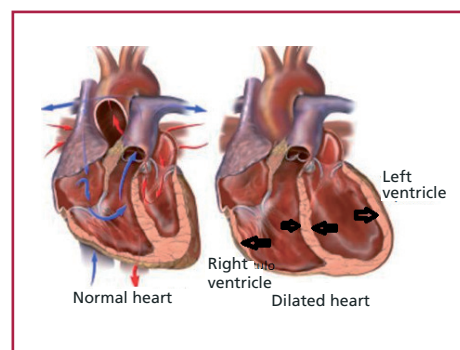
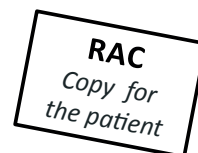

Fig. 1. Normal heart and dilated heart.



Author: Enrique Fairman, MD
Department of Cardiology, Clínica Bazterrica
Editor: Dr. Adrian Charask
Coronary Care Unit, Clínica Bazterrica/
Clínica Santa Isabel

INFORMATION YOU MAY FIND IN THE WEB

- Argentina Society of Cardiology (Consensus Area): <http://www.sac.org.ar/consensos>
- Méndez RJ, Cianciulli TF, Lax JA, Gagliardi J, Morita LA, Guerra JE et al. Clinical presentation and echocardiographic features of patients with noncompacted myocardium. *Rev Argent Cardiol* 2013;81:451-456. <http://dx.doi.org/10.7775/rac.es.v81.i6.2144>
- www.cardiosmart.org/MI-CORAZON?sc_lang=es-US

The information provided here is intended to be informative and educational and is not a substitute of the evaluation, advice, diagnosis, or treatment recommended by your doctor.

This page cannot be photocopied for commercial purposes, unless authorized by the Argentine Journal of Cardiology.