Coronary Artery Aneurysms with Multivessel Involvement: a Case Report

To the Director

Coronary artery aneurysm is an uncommon condition; yet, its incidence has increased with the advent of novel and more sophisticated diagnostic imaging techniques. It may be caused by many etiologies, but atherosclerosis accounts for up to 50% of cases. (1) We report a case of a patient with aneurysmatic disease in the three coronary vessels, a very uncommon presentation and with controversial therapy.

A 58-year old male patient was referred to our institution due to typical angina at rest, absence of ST-segment deviations in the ECG and negative cardiac biomarkers. He had a history of hypertension and chronic kidney failure not requiring dialysis. His mother suffered a myocardial (MI) infarction at the age of 42.

Twenty years before this episode, the patient had presented an acute coronary syndrome and the coronary angiography had revealed multiple coronary artery ectasia. He had been treated with anticoagulant agents for 4 years.

A transthoracic echocardiogram (TTE) showed a 4 ×4.5-cm round cystic image in the left atrioventricular groove with preserved left ventricular function.

The coronary angiography revealed multiple aneurysmatic lesions with giant ectasia in some segments involving the three coronary arteries. A computed tomography coronary angiography (CTCA) requested for further evaluation showed diffuse dilatation of the coronary arteries. The aneurysm with maximum diameter was seen in the proximal left circumflex artery.

In view of the aneurysm size, a surgical approach was decided. The patient underwent coronary artery bypass graft surgery: left internal mammary artery bypass graft to the left anterior descending coronary artery, right internal mammary artery graft to the obtuse marginal branch and radial artery graft to the right coronary artery. The aneurysms in the three vessels were excluded, the aneurysm in the left circumflex artery having the largest diameter: 4 cm.

During the immediate postoperative period, the patient developed ST-segment elevation right ventricular infarction and refractory cardiogenic shock. He required ventricular assistance with intraaortic balloon pump and subsequent extracorporeal membrane oxygenation (ECMO) device. After the ventricular assistance was removed, the patient developed hemodynamic instability and multiple organ failure. He died 6 days after surgery. Histopathological examination of the surgical specimen showed calcified atheromatous plaques with thrombosis (AHA type VI).

Coronary artery aneurysms are a rare form of presentation of coronary artery disease. An artery aneurysm is defined as a localized dilatation exceeding the diameter of adjacent normal segments by 50%. (3)

The right coronary artery is most commonly affected, but multivessel involvement is very rare.

This entity predominantly affects middle-aged male patients between 54.4 and 65.9 years. (4, 5) The incidence ranges between 0.3% and 4.9% in patients with coronary artery disease. (6)

The most common etiologic factor for coronary aneurysms is atherosclerotic disease in 50-70% of cases. Other possible causes include congenital defects, vasculitis, connective tissue disorders, drugs and trauma. (1)

Myocardial ischemia is the most common presentation, while aneurysmatic rupture or sudden death is a rare complication.

Coronary angiography is the gold standard for the diagnosis, allowing the evaluation of aneurysm size, shape, location and number of lesions. False negative results may occur in case of thrombotic luminal occlusion. Non-invasive assessment includes echocardiography, MSCT scan or magnetic resonance imaging. The presence of a cystic mass in the atrioventricular groove in the TTE is suggestive of this entity.

The therapeutic approach includes dual antiplatelet therapy, anticoagulation and revascularization. (3) The latter depends on aneurysm size, while endovascular repair is indicated for <10 mm-diameter aneurysms. Bypass graft surgery with aneurysm isolation is preferred for larger aneurysms.

This case report represents an atypical manifestation of an uncommon clinical condition: giant aneurysms of the three coronary vessels with typical angina at rest. The complementary tests allowed the evaluation of aneurysm morphology and helped to establish the surgical approach. Finally, the histopathological examination demonstrated the atherosclerotic etiology.

Santiago Del Castillo,
María Eugenia García Guzzo,
Ezequiel Guzzetti, Aníbal Arias[MTSAC],
Ricardo Marenchino, César Belziti [MTSAC]
Hospital Italiano de Buenos Aires

REFERENCES

1. Pahlavan P, Niroomand F. Coronary artery aneurysm: a review. ClinCardiol 2006;29:439-43. http://doi.org/bnbxb3

2. Yang E, Kapoor N, Gheissari A, Burstein S, et al. Coronary and intracerebral artery aneurysm in a young adult with acute coronary syndrome. Tex Heart Inst J 2012;39:380-3.

3. Nichols L, Lagana S, Parwani A. Coronary artery aneurysm: a review and hypothesis regarding etiology. Arch Pathol Lab Med 2008;132:823-8.

4. Daoud AS, Pankin D, Tulgan H, Florentin RA. Aneurysms of the coronary artery: report of ten cases and review of literature. Am J Cardiol 1963;11:228-37. http://doi.org/dvvds6

5. Groenke S, Diet F, Kilter H, Boehm M, Erdmann E. [Characteristics of patients with coronary ectasian with and stenotic coronary artery disease] Dtsch Med Wochenschr 2005;130:2375-9. http://doi.org/fkwmzw

6. Syed M, Lesch M. Coronary artery aneurysm: a review. ProgCardiovasc Dis 1997;40:77-84. http://doi.org/dc4sxv

Rev Argent Cardiol 2014;82:146-147 - http://dx.doi.org/10.7775/rac.v82.i2.2303

Percutaneous Circulatory Support with Impella 2.5 During Unprotected Left Main Percutaneous Coronary Intervention with Cardiogenic Shock

To the Director

An increasing number of patients with complex coronary artery anatomy, including the left main coronary artery, are being treated with percutaneous coronary-interventions.

Ventricular assist devices (VADs) may be useful for patients at risk of developing hemodynamic instability or for those with cardiogenic shock (CS) due to a coronary event. Yet, the role and the superiority of VAD over intraaortic balloon pump (IABP) are not completely defined. (1)

We report a case of a percutaneous coronary intervention of the left main coronary artery supported by a percutaneous Impella LD 2.5VAD.

A 47-year old male patient with a history of current smoking and dyslipidemia was admitted due to angina with ST-segment elevation. He rapidly developed cardiogenic shock with systolic blood pressure (SBP) of 50 mm Hg and confusion, requiring endotracheal intubation, central venous line placement and vasopressors; norepinephrine infusion was increased to a rate of 20 μg/min, and a SBP of 85 mm Hg was attained.

The patient was transferred to the coronary care unit while the catheterization laboratory was being prepared. A Swan-Ganz catheter was introduced; the cardiac index was 1.3 L/min/m^2 and the capillary pulmonary wedge pressure was 28 mm Hg. Dobutamine infusion was started but was not well tolerated leading to hemodynamic impairment, requiring increased norepinephrine infusion at a rate of 30 μg/min.

Once the patient arrived at the cath lab, an IABP was implanted and a coronary angiography was performed, showing severe stenosis of the left main coronary artery and a normal right coronary artery (Figure 1 A and B).

As the patient´s hemodynamic instability persisted with hypotension (SBP of 60 mm Hg) despite norepinephrine infusion at a rate of 35 μg/min and pulses of phenylephrine infusion plus dobutamine at a rate of 7.5 μg/kg/min and IABP, a percutaneous axial Impella 2.5VAD was inserted. The procedure took 5 minutes from the initial puncture to fluoroscopic confirmation of appropriate placement (Figure 2).

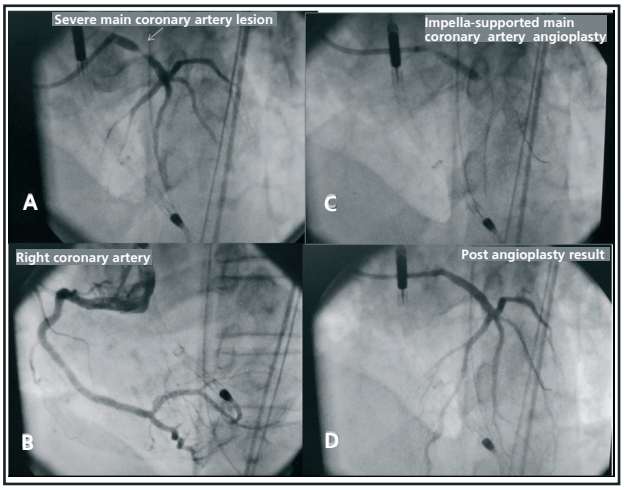

Fig. 1. A y B. Impella device-supported coronariography. **C.** Main coronary artery angiography. **D.** Post angioplasty result.

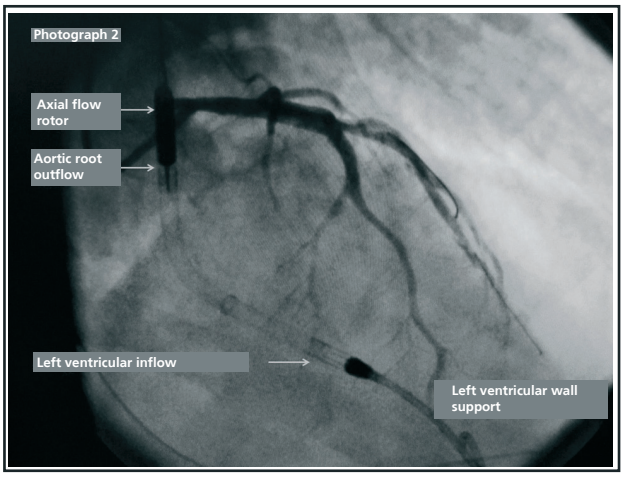

Fig. 2. Parts and placement of the Impella device.

A stent was successfully implanted in the left main coronary artery under VAD support (Figure 1 C and D). The Impella device was useful to stabilize the patient rapidly and norepinephrine infusion was reduced to 5 μg/min. When the patient returned to the coronary care unit, his blood pressure was of 120/70 mm Hg. He was in sinus rhythm, with a heart rate of 90 bpm under norepinephrine infusion at a rate of 2.5 μg/min and dobutamine infusion rate of 5 μg/kg/min.

Ventricular assistance was reduced when cardiac index returned to normal values (2.8 l/min/m2) and pulmonary capillary wedge pressure decreased to 14 mm Hg. The VAD was removed 5 hours later and IABP was maintained for 12 hours. The endotracheal catheter was removed the following morning.

This case report demonstrates that the use of the Impella 2.5 device (Abiomed Inc., Danvers, MA, USA) is feasible and useful to support the high-risk percutaneous coronary intervention of an unprotected left

main coronary artery in the setting of CS refractory to vasopressors, mechanical ventilation and IABP, allowing coronary artery flow restoration.

The Impella LD 2.5VAD is a miniaturized axial flow pump capable of unloading the left ventricle in an active fashion. The device works on Archimedes´ screw principle. The device aspirates blood from the left ventricle and delivers it into the ascending aorta, generating a flow of up to 2.5 l, thus reducing cardiac work, myocardial oxygen consumption and increasing cardiac output, coronary artery perfusion and tissue perfusion. (2)

The use of VAD is a favorable intervention in high-risk procedures, optimizing procedure tolerance and avoiding hemodynamic and electrical complications. In this sense, IABP has been widely used, providing minor circulatory support. In addition, its action depends on viable myocardial function and a stable heart rhythm. The development of tachyarrhythmias, the presence of pacemakers or poor electrocadiographic signals interfere with adequate IABP function.

Moreover, the results of the Shock II trial question the usefulness of IABP in patients with cardiogenic shock, a concept particularly based on non-randomized studies and case reports. (3)

As opposed to IAPB, the Impella device provides active circulatory support for up to 5 days, independently of ventricular function, rhythm disturbances or presence of pacemakers, generating up to 2.5 l flow. The rotation speed is regulated by a mobile console connected to the device, and the differential pressure between the left ventricle and the aorta is displayed (Figure 3).

The ProtectII was a multicenter, prospective and randomized trial comparing the outcomes of Impella 2.5 vs. IABP as hemodynamic support in patients undergoing percutaneous coronary intervention. The use of Impella was associated with improved outcomes when extensive revascularization was performed (major adverse events 33% vs. 48% at 90 days; p = 0.008). (4)

Fig. 3. Impella 2.5 device console

The study excluded high-risk patients: patients resuscitated from cardiac arrest, CS and ST-segment elevation myocardial infarction, as in our case. An analysis of the 10 patients excluded from the study detected that 80% of patients were hemodynamically stable during the procedure. (5)

These investigations suggest the superiority of the Impella 2.5 device over IABP, particularly in high-risk patients; yet, randomized studies have not reported greater survival.

At present, the use of percutaneous support in patients with CS or in unstable patients undergoing high-risk percutaneous coronary intervention is increasing, as in the case reported here.

Device implantation and explantation were easy procedures, with no complications and with an implantation time of 5 minutes. Bautista-Hernández et al. reported similar results with implantation time < 10 minutes in 6 patients undergoing percutaneous coronary intervention of the left main coronary artery. (6)

Cardiogenic shock is the most common cause of death in patients with myocardial infarction. The Shock Trial Registry reported in-hospital mortality of 79% in patients with severe stenosis of the left main coronary artery compared with 40% in those with one-vessel disease. Percutaneous ventricular assistance seems a reasonable option for fast stabilization of patients who rapidly develop hemodynamic instability, optimizing tolerance to revascularization.

The feasibility of this approach is demonstrated in different series and cases as ours. Further studies should determine if this type of interventions is also associated with increased survival.

Ricardo L. Levin[MTSAC],
Marcela A. Degrange[MTSAC],
Rafael Porcile[MTSAC],
Jorge Balaguer, John Byrne
Vanderbilt University Medical Center. Nashville, TN, USA
Department of Cardiology.
Universidad Abierta Interamericana, Buenos Aires, Argentina

REFERENCES

1. Sjauw KD, Engstrom AE, Henriques JP. Percutaneous mechanical cardiac assist in myocardial infarction. Where are we now, where are we going? Acute Card Care 2007;9:222-30. http://doi.org/bkrkh3

2. Remmelink M, Sjauw KD, Henriques JP, de Winter RJ, Koch KT, van der Schaaf RJ, et al. Effects of left ventricular unloading by Impella recover LP2.5 on coronary hemodynamics. Catheter CardiovascInterv 2007;70:532-7. http://doi.org/dkcx46

3. Thiele H, Zeymer U, Neumann F-J, Ferenc M, Olbrich HG, Hausleiter J, et al. Intraaortic balloon support for myocardial infarction with cardiogenic shock. N Engl J Med 2012;367:1287-96. http://doi.org/ngc

4. Popma JP, Moses J, Kleiman N, et al. Impella improves clinical outcomes when extensive revascularization is performed: The Protect II Study. JACC 2012;59:E1522. http://doi.org/qx9

5. Liu W, Barbagelata NA, Fujise K. Percutaneous hemodynamic support (Impella) in patients with advanced heart failure and/or

cardiogenic shock not eligible to PROTECT II Trial. J CardiacFail 2012;18:S101. http://doi.org/qzb

6. Bautista-Hernández V, Gutiérrez F, Pinar E, Gimeno JR, Arribas JM, García-Puente J y cols. Experiencia inicial con la asistencia ventricular izquierda tipo "Impella"para el shock cardiogénicoposcardiotomía y la angioplastia de tronco coronario izquierdo no protegido con baja fracción de eyección ventricular izquierda. Rev Esp Cardiol 2007;60:984-7. http://doi.org/ck2v3t

Rev Argent Cardiol 2014;82:147-149 - http://dx.doi.org/10.7775/rac.v82.i2.3182

Inverted Takotsubo syndrome

To the Director

Takotsubo syndrome is characterized by left ventricular wall motion abnormalities (akinesia of the apical and mid-ventricular segments) mimicking an acute coronary syndrome triggered by an episode of acute stress.

We report the case of a 28-year old female patient, hospitalized due to abdominal pain related to a renal colic requiring intravenous analgesia. After 24 hours of hospitalization, she underwent endoscopic ureterolithotomy under general anesthesia. In the immediate postoperative period, the patient presented dyspnea and decreased oxygen saturation. Chest X-ray showed pulmonary venous congestion. Six hours later she presented oppressive pain in the epigastric region. The electrocardiogram showed flattened T waves in lateral leads. The echocardiogram showed hypokinesia of the mid-anterior segments. Coronary angiography revealed normal coronary arteries (Figure 1 A) with mid–segment akinesia and preserved wall motion in the apical and basal segments (Figure 1 B). The echocardiogram performed 1 month after discharge showed normal left ventricular systolic function with absence of regional wall motion abnormalities.

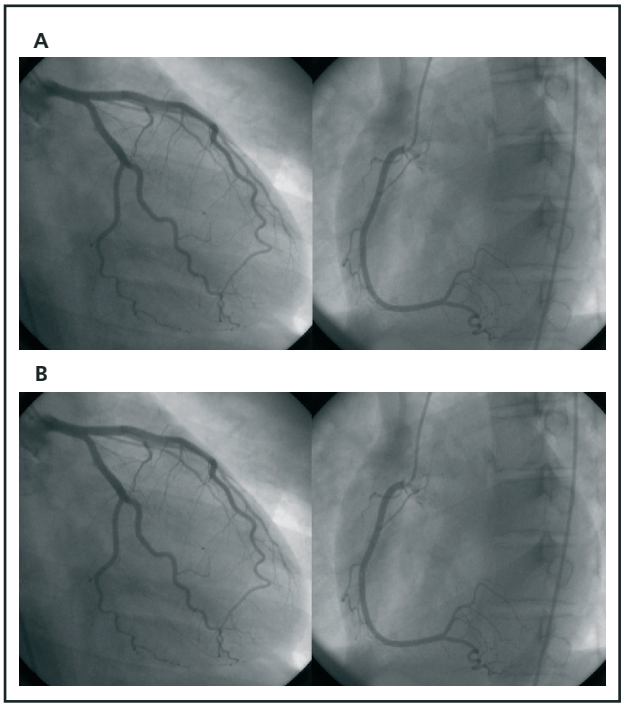

Fig. 1. Electrocardiogram at the time of admission shows an inferior, posterior, low lateral subepicardial lesion, and signs of RV infarction.

The Takotsubo syndrome was described in the nineties as apical ballooning syndrome, and represents 1.2% of patients undergoing coronary angiography to rule out acute coronary syndrome with elevation of cardiac biomarkers. (1) New variants have been described; the inverted Takotsubo cardiomyopathy is characterized by akinesia of the mid ventricular segments with normal wall motion in the basal and apical segments. Its clinical presentation and outcome do not differ from the traditional presentation, and its prevalence is unknown. In one series, 40% of cases were inverted Takotsubo. (1) The exact pathophysiology of this variant is still unknown, but may be related to the natural history of a classical form (recovery period) or a mild variant of the classical form. (2, 3).

Alejandro E. Contreras[MTSAC], Adolfo Ferrero Guadagnoli, Eduardo J. Brenna
Department of Cardiology and Interventional Cardiology, Hospital Privado Centro Médico de Córdoba, Córdoba
e-mail: aletreras@hotmail.com

REFERENCES

1. Kurowski V, Kaiser A, von Hof K, Killermann DP, Mayer B, Hartmann F, et al. Apical and midventricular transient left ventricular dysfunction syndrome (tako-tsubo cardiomyopathy): frequency, mechanisms, and prognosis. Chest 2007;132:809-16. http://doi.org/bjb97z

2. Núñez Gil IJ, García-Rubira JC, Luaces Méndez M, Fernández-Ortiz A, Vivas Balcones D, González Ferrer JJ, et al. [Transient left midventricular dyskinesia: clinical features of a new variant]. Rev EspCardiol 2008;61:322-6. http://doi.org/fcfvqt

3. Prasad A, Lerman A, Rihal CS. Apical ballooning syndrome (tako-tsubo or stress cardiomyopathy): a mimic of acute MI. Am Heart J 2008;155:408-17. http://doi.org/ccdpjr

Rev Argent Cardiol 2014;82:149 - http://dx.doi.org/10.7775/rac.v82.i2.3132

Value of Multislice Computed Tomography in the Assessment of the Single Ventricle and its Surgical Steps

To the Director

In Argentina, 5000 children with congenital heart defects are born each year; 70% of whom require surgery before the first year of life. The abnormal ventricular formation known as "single ventricle",accounts for 1% of these cases.

The single ventricle is characterized by the presence of a single dominant ventricular chamber which receives the blood from the two atria, either through the mitral or tricuspid orifices or a common atrioventricular valve. It may also be accompanied by a rudimentary accessory chamber connected with the domi-

nant chamber via a bulboventricular foramen. Of the three types of single ventricle (left ventricular, right ventricular or indeterminate), the left ventricular type is the most common (80%). The single ventricle may be associated with L-transposition or D-transposition (85%) of the great arteries and with pulmonary stenosis or atresia (50%).

Management of this defect involves a two or three-step surgical procedure according to the patient's age, comorbidities, symptoms and hemodynamic status.

If pulmonary stenosis and severe cyanosis are present during the first two months of life, the intervention begins with aorta-to-pulmonary shunt using the Blalock-Taussig technique which consists in connecting a branch of the aorta with a pulmonary artery branch to direct more blood to the lungs.

The Norwood procedure is used in other cases. In this technique, the main pulmonary artery is transected and the ductus is ligated. An output is established from the ventricle to the hypoplastic aorta using the main proximal pulmonary artery to reconstruct the ascending aorta and the aortic arch.

The Glenn operation is usually performed around six months of age. The superior vena cava is connected to the pulmonary artery so that the deoxygenated blood coming from the superior vena cava avoids the heart, keeping the passage of deoxygenated blood from the inferior vena cava to the heart, reducing left ventricular volume overload. The Glenn technique is usually considered as the first stage of the Fontan-Kreutzer procedure.

Then, at the age of 3 and with a weight of about 13 kg, the inferior vena cava is connected to the pulmonary artery, producing total cavopulmonary anastomosis. Two techniques are currently used to perform the anastomosis: the intracardiac lateral tunnel or the external fenestrated conduit (extracardiac Fontan procedure). The former technique does not require anticoagulant therapy and the latter has lower risk of arrhythmias and thrombotic complications.

In other cases, a prosthetic conduit is placed between the ventricle and the pulmonary artery (Sano technique). This procedure limits pulmonary flow only to systole and improves the hemodynamic stability and surgical survival.

Diagnostic imaging techniques as computed tomography (CT) scan and magnetic resonance imaging (MRI) provide information about the anatomy of the different cardiac structures and the frequent extracardiac structure involvement during the evaluation of these patients before and after surgery.

Computed tomography has some advantages over MRI in the evaluation of pediatric patients: better spatial resolution, shorter exploration time and lower cost. The open gantry gives the child the possibility of visualizing the adult companion, providing safety and confidence while the child is lying down and the CT scan is being performed. If the scan has to be performed under anesthesia or sedation, lower drug doses will be necessary to complete the study due to the shorter exploration time.

We present two CT scan images from two children.

The type of surgeries performed and the anatomy after surgery, as well as obstructions or abnormalities requiring new interventions, can be identified by CT scan.

Figure 1 corresponds to a 1-year old boy; the Norwood procedure and the Sano technique can be identified. The main pulmonary artery (PA) is connected to the ascending aorta after the Norwood procedure. There are no obstructions. A prosthetic conduit between the right ventricle (RV) and the pulmonary artery (PA) is observed in the Sano technique. The conduit is patent without obstructions.

Figure 2 corresponds to a 14-year old girl who underwent bidirectional Glenn and extracardiac Fontan procedures. The superior vena cava (SVC) is connected to the right pulmonary artery (RPA) in the

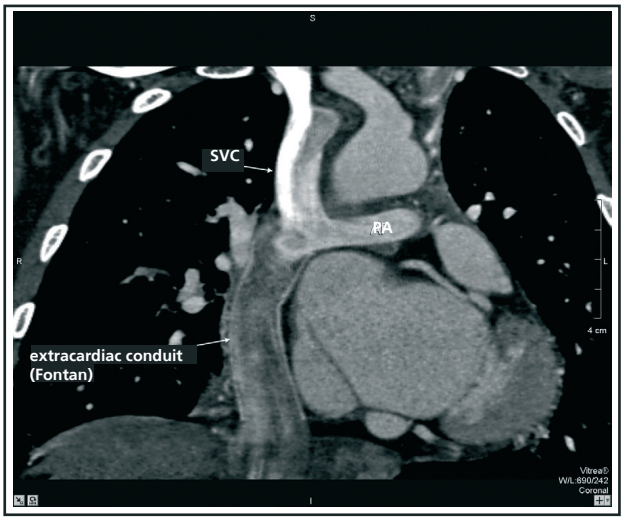

Fig. 1

Fig. 2

bidirectional Glenn technique. The anastomosis is patent, without stenosis. In the extracardiac Fontan procedure, a fenestrated external conduit connects the inferior vena cava to the pulmonary artery.

Mariana Suárez-Bagnasco, Miguel Cerdá[MTSAC], Guillermo Ganum[MTSAC]
Hospital Universitario Fundación Favaloro

REFERENCES

1. Allen HD, Driscoll DJ, Shaddy RE, Feltes TF. Moss and Adams' Heart Disease in Infants, Children, and Adolescents. 7thed. Lippincott Williams & Wilkins; 2008

2. Gilkeson RC, Ciancibello Leslie, Zahka Kenneth. Multidetector CT evaluation of congenital heart disease in pediatric and adult patients. Am JRoentgenol 2003;180:973-80. http://doi.org/qzd

3. Goo HW, Park IS, Ko JK, Kim YH, Seo DM, Yun TJ, et al. CT of congenital heart disease: normal anatomy and typical pathologic conditions. RadioGraphics 2003;23:S147-65. http://doi.org/cqkkpt

4. Goo HW. State of the art CT imaging techniques for congenital heart disease. Korean J Radiol 2010;11:4-18. http://doi.org/cptkpr

5. Magliola R, Laura JP, Capelli H. Situación actual de los niños con cardiopatía congénita en Argentina. Arch Argent Pediatr 2000;98:130-3.

Rev Argent Cardiol 2014;82:149-151 - http://dx.doi.org/10.7775/rac.v82.i2.3932

Nonischemic Cardiac Calcifications: Imaging Contributions

In general, available publications on massive myocardial calcifications are limited to an isolated case report.

In daily practice, valvular (mitral or aortic), myocardial (particularly ischemic) or pericardial (in patients with constrictive pericarditis) calcifications can be radiologically detected. Left ventricular walls are rarely involved, while calcified thrombi on ventricular aneurysms are the most common ones. Calcification in cardiac tumors, such as rhabdomyomas or endotheliomas, is less commonly observed. In some cases, the cause of calcification cannot be identified.

Cardiac calcification is classified as either dystrophic or metastatic. Dystrophic calcifications usually occur in the area of prior myocardial infarction, while myocardial calcifications occur in normal tissues. (1) The anatomic and functional involvement and size may vary.

Dystrophic calcification is more common than metastatic calcification, and occurs on infarcted tissues (2) or previous surgeries, congenital defects, bacterial myocarditis, or by actinic effect. (3) Metastatic calcification is secondary to bone disease, hypervitaminosis, hypercalcemia, hypophosphotemia, renal failure, and dialysis. Its predisposing factors include age, hypertension, diabetes mellitus, dyslipidemia, and time on dialysis. In turbulent flows, calcification may cause microfracture, fibrosis and calcification, which in turn can be worsened by some therapies, for example, the use of anticoagulants such as warfarin. (4, 5)

This involvement, together with its underlying cause, can lead to multiple arrhythmias, end-stage heart failure, and even death. In addition, the presence of myocardial calcification of varying size may be decisive in the choice of medical or surgical treatment for each specific case.

We present three cases of uncommon, significant cardiac calcification of nonischemic etiology. The first case corresponds to an Anglo-Saxon 72-year-old female with a history of rheumatic fever during childhood. At age 65, she underwent mitral valve replacement in another center due to severe heart failure secondary to bi-leaflet prolapse. She remains asymptomatic for years. A control echocardiography during follow-up shows an apical calcification with preserved left ventricular function. Preoperative coronary angiography is reviewed, revealing the apical calcification in the different projections. Lab tests are indicated, which show normal serum calcium levels and parathyroid function. A cardiac MRI is performed, detecting the presence of a mass that obliterates the left ventricular apex and prevents contraction of viable apical segments, as evidenced by 2 and 4-chamber cine sequences showing myocardial saturation bands (tagging), and delayed enhancement. A CT scan confirms the extensive calcification of the apex and the concomitant area to mitral valve replacement (Figure 1 A & B).

The second case corresponds to an Asian 64 year-old female who comes to consultation with a control color echo-Doppler performed 5 years before due to hypertension. Images show apical calcification with normal acoustic windows. The patient was asymptomatic, with satisfactory blood pressure levels, and under drug therapy. A new echocardiography confirms previous study findings. Therefore, a cardiac MRI and CT scan are performed. The MRI shows large apical trabeculation, lateral or inferior, compatible with noncompacted myocardium. The CT scan shows an extensive calcification at the level of the apical hypertrabeculation. The patient had normal hormone and metabolic studies (Figure 2A).

The third case corresponds to a 40 year-old female, who underwent radiation therapy due to a mediastinal tumor at the age of 5. Some years later, she progresses to severe bronchiectasis, and a control echocardiography detects an extensive calcification on the left atrial free wall, with mobile thrombus on the surface. She is started on anticoagulant therapy, with image resolution during follow-up. In subsequent years, the patient progresses with decreased aortic valve area due to actinic effect, with severe calcification in the wall of the ascending thoracic aorta (Figure 2 B and C).

Cardiac calcification can occur in different clinical situations, either in symptomatic patients or in those in whom calcification is a finding in complementary tests (chest x-ray, echocardiography, cardiac MRI or CT scan).

The etiology –dystrophic or metastatic– of calcifi-

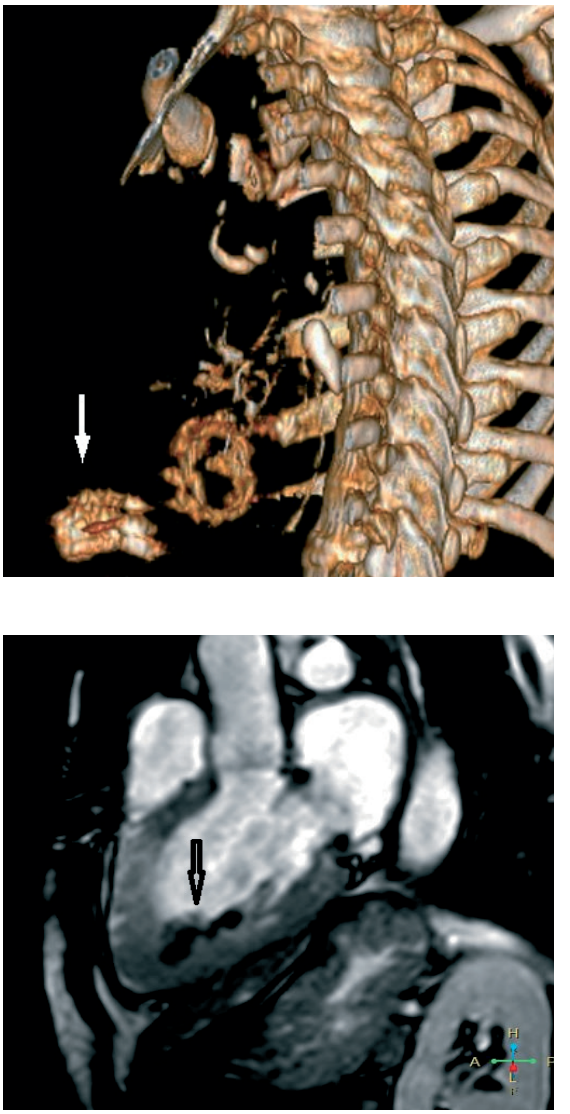

Fig. 2. A. CT scan showing a calcified apical mass (arrow) and calcification surrounding the valve prosthesis. **B.** Cardiac MRI: cine of the left ventrical outflow tract of the same patient, showing a normal functioning myocardium and absence of apical mass (arrow), without detecting necrosis in delayed enhancement sequences.

cation will define the approach to follow. In cases of severe myocardial involvement and clinical condition of heart failure, calcification may require surgical intervention, usually with discouraging outcomes.

We present three cases of nonischemic dystrophic calcification of rare etiology. The first case occurs on a rheumatic myocardium, a condition that often presents with valvular and atrial involvement. The second case occurs on a noncompacted myocardium, a rare finding except in repeat endocarditis, (6) which is absent in this case. The third case is due to actinic effect, with large involvement of vascular and cardiac structures.

Fig. 2. A. Cardiac MRI showing apical hypertrabeculation with absence of signal, secondary to calcification of noncompacted border (arrow). **B.** CT scan showing extensive calcification of the left atrial free wall (arrow) and descending aorta. **C.** Cardiac MRI of the same patient as in B, with flow acceleration in the ascending aorta (arrow) due to reduced valve opening.

The complementary methods allow quantifying not only the volume of the calcified mass but also its anatomical and functional involvement. These evaluations should be completed with hormone/metabolic

lab tests (serum phosphorus and calcium levels, kidney function).

The clinical condition and imaging methods available to the cardiologist will allow identifying its dystrophic or metastatic cause in order to follow the best therapeutic approach for this uneven population with different prognoses.

Esteban Ludueña Clos, Ramiro Feijóo, Eduardo Brunel, Mariano De Titta, Osvaldo Manuale
Department of Cardiology - Hospital Británico de Buenos Aires

REFERENCES

1. Martín-Cuartero J, Yagüe-Romeo D, Abril-Avellanas E. [Myocardial calcification in chronic renal failure]. Rev Esp Cardiol 2007;60:1092. Spanish. http://doi.org/cdvxf3

2. Cabré Ollé X, Almirall Egerique M, Pardina Solano M, Lacasta García JD. Aneurisma calcificado de ventrículo izquierdo. Emergencias 2004;16:169-70.

3. Iwatani H, Tomida K, Nagasawa Y, Imai E, Rakugi H, Isaka Y. Massive and rapid left ventricular calcification. NDT plus 2009; 2:259-60. http://doi.org/b6m3t2

4. Suárez Benjumea A, Rodríguez Pérez MA, Gascó Martos B, Salgueira Lazo M. Calcificaciones valvulares cardíacas y alteraciones del metabolismo óseo-mineral. Dial Traspl 2010;31:124-6.

5. Caballero J, Calle G, Piñero C. [Severe myocardial restriction secondary to massive calcification of the left ventricle]. Rev Esp Cardiol 1999;52:53. Spanish. http://doi.org/qzc

6. Stöllberger C, Finsterer J. [Calcified noncompaction left ventricle in mannose-binding leptin deficiency and myopathy]. Rev Esp Cardiol 2007;60:655. Spanish. http://doi.org/dmv6mj

Rev Argent Cardiol 2014;82:151-153 - http://dx.doi.org/10.7775/rac.v82.i2.3659