

Fibrillatory Conduction and Exit Block in the Pulmonary Veins. Two Mechanisms Seldom Seen During Catheter Ablation of Paroxysmal Atrial Fibrillation

Atrial fibrillation (AF) is the most common tachyarrhythmia, affecting more than 3% of the adult population. Although much progress has been achieved in the treatment of stroke, its most feared complication, there is still a gap in medical knowledge about its definite control, probably due to its complex pathophysiology and the multiple pathophysiological mechanisms grouped in triggers, modulators and substrates.

There is sufficient evidence suggesting that the pulmonary veins-left atrium junction represents a critical region involved not only in the genesis of AF in patients with appropriate substrate, but also in its perpetuation by complex microreentrant mechanisms.

Catheter ablation of atrial fibrillation is based on the use of radiofrequency in this critical zone according to anatomical and electrophysiological parameters, identifying the entry block in the pulmonary vein by abolition or dissociation of pulmonary vein potentials. However, the observation of other electrophysiological phenomena could increase the success of the procedure.

The two records presented here are an example of the concept of fibrillatory conduction and exit block at the level of the pulmonary vein in 2 patients aged 29 and 56 years, without documented organic heart disease and with no risk factors for the development of atrial fibrillation or brain embolism (CHADS₂ = 0). Both patients had recurrent AF refractory to class Ic agents.

In the two cases, the patients present AF rhythm at the moment of catheter ablation.

In the first case, atrial tachycardia originating from the pulmonary vein is observed in the circular catheter placed in the right superior pulmonary vein, and when radiofrequency ablation interrupts the tachycardia, the AF stops (Figure 1). Yet, the vein remains connected, with the record of the pulmonary vein potentials linked to atrial activity. This is an example of fibrillatory conduction from a tachycardia originating from the pulmonary vein; when the tachycardia is interrupted, the AF reverts immediately.

In the other patient, a regular tachycardia originating from the right pulmonary vein is also observed during AF (Figure 2). In this case, when isolation of the right pulmonary vein is achieved during catheter ablation, the AF is interrupted, despite the atrial tachycardia persists in the pulmonary vein (fibrillatory conduction to the left atrium, with exit block in the right inferior pulmonary vein). The atrial tachycardia originating from the vein is subsequently interrupted when radiofrequency is applied (Figure 3). In this case, conversion to sinus rhythm, despite the ar-

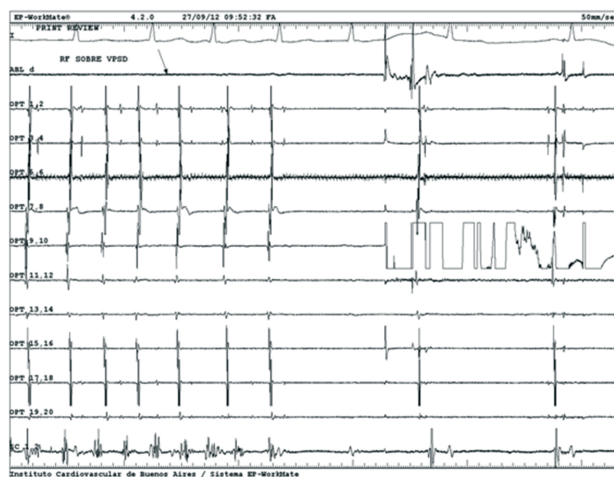


Fig. 1. Case 1. Atrial fibrillation reversion when the atrial tachycardia originating from the right superior pulmonary vein stops during catheter ablation. The patient has simultaneous atrial fibrillation [see the surface recording in lead I and the chaotic activity in the distal coronary sinus (CS)]. However, the pulmonary vein presents an atrial tachycardia [see the organized activity in the pulmonary vein, recorded by the 20-pole circular mapping catheter (OPT)]. The atrial tachycardia and the atrial fibrillation cease simultaneously [see the ECG (lead I) and the CS recording where two deflections corresponding to the atrium and the ventricle are clearly identified]. This is an example of fibrillatory conduction.

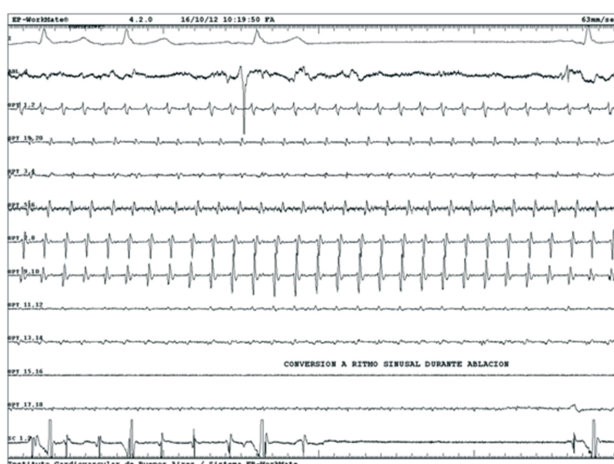


Fig. 2. Case 2. Atrial fibrillation reversion during isolation of the right inferior pulmonary vein, despite persistent atrial tachycardia in that vein. The surface record (lead I) shows conversion to sinus rhythm at the 4th beat during ablation. Simultaneously, the coronary sinus (CS) recording shows reversion to sinus rhythm. However, pulmonary vein atrial tachycardia remains unmodified despite the patient has reverted to sinus rhythm [see the organized activity in the pulmonary vein, recorded by the 20-pole circular mapping catheter (OPT)]. This is an example of a pulmonary vein exit block.

rhythmia persisting in the vein, confirms the presence of an exit block at that level, demonstrating that the pulmonary focus plays a role not only in initiating the AF but also in sustaining it.

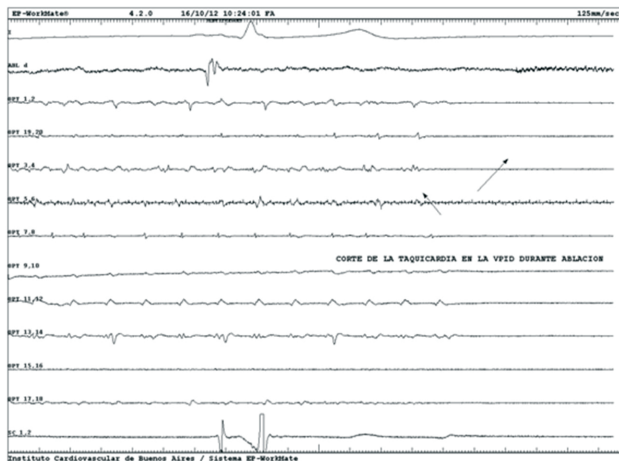


Fig. 3. Case 2. Reversion of right inferior pulmonary vein tachycardia during catheter ablation recorded with the 20-pole circular mapping catheter (OPT). The patient is always in sinus rhythm [see the coronary sinus (CS) recording and lead I].

The electrophysiological mechanisms that trigger AF have been in continuous debate throughout the years. In 1914, reentry was proposed by Garrey, who stated that AF was elicited by differences in excitability and conductivity, producing macroreentrant circular movements leading to AF. In 1964, Moe defined AF as a self-sustained process of multiple simultaneous wavelets that change, are blocked and fragmented to become new wavelets. If this mechanism is maintained, persistent AF occurs. These findings were subsequently demonstrated in 1985 by Allesie in studies performed in dog hearts. (1)

In 1981, Cheng published for the first time the results of a study in guinea pigs, showing presence of electrical activity in the proximal sites of the pulmonary veins that could originate episodes of AF. In 1998, Haissaguerre demonstrated that, in clinical studies, premature beats and rapid atrial rhythms originating in the pulmonary veins could trigger and maintain AF by generating a functional microreentry in the pulmonary veins-left atrium junction. This led to the hypothesis of focal AF, offering a novel pathophysiological concept to the traditional theory of multiple functional reentry circuits moving along the excitable atrial tissue. (3) However, clinical experience demonstrated that the effectiveness of the ablation procedure increases when all the pulmonary veins, and not only the spontaneous foci or the foci induced in the electrophysiology laboratory, are isolated. Furthermore, AF is occasionally interrupted before the triggering focus is eliminated or blocked, which is more compatible with the elimination of the substrate necessary to maintain the arrhythmia. Therefore, once again, the reentrant mechanism seems to perpetuate the arrhythmia. This made Jalife propose an integrated theory, in which AF is initiated by high frequency impulses in the pulmonary veins invading the left atrium, and if these impulses find sufficient conduction

heterogeneity, they originate multiple rotors which sustain the AF. (4) The pulmonary veins-left atrium junction has the electrophysiological and anatomical conditions to maintain these reentrant mechanisms necessary to sustain the arrhythmia. This mechanism was called fibrillatory conduction, which is the irregular conduction of a regular activation generated in the pulmonary vein. These high frequency impulses do not allow the complete recovery of the surrounding myocardium. When the focus disappears, either spontaneously or due to catheter ablation, also does the fibrillation. Once again in medicine, two conditions are necessary to develop the arrhythmia: the trigger and a structure facilitating arrhythmia persistence. This mechanism combining automatism and slow conduction would be responsible for initiating and sustaining AF, and could be limited to the veno-atrial junction in patients without documented heart disease, or could extend to the entire atrium in those with organic damage secondary to hypertension, valvular heart disease or ischemia.

Several studies have demonstrated that almost 40% of patients with successful isolation of the pulmonary veins demonstrated by the classic parameters of abolition or dissociation of the pulmonary vein potential (entry block) still have inverse conduction from the vein to the atrium, which undoubtedly increases the possibilities of AF recurrence. The exit block can be demonstrated in the electrophysiology laboratory by pacing from within the pulmonary vein without capturing the left atrium. The problem is that it is difficult to be sure that the vein is effectively captured with pacing. Therefore, the presence of atrial tachycardia or fibrillation originating in the pulmonary veins with the patient in sinus rhythm constitutes the best evidence of pulmonary vein exit block and better procedure-related outcomes. (5-7).

**Gastón Albina^{MTSAC}, Fernando Scazzuso^{MTSAC},
Diego Belardi, Luis Gómez, Andrés Klein,
Alberto Giniger^{MTSAC}**

Instituto Cardiovascular de Buenos Aires

REFERENCES

- Allesie MA, Lammers WJEP, Bonke FIM, Hollen J. Experimental evaluation of Moe's multiple wavelet hypothesis of atrial fibrillation. En: Zipes DP, Jalife J, editors. Cardiac electrophysiology and arrhythmias. New York: Grune & Stratton; 1985. p. 265-75.
- Chen YJ, Chen SA, Chang MS, Linb CI. Arrhythmogenic activity of cardiac muscle in pulmonary veins of the dog: implication for the genesis of atrial fibrillation. Cardiovasc Res 2000;48:265-73. <http://doi.org/fpvd8v>
- Haissaguerre M, Jais P, Shah DC, Takahashi A, Hocini M, Quiniou G, et al. Spontaneous initiation of atrial fibrillation by ectopic beats originating in the pulmonary veins. N Engl J Med 1998;339:659-66. <http://doi.org/bddjdv>
- Jalife J, Berenfeld O, Mansour M. Mother rotors and fibrillatory conduction: a mechanism of atrial fibrillation. Cardiovasc Res 2002;54:204-16. <http://doi.org/cdnjms>
- Gerstenfeld EP, Dixit S, Callans D, Rho R, Rajawat Y, Zado E, et al. Utility of exit block for identifying electrical isolation of the pulmonary veins. J Cardiovasc Electrophysiol 2002;13:971-9. <http://doi.org/dd7jbq>

6. Gurevitz O, Friedman P. Pulmonary vein exit block during radiofrequency ablation of paroxysmal atrial fibrillation. *Circulation* 2002;105:e124-e125. <http://doi.org/djnwbtb>

7. Frankel D, Riley M. Entrance without exit block during pulmonary vein isolation. *The Journal of Innovations in Cardiac Rhythm Management* 2011;2:459-60.

Rev Argent Cardiol 2014;82:223-225 - <http://dx.doi.org/10.7775/rac.v82.i3.2224>

Triple Papillary Fibroelastoma of the Aortic Valve Associated to Cerebral and Coronary Embolization

Papillary fibroelastomas are the most common heart valve neoplasms, and the third in frequency in other cardiac locations, after myxomas and lipomas (1) They are usually single benign lesions, but can be multiple in 7.5% of cases, although this incidence could be undervalued since surgical interventions and autopsies sometimes reveal smaller lesions overlooked by echocardiography. (2) The clinical significance of papillary fibroelastomas remains controversial; however, these neoplasms seem to be responsible for embolic events leading to transient ischemic attacks, stroke, angina, myocardial infarction, syncope and even death. We here report a patient with triple papillary fibroelastoma of the aortic valve associated with systemic embolization.

A 55-year-old Caucasian man with history of arterial hypertension, dyslipidemia and transient ischemic attack was admitted to the coronary care unit because of chest pain and a non-Q wave myocardial infarction. The laboratory tests showed high CK-MB and troponin levels, and the electrocardiogram revealed left ventricular hypertrophy. Transthoracic echocardiography identified a small mass attached to the aortic valve. Transesophageal echocardiography confirmed a non-pedunculate hyperechogenic mass of 10 mm diameter on the ventricular side of the left coronary leaflet. (Figure 1 A and B) The brain computed tomography showed a hypodense left paraventricular ischemic lesion (Figure 1 C), with a normal carotid Doppler ultrasound. The coronary angiography revealed a distal stenosis of the left anterior descending coronary artery (Figure 1 D) suggestive of coronary embolism. A multiple papillary fibroelastoma with embolic complications was suspected and the patient was referred to surgery.

At surgery, a 15-mm tumor was found in the left coronary cusp and excised, and the resultant leaflet defect was successfully repaired with a Prolene suture (Figure 2 A). Direct valve examination revealed two secondary fibrotic 5-mm lesions on the right coronary and non-coronary cusps. Both lesions were also removed, without residual defects.

Intra- and postoperative transesophageal echocardiograms showed mild residual aortic regurgitation. The postoperative period was uneventful and the patient was discharged 10-days after surgery. Histologi-

cal examination of the three lesions led to a final diagnosis of papillary fibroelastoma (Figure 2 B-D).

Papillary fibroelastomas only represent less than 10% of all cardiac neoplasms. The reported prevalence in autopsies ranges from 0.002% to 0.33%, and is 0.02% in echocardiographic series. (3) They constitute a vascular neoplasms originating from the cardiac valves or the normal components of the endocardium. Cardiac fibroelastomas have been described at any age, measuring from 0.1 to 5.7 cm. Histologically, they consist of a matrix core of dense connective tissue, surrounded by a layer of thin connective tissue covered by hyperplastic endothelial cells. The connective tissue is not the only core component; the matrix of proteoglycans also contains elastic fibers, smooth muscle cells, and rarely spindle cells resembling fibroblasts. The microscopic views of the specimens shown in Figure 2 seem to represent different stages of tumor development.

The clinical significance of papillary fibroelastomas has been extensively debated. Some studies argue that the presence of a fibroelastoma is indication for surgical excision, since even small lesions can be associated with life-threatening complications. On the other hand, asymptomatic patients with non-mobile masses can be followed-up closely with echocardiogra-

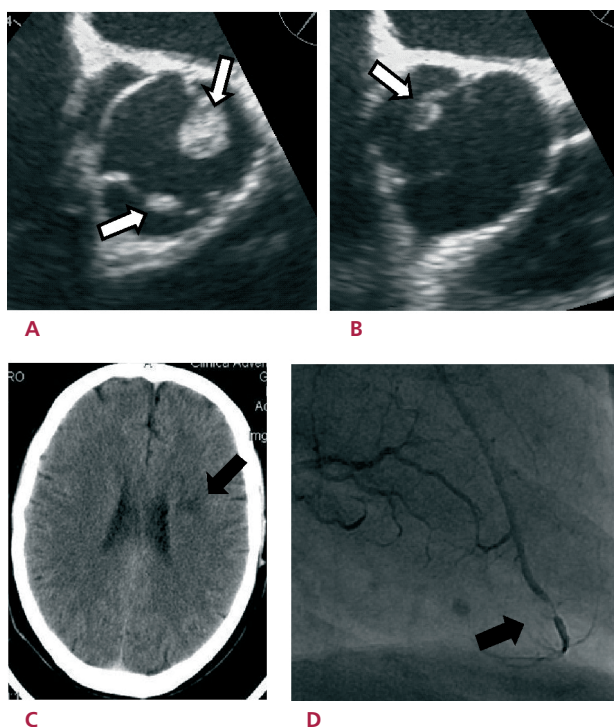


Fig. 1. A and B. Preoperative short-axis images obtained with two-dimensional transesophageal echocardiography, showing a mobile mass attached to the left coronary cusp of the aortic valve and two additional masses attached to the right coronary cusp and non-coronary cusp, respectively. C. Preoperative computed tomography scan of the brain showing an ischemic focal lesion (arrow). D. Preoperative coronary angiography with a distal stenosis of the left anterior descending coronary artery (arrow), probably due to embolism.

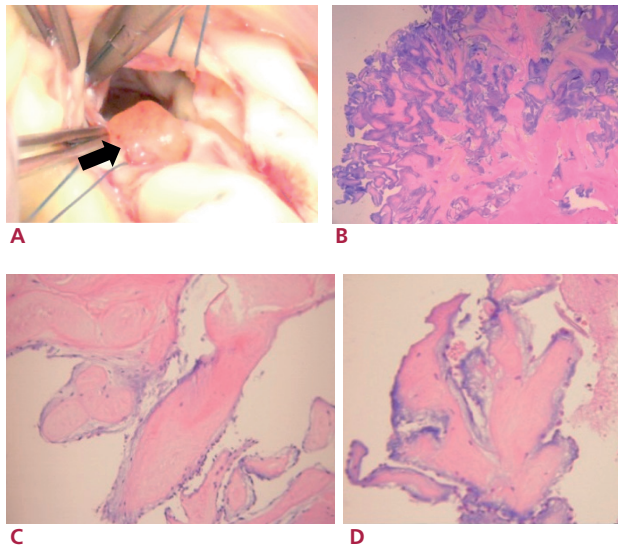


Fig. 2. Surgical and histological findings. **A.** Intraoperative view of a mass (arrow) arising from the ventricular side of the left coronary cusp. The two secondary masses attached to the right and non-coronary cusps are not seen. **B.** The microscopic image of the specimen obtained from the left coronary cusp, stained with hematoxylin and eosin, shows multiple papillary fronds with a central core of dense fibroelastic tissue (X100 magnification). **C** and **D.** A similar histological structure was found in the masses attached to the aortic right coronary and non-coronary cusps (X400 and X200 magnification, respectively).

phy until the tumor becomes mobile or symptomatic. In our patient, as we interpreted that both the cardiac and neurological complications had an embolic origin, he was referred for surgery. Embolic debris may originate either by the release of papillary fragments or by thrombus or platelet aggregates formed on the surface of the tumor.

Echocardiography is the best examination method, and the differential diagnosis with other cardiac masses is based on the echodensity of the central collagen matrix observed in fibroelastomas. (1) Nevertheless, as in our case, multiple lesions may not be detected by transthoracic echocardiography. Computed tomography scan and nuclear magnetic resonance imaging should provide a better characterization of soft-tissue lesions. Although coronary angiography is not advisable because of the fragile nature of the papillary fronds, it was indicated to our patient because he was admitted with a non-Q wave myocardial infarction.

Multiple papillary fibroelastomas of the aortic valve are uncommon. (4, 5) In our patient, two additional small lesions were detected beneath the leaflet surfaces upon surgical inspection. These two masses were only detected after a thorough revision of the transesophageal echocardiogram.

Surgical resection seems to be curative with an excellent prognosis, even after partial removal. Nevertheless, a thorough follow-up is necessary. Usually, these tumors can be treated by shave excision without the need for valve repair, but, occasionally, aortic leaf-

lets must be restored with a simple suture, a pericardial patch, an aortic cusp homograft, or rarely with valve replacement.

In conclusion, the association of triple papillary fibroelastoma, and brain and coronary embolism constitutes an unusual clinical presentation. In addition, as multiple lesions may be overlooked by transthoracic echocardiography, the transesophageal approach could be recommended when the presence of a papillary fibroelastoma is suspected.

**Raúl A. Borracci^{MTSAC}, Jorge Lowenstein^{MTSAC},
Gustavo Ramos, José L. Barisani^{MTSAC},
Alejandro Iotti**

Department of Cardiology, Clínica Adventista Belgrano,
Buenos Aires, Argentina

REFERENCES

1. Davoli G, Bizzari F, Tucci E, Carone E, Muzzi L, Frati G, et al. Double papillary fibroelastoma of the aortic valve. *Text Heart J* 2004;31:448-9.
2. Kumar TK, Kuehl K, Reyes C, Talwar S, Moulick A, Jonas RA. Multiple papillary fibroelastomas of the heart. *Ann ThoracSurg* 2009;88:e66-7. <http://doi.org/fdjff8>
3. Jha NK, Khouri M, Murphy DM, Salustri A, Khan JA, Saleh MA, et al. Papillary fibroelastoma of the aortic valve a case report and literature review. *J CardiothoracSurg* 2010;5:84-8. <http://doi.org/b7tkw3>
4. Hattori R, Oishi C, Iwasaka J, Iwasaka T, Okada T, Johno H, et al. Multiple papillary fibroelastoma with quadricuspid aortic valve. *J ThoracCardiovascSurg* 2009;137:1280-2. <http://doi.org/b8bz6m>
5. Matsumoto N, Sato Y, Kusama J, Matsuo S, Kinukawa N, Kuni-masa T, et al. Multiple papillary fibroelastomas of the aortic valve: case report. *Int J Cardiol* 2007;122:e1-3. <http://doi.org/bz5fh4>

Rev Argent Cardiol 2014;82:225-226 - <http://dx.doi.org/10.7775/rac.v82.i3.3347>

Thoracoabdominal Aortic Aneurysm: Endovascular Approach in a Patient with High Clinical and Surgical Risk

The incidence of thoracoabdominal aortic aneurysm represents 10.4% of cases per 100,000 inhabitants per year in the United States. Mean age at presentation is between 59 and 69 years and is more common in men. (1) Most deaths occur due to aneurysm rupture when the sac diameter measures more than 5 cm. For those measuring more than 8 cm, the probability of rupture is almost 80% one year after the diagnosis. (2) The morbidity and mortality rate associated with surgical repair is still high, ranging between 4% and 21%. This variability is related to the heterogeneity of the population and the skill of the surgical team and its setting. (1, 2)

This case report corresponds to a 63 year-old male patient, former smoker, with history of hypertension, dyslipidemia, ischemic cardiomyopathy (ejection fraction of 19%) and NYHA class II-III congestive heart failure. He had undergone an aorto-aortic bypass graft surgery due to abdominal aortic aneurysm and

a percutaneous coronary intervention of the proximal circumflex coronary artery in 2011.

A 64-row multidetector computed tomography angiography with 3D reconstruction and angiography revealed: 1) a type IV thoracoabdominal aneurysm with diameter > 78 mm from which the renal arteries, the celiac trunk and the superior mesenteric artery emerged, 2) the occlusion of the common iliac artery recanalized through the epigastric artery and pelvic collaterals to the external iliac artery (Figure 1). Before the intervention, the patient presented intermittent claudication at 300 meters.

In view of the high operative risk due to the presence of several clinical and cardiological comorbidities, the medical team decided to treat the patient with an endovascular approach.

The patient was informed about the risk of medullary neurologic complications, which were particularly high due to the previous aorto-aortic replacement. A catheter for cerebrospinal fluid drainage was placed to measure cerebrospinal fluid pressure during the procedure.

The procedure was performed under general anesthesia in a hybrid operating room. A custom made multibranched aortic stent graft (Cook®, Bloomington, Ind, USA) for visceral and renal vessels was implanted (Figure 2).

A double approach was used via the left femoral artery and the left subclavian artery. The main body of the stent graft and its iliac prolongation was advanced via the left femoral artery. The left renal artery was canalized and sealed via the left subclavian artery using covered stents (Fluency®, Bard and Zilver® measuring 6 × 60 mm, Cook); then, the right renal artery underwent the same procedure (Fluency® and Zilver® measuring 7 × 60 mm).

A severe stenosis was detected at the moment of performing the preoperative tests. At the moment of the intervention (and considering that the manufacturing of a custom made stent graft takes several months), the vessel was occluded. Thus, after ensuring the presence of sufficient collateral circulation through the pancreaticoduodenal arteries, the surgical team decided not to repair the celiac trunk. Then, the superior mesenteric artery was canalized from the branch of the stent graft corresponding to the celiac trunk, and two stents (Fluency® and Zilver® measuring 9 × 60 mm) were placed there, without complications.

Finally, the remaining branch of the stent graft body (originally created for the superior mesenteric artery) was occluded with a Fluency® stent and with Nester Cook® coils to prevent further leaks.

Originally, implantation of a femoro-femoral bypass graft was planned for the ischemic right inferior limb, but as the intraoperative angiography showed important collateral circulation, an expectant management was decided. During the postoperative period, the patient did not present signs of ischemia. He

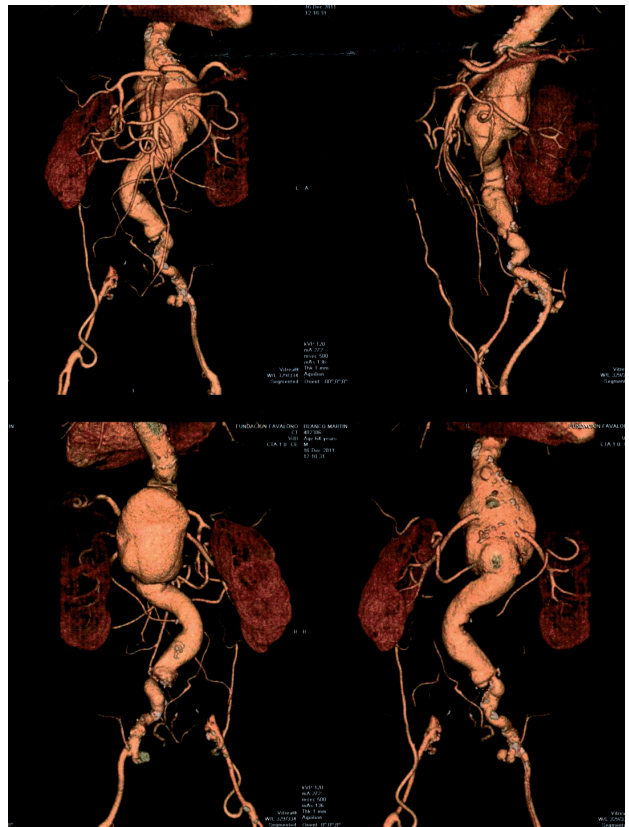

Fig. 1. 64-row multidetector computed tomography angiography with 3D reconstruction before the intervention.

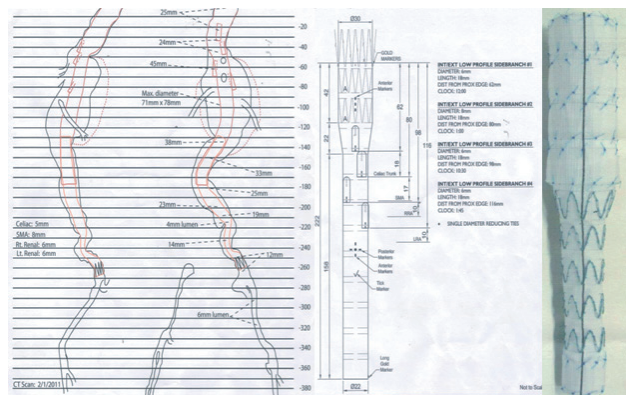


Fig. 2. Custom-made multibranched aortic stent graft

has currently no claudication changes and no evidence of trophic lesions.

The procedure was well tolerated and there were no technical complications. Creatinine levels presented a transient elevation, but were normal at discharge. The patient was discharged after 5 days with favorable outcome. Angiography and computed tomography scans were performed immediately after the procedure and after 6 months, evidencing patent visceral branches with no evidence of endoleaks (Figure 3).

Endovascular treatment of the thoracoabdominal

aorta using a branched stent graft is feasible in a complex patient. (3)

This approach is less aggressive, does not need large incisions or visceral clamp, and has lower morbidity and mortality at 24 months (lower rate of aneurysm rupture, endoleaks of the visceral vessels or need of conversion to conventional surgery) (3) The need for blood products is lower and has shorter hospital stay. In addition, the patient returns to work earlier compared to open surgery. (4, 5)

Due to the high incidence of complications related to open surgery, the most adequate patient for endovascular repair is that with thoracoabdominal aortic aneurysm, independently of the presence of comorbidities. (6, 7)

This type of procedure is not currently performed in all centers, but only in high-volume institutions with large experience in conventional and endovascular treatment of aortic diseases. One of the limiting factors is the manufacture of the stent grafts, which are custom-made devices for each patient (Figure 2). This implies a thorough process that requires exact measurement of the aneurysm anatomy, selection of the adequate device for each particular case, access to an adequate facility (a hybrid operation room) to perform the procedure and the coordination of the different actors participating in it.

There are currently a few clinical trials demonstrating that endovascular treatment of patients with thoracoabdominal aneurysms constitutes a safe, effective and feasible procedure in most cases. If the technique proves to be durable, it will be important in the treatment of thoracoabdominal aortic aneurysms, particularly in patients with high operative risk for open surgery. (7, 8).

Vadim Kotowicz¹, Diego J. Koladynski¹,
Marcelo Halac¹, José M. Rabellino²,
Oscar Peralta², Roberto R. Battellini¹

Hospital Italiano de Buenos Aires
¹Adult Cardiovascular Surgery Unit
²Diagnostic Imaging Unit

REFERENCES

1. Scott RA, Wilson NM, Ashton HA. Influence of screening on incidence of ruptured abdominal aortic aneurysms: 5-year results of a randomized controlled study. *Br J Surg* 1995;82:1066-70. <http://doi.org/bz5fh40>
2. Schermerhorn ML, Cronenwett JL. The UK small aneurysm trial. *J VascSurg* 2001;33:443. <http://doi.org/b95h32>
3. Kitagawa A, Greenberg RK, Eagleton MJ, Mastracci TM. Zenith p-branch standard fenestrated endovascular graft for juxtarenal abdominal aortic aneurysms. *J VascSurg* 2013;58:291-300. 10.1016/j.jvs.2012.12.087
4. Sicard GA, Zwolak RM, Sidawy AN, White RA, Siami FS; Society for Vascular Surgery Outcomes Committee. Endovascular abdominal aortic aneurysm repair: Long-term outcome measurement in high-risk for open surgery. *J VascSurg* 2006;44:229-36. <http://doi.org/bmj3p>
5. Parodi JC, Palmaz JC, Barone HD. Transfemoral intraluminal graft implantation for abdominal aortic aneurysms. *Ann VascSurg* 1991;5:491-9. <http://doi.org/b99fts>

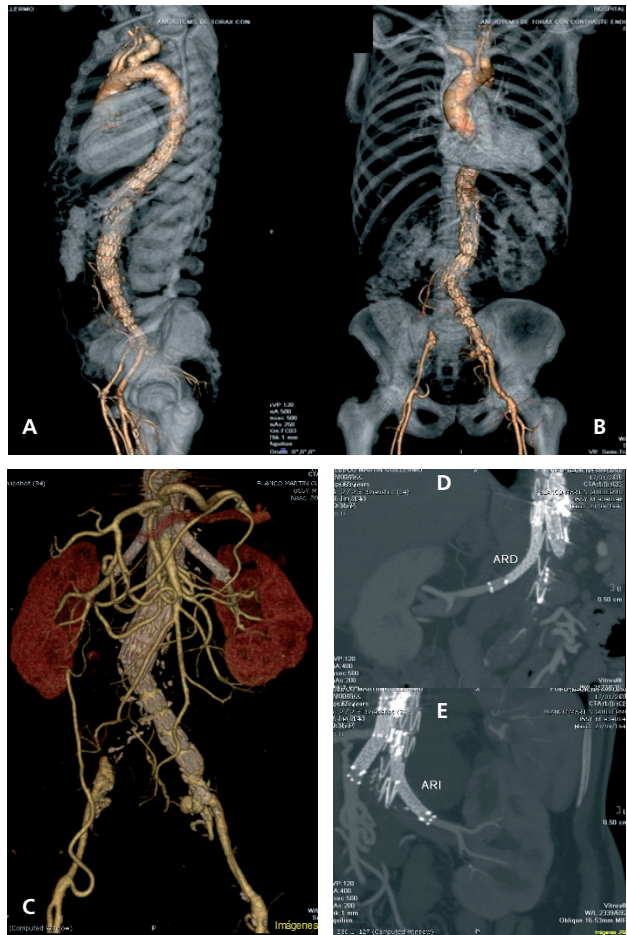


Fig. 3. Computed tomography scan performed in the immediate postoperative period (A and B) and after 6 months (C, D and E).

6. Carpenter JP, Baum RA, Barker CF, Golden MA, Mitchell ME, Velazquez OC, et al. Impact of exclusion criteria on patient selection for endovascular abdominal aortic aneurysm repair. *J VascSurg* 2001;34:1050-4. <http://doi.org/dqnv66>
7. Lezzi R, Cotroneo AR. Endovascular repair of abdominal aortic aneurysms: CTA evaluation of contraindications. *Abdom Imaging* 2006;31:722-31. <http://doi.org/bw22dh>
8. Davidović L, Jevtić M, Radak D, Sagić D, Marjanović I, Koncar I, et al. Endovascular treatment of thoracic aortic diseases. *Vojnosanit Pregl* 2013;70:32-7. <http://doi.org/rd8>

Rev Argent Cardiol 2014;82:226-228 - <http://dx.doi.org/10.7775/rac.v82.i3.2799>

Bronchiolitis Obliterans Organizing Pneumonia after Coronary Artery Bypass Graft Surgery

Pulmonary edema, atelectasis, and pneumonia are frequent causes of respiratory dysfunction after cardiac surgery. (1) We report the case of a patient who developed hypoxemia and pulmonary infiltrates as a result of bronchiolitis obliterans organizing pneumonia (BOOP) after coronary artery bypass graft surgery (CABGS). A 73-year old male patient underwent

CABGS due to severe stenosis of the left main coronary artery. The patient's medical history included type 2 diabetes, dyslipidemia, hypertension, obesity, current smoking, severe chronic obstructive pulmonary disease, obstructive sleep apnea syndrome with indication of bi-level positive airway pressure (BiPAP) and chronic atrial fibrillation. Cardiopulmonary bypass time was 56 min and aortic cross-clamp time was 27 min. During the postoperative period, the patient developed dyspnea, hypoxemia and diffuse, mixed interstitial parenchymal infiltrates, requiring BiPAP (Figure 1 A). After samples for blood culture and specimens for respiratory culture to detect common and uncommon pathogens were obtained, empirical antibiotic therapy was started, without a favorable response. The computed tomography scan (Figure 1 B) showed presence of a ground-glass opacity from apex to base, interlobular septal thickening with centrilobular images, peribronchial thickness, consolidation with air bronchogram and moderate bilateral pleural effusion with septations.

Bronchiolitis obliterans organizing pneumonia was suspected and empirical treatment with dexamethasone 1 g b.i.d was started. Bacterial cultures were negative and the clinical outcome after 1 week of corticosteroid therapy was favorable, with significant resolution of the radiological and tomographic images (Figure 2 A and B).

Bronchiolitis obliterans-organizing pneumonia was described in 1985 (2) as a particular entity with clinical and radiological characteristics that were similar to those of this patient. The histological characteristics include granulation tissue in the terminal bronchioles and alveolar ducts, extending distally into the alveoli. The tomographic pattern of BOOP is distinctive, with areas of airspace consolidation, ground-glass or "band-like" opacities, nodular infiltrates, interlobular septal thickening and signs of pulmonary fibrosis. (3) The final diagnosis is made by lung biopsy or transbronchial biopsy by bronchoscopy. (4) In general, the response to corticosteroid therapy (dexamethasone or prednisone) is excellent, and 65% to 80% of cases can be cured. (5) The clinical manifestations improve within the first 48 hours and the pulmonary infiltrates usually disappear in a few weeks. Most cases of BOOP are idiopathic, but the list of entities capable of producing secondary BOOP has been increasing in the last years, and includes infections (adenovirus, CMV, Legionella, fungi), medications (amiodarone, gold salts, bleomycin), connective tissue diseases (systemic lupus erythematosus, rheumatoid arthritis, polymyositis), organ transplantation, inhalation injury, immunologic diseases (HIV), radiotherapy, neoplasms and cirrhosis. (6)

There are few reports of BOOP associated with CABGS. The diagnosis should be considered in the absence of other causes of fever, hypoxemia and pulmonary infiltrates in the setting of cardiovascular surgery.

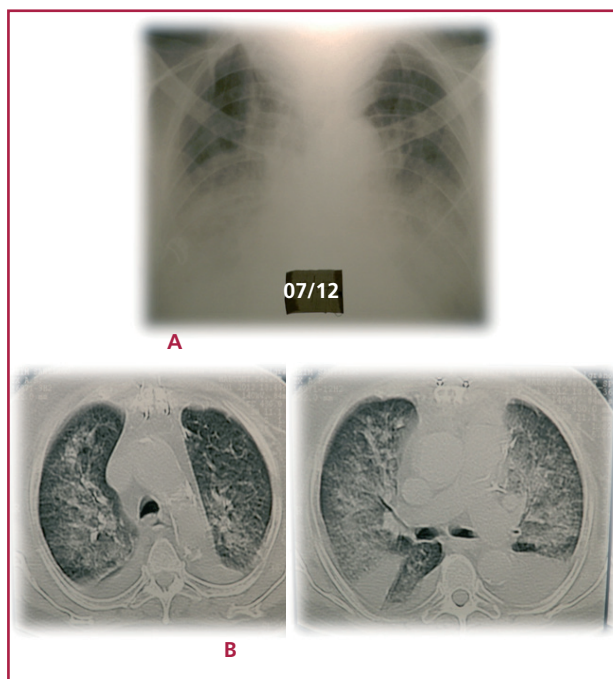


Fig. 1. A. Chest x-ray with BOOP. **B.** Computed tomography scan with BOOP

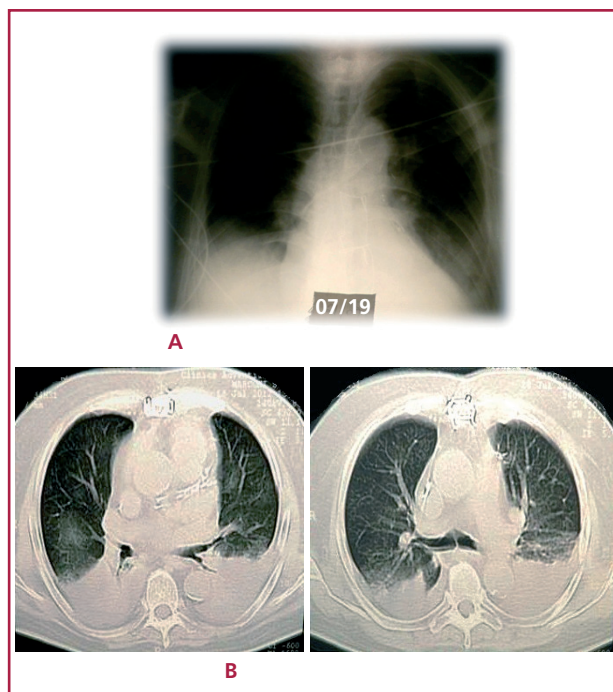


Fig. 2. A. Chest x-ray 1 week after corticosteroid therapy. **B.** Computed tomography scan one week after corticosteroid therapy.

Luis Mantilla, Gustavo Ramos, Juan C. Camino,
Juan Álvarez Sevillano, José L. Barisani^{IMTSAC},
Raúl A. Borracci^{IMTSAC}

Instituto del Corazón, Clínica Adventista Belgrano, Buenos Aires

REFERENCES

1. Guzman E, Smith A, Tietjen P. Bronchiolitis obliterans-organizing pneumonia after coronary artery bypass graft surgery. *J Thorac Cardiovasc Surg* 2000;119:382-3. <http://doi.org/cdxscm>
2. Epler GR, Colby TV, McLoud TC, Carrington CB, Gaensler EA. Bronchiolitis obliterans organizing pneumonia. *N Engl J Med* 1985;312:152-8. <http://doi.org/c47hrj>
3. Robles AM, Casas JP, Pereyra MA, Sánchez C, Navarro R, López AM. Bronquiolitis obliterante con neumonía organizante. *Revista Argentina de Medicina Respiratoria* 2005;1:20-6.
4. Poletti V, Cazzato S, Minicuci N, Zompatori M, Burzi M, Schiattone ML. The diagnostic value of bronchoalveolar lavage and transbronchial lung biopsy in cryptogenic organizing pneumonia. *Eur Respir J* 1996;9:2513-6. <http://doi.org/dk6c4z>
5. Epler GR. Bronchiolitis obliterans organizing pneumonia. *Arch Intern Med* 2001;161:158-64. <http://doi.org/fnwn2k>
6. Cordier JF. Organizing pneumonia. *Thorax* 2000;55:318-28. <http://doi.org/d6ccqx>

Rev Argent Cardiol 2014;82:228-230 - <http://dx.doi.org/10.7775/rac.v82.i3.3211>

Per-lesion Interobserver Variability and Global Impact on the SYNTAX Score

The number of patients with more comorbidities and extensive complex coronary artery disease has increased in parallel with technological advances; therefore, current medical practice requires stratification tools to individualize the decision-making process. This decision is taken by an entire work group (a cardiology interdisciplinary team) with the aim of selecting the most convenient treatment to achieve the most favorable outcome.

The SYNTAX score (SS) is an angiographic scoring system applied in patients with complex coronary artery disease to assist in risk stratification and discrimination, and to help in deciding the most convenient revascularization strategy according to the clinical variables. (1, 2) Yet, the visual interpretation of the lesions by the operators may vary and not be exact. (3) Such an error affects the reproducibility of the score and, particularly, the clinical recommendation. The variability of the global score depends on the analysis of the lesion. The points of disagreement and their implications are not well known.

In 2009, 227 coronary angiographies with significant stenosis of the left main coronary artery and/or significant three-vessel disease were prospectively and consecutively included for evaluation at the Instituto Cardiovascular de Buenos Aires. The angiographies of patients with previous percutaneous coronary interventions, coronary artery bypass grafting and ST-segment elevation acute coronary syndromes were excluded. Finally, 98 coronary angiographies were analyzed. The evaluations were performed by two independent interventional cardiologists (IC) who were not aware of the clinical information of these patients or the revascularization strategy performed. Before analyzing these angiographies, the interventional car-

diologists underwent basic training from the SS website (www.syntaxscore.com).

The observers diagnosed an average of four lesions per study (IC 1: 4.19 ± 1.5 - IC 2: 4.2 ± 1.62 ; $p = ns$), resulting in an average global SS of 30 ± 12.3 points for the first observer and 31.7 ± 14 for the second.

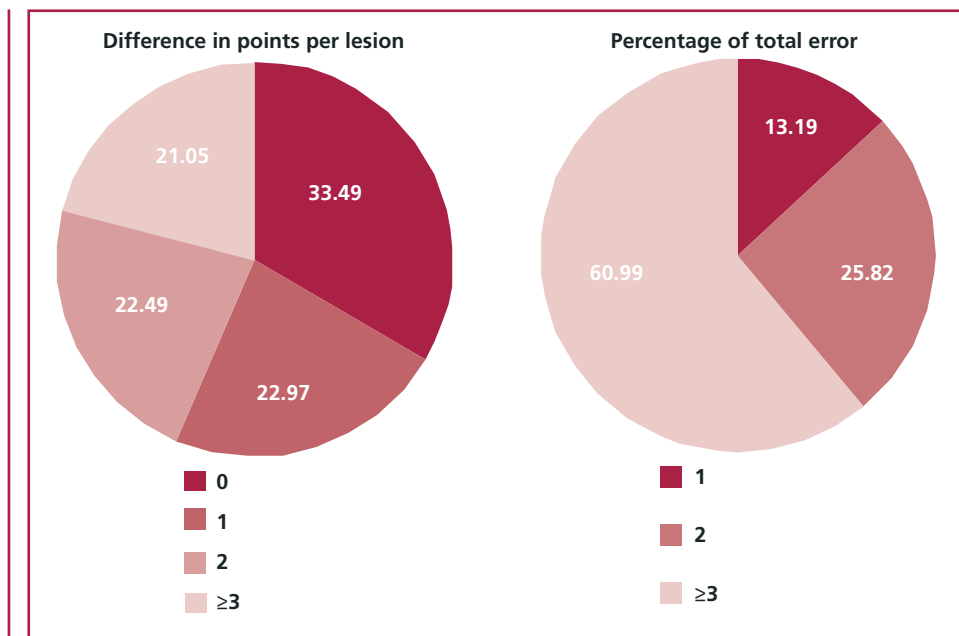
The interobserver variability of the global SS was good with kappa of 0.70 (0.59-0.81). The reproducibility of the SS has been examined in several studies, demonstrating fair to good concordance among observers. (4, 5)

In the analysis per lesion, 209 pairs of lesions were obtained from both IC. Strict measures were taken to certify the comparison of the same lesion evaluated by both IC in order to reduce the error of analysis in our study. This is extremely important, as the conclusions of previous studies were drawn according to the type of lesion investigated (bifurcations, occlusions, ostial stenosis) but not by comparing the same lesion. They also used other methods and provided the blind observers directions about which lesions to characterize. This led to biases and to limitation in segment allocation, in the severity variability and, therefore, in the conclusions. One third of the lesions evaluated did not present interobserver disagreement. Conversely, a difference of 3 points or greater in the SS per lesion was observed in more than 20%. Of importance, the latter disagreements constituted 61% of the total error (Figure 1). Both IC made a good allocation of bifurcation lesions (kappa 0.83) and of its different types (kappa 0.71). There was also good agreement in the diagnosis of chronic occlusions (kappa 0.94), aorto-ostial lesions (kappa 0.85), segment length (kappa 0.61) and presence of thrombotic material (kappa 1). However, the variability was high in the allocation of severe calcifications, significant tortuosity of the vessel and the degree of angulated occlusions between the main vessel and the secondary vessel in bifurcation lesions (Table 1).

Despite agreement in segment allocation was more than 80%, the percentage of error constitutes almost one-third of the total (error in points: 116; total percentage of error: 29.6%). The variability in the assignment of severe calcification and bifurcation lesions with specific characteristics represents the majority of the discordant points (Table 1). This significant difference in points in the assignment of segments is a basic variable leading to changes in patient treatment (e. g., proximal left anterior descending coronary artery) and outcome related to the disease. (6)

Multivariate analysis revealed a significant impact on the global SS in the segment allocation group (OR 2.05; 1.48-2.83; $p = 0.001$) and in the bifurcation group (OR 10.51; 2.18-50.63; $p = 0.003$). Bifurcation lesions correspond to a significant percentage of lesions in patients with multi-vessel disease. In addition, the requirement of percutaneous or surgical treatment is still a challenge and is associated with greater risk. Thus, the correct diagnosis of bifurcation lesions and their characteristics has particular interest. The

Fig. 1. Errors per lesion.



ability to distinguish this type of lesions was moderate in previous studies using the SS. However, in our study, multivariate analysis shows that the main SS disagreement is related to the allocation of bifurcation lesions. There is agreement in a significant percentage of allocations; yet, the error in points is clearly important with bifurcation lesions, as it has an impact on the total and leads to changes in the choice of treatment and prognosis.

This analysis has some limitations. The study was performed with a limited number of angiographies and with only two observers. These factors may be the main variables limiting the generalization of repro-

ducibility. The experience of the operators and their specialization as interventional cardiologists may affect the result. These IC had sufficient experience and were familiar with the definitions. Different types of observers could vary the results. The statistical method with kappa value is an accepted tool to evaluate interobserver reproducibility; however, the chance of agreement is a variable that is affected by the prevalence of the event studied.

The interobserver correlation per lesion was acceptable except for severe calcifications, without generating a significant error in the SS. Despite very good interobserver correlation, segment and bifurcation al-

Table 1. Variability and impact per lesion on the SYNTAX score.

| Characteristics | Variability | | Error (points) | Total error (%) | Variability Multivariate: OR (95% CI) |
|--------------------------------------|---------------|------------------|----------------|-----------------|--|
| | Agreement (%) | Kappa (SD) | | | |
| Segment allocation | 81.50% | - | 116 | 29.66 | 2.05 (1.48-2.83; p = 0.001) |
| Calcification | 73.20% | 0.39 (0.26-0.52) | 112 | 28.64 | 1.52 (0.61-3.80; p = 0.362) |
| Bifurcation | 92.00% | 0.83 (0.75-0.91) | 17 | 4.34 | 10.51 (2.18-50.63; p = |
| - Medina classification | 85.70% | 0.71 (0.53-0.88) | 18 | 4.60 | 0.003) |
| - Angulated | 73.00% | 0.45 (0.23-0.67) | 28 | 7.16 | 0.64 (0.14-2.84; p = 0.565) |
| CTO | 98.60% | 0.94 (0.87-1.00) | 20 | 5.11 | 0.98 (0.26-3.72; p = 0.981) |
| - Blunt stump / bridging collaterals | 92.9% / 62.7% | - | 16 | 4.09 | - |
| Aorto-ostial | 97.60% | 0.85 (0.71-0.99) | 5 | 1.27 | 4.11 (0.49-34.00; p = 0.188) |
| Length (> 20 mm) | 88.00% | 0.61 (0.47-0.74) | 25 | 6.39 | 1.85 (0.59-5.79; p = 0.285) |
| Tortuosity | 94.30% | 0.42 (0.15-0.69) | 24 | 6.13 | 3.32 (0.80-13.69; p = 0.095) |
| Thrombus | 100.00% | 1.00 (1.00-1.00) | 0 | 0 | - |
| Total | | | 391 | 100% | |

CTO: Chronic total occlusions. SD: Standard deviation. OR: Odds ratio.

location showed discrepancy, generating a significant error in the SS. Future image integration and global interpretation of complex lesions may help reduce the SS variability.

**Gerardo Nau^{MTSAC}, Pablo Lamelas,
Alfonsina Candiello, Lucio Padilla,
Fernando Cura^{MTSAC}**
Instituto Cardiovascular de Buenos Aires

REFERENCES

1. Valgimigli M, Serruys PW, Tsuchida K, Vaina S, Morel MA, van den Brand MJ, et al. Cyphering the complexity of coronary artery disease using the syntax score to predict clinical outcomes in patients with three vessel lumen obstruction undergoing coronary intervention. *Am J Cardiol* 2007;99:1072-81. <http://doi.org/cf2rjh>
2. Palmerini T, Genereux P, Caixeta A, Cristea E, Lansky A, Mehran R, et al. Prognostic value of the syntax score in patients with acute coronary syndromes undergoing percutaneous coronary interventions: analysis from the acuity trial. *J Am CollCardiol* 2011;57:2389-97. <http://doi.org/bv6q4t>
3. Garg S, Girasis C, Sarno G, Goedhart D, Morel MA, Garcia-Garcia HM, et al. The syntax score revisited: A reassessment of the syntax score reproducibility. *Catheter CardiovascInterv* 2010;75:946-52.
4. Génereux P, Palmerini T, Caixeta A, Cristea E, Mehran R, Sanchez R, et al. Syntax score reproducibility and variability between interventional cardiologists, core laboratory technicians, and quantitative coronary measurements. *CircCardiovascInterv* 2011;4:553-61. <http://doi.org/dmd67m>
5. Lamelas PM, Nau G, Costabel JP, Thierer J, Belardi J, Alves de Lima A. Evaluación del puntaje SYNTAX porresidentes decardiologíaclínica. *Rev Argent Cardiol* 2012;80:299-303.
6. Beauman GL, Vogel RA. Accuracy of individual and panel visual interpretations of coronary arteriograms: Implications for clinical decisions. *J Am CollCardiol* 1990;16:108-13. <http://doi.org/bgxvkz>

Rev Argent Cardiol 2014;82:230-232 - <http://dx.doi.org/10.7775/rac.v82.i3.2828>
