

What is Primary Angioplasty in Myocardial Infarction?

Angioplastia primaria en el infarto de miocardio: ¿qué es?

Acute myocardial infarction occurs when one of the arteries that supplies blood to the heart (coronary arteries) develops sudden blockage due to a blood clot.

HOW IS THE CLINICAL DIAGNOSIS MADE?

Intense and prolonged chest pain (lasting more than 30 minutes) is the most common symptom.

The situation is serious but **can be treated**. Long-term and short-term prognosis depends on **early** initiation of treatment. Therefore, the first message to transmit is that patients should seek **medical care without delay in hospitals** with the necessary capabilities to perform the diagnosis and indicate **therapy**.

HOW IS THE ANGIOGRAPHIC DIAGNOSIS MADE?

First, a coronary angiography must be performed to identify the infarct-related artery. This is done using X-ray equipment especially designed for monitoring and digitally recording images. Under local anesthesia, a catheter (a hollow plastic tube) is inserted in the groin or wrist and contrast material is injected into the coronary arteries to obtain the necessary information.

HOW IS THE BLOCKAGE TREATED?

The next step is treatment. This covers various aspects, but the priority is to open the artery. Coronary angioplasty is the fastest way to do it.

From a catheter placed at the origin of the artery (guiding catheter), a coronary guidewire 0.3 mm in diameter is advanced through the occluded area.

Initially, the clot has a soft jellylike consistency which makes the procedure easy. The balloon catheter is advanced through this guidewire.

This device has a balloon in the distal tip, which is inflated using high pressure and literally “smashes” the fatty plaque and the blood clot against the artery wall, eliminating the obstruction.

The coronary arteries are elastic structures which, after the initial stretching produced by the balloon catheter, can retract and significantly reduce the arterial lumen.

This can be avoided by placing a rigid metallic framework within the artery, called a stent (Figure 1), made of stainless steel or cobalt-chrome alloys. The stent is introduced into the artery mounted over a balloon catheter that has a diameter similar to that of the artery and sufficient length to cover the entire area of the blockage.

On occasions, and depending on the patient’s clinical characteristics and/or the type or site of the obstruction to be treated, stents that locally release medication (drug-eluting stents) are used to reduce the possibility of exaggerated scarring (restenosis).

The procedure may last between 30 minutes to several hours, depending on the patient’s status and the complexity of the blockages to treat.

WHO CAN UNDERGO THE PROCEDURE?

1. All patients with infarction within 12 hours after symptom onset.
2. All patients where drugs to break up or dissolve blood clots (thrombolytic drugs) cannot be used because of the risk involved.
3. All patients with infarction showing signs of severe impairment of heart function (heart failure).
4. All patients with infarction and suspected unsuccessful treatment with thrombolytic agents.
5. There is sufficient evidence showing that angioplasty can improve the outcome in patients with infarction between 12 and 24 hours after symptom onset.

CONCLUSIONS

The successful results of myocardial infarction treatment are associated with early therapy; thus, it is essential that the patient seeks hospital medical care immediately.

Once the diagnosis has been confirmed and the procedure has been decided, angioplasty is performed in well-trained centers with the necessary capabilities to solve the potential complications that may arise. The faster a blocked coronary artery is opened, the smaller the infarct size and the better the patient outcome.

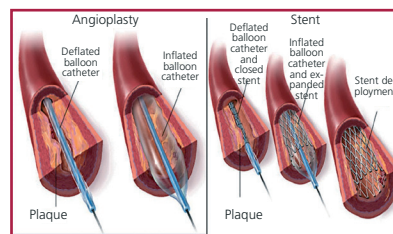
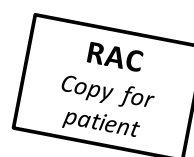

Fig. 1. Balloon angioplasty and stent implant.



Author: Dr. Jorge Blüguermann^{MTSAC}
Nueva Clínica Cruz Azul - Mercedes
Pcia. de Bs. As.

Editor: Julio Manuel Lewkowicz, MD^{MTSAC}
Sanatorio Güemes, Buenos Aires

INFORMATION YOU MAY FIND IN THE WEB

- Tajer CD, Charask A. Infarto agudo de miocardio: ¿Cuándo sospecharlo y qué hacer? *Rev Argent Cardiol* 2013; 81:294.
- Sociedad Argentina de Cardiología. Consenso de Síndromes Coronarios Agudos. *Rev Argent Cardiol* 2005;73(Supl 3):45-62.
- Álvarez JA, Migliaro G, Leiva G, Allin JG, Baglioni P, Fernández Recalde ML y cols. Angioplastia primaria en el infarto agudo de miocardio: predictores de eventos en el seguimiento a largo plazo. *Rev Argent Cardiol* 2014;82:359-365.
- Vídeo angioplastia <http://www.youtube.com/watch?v=cHZSnMlZKQE>
- Vídeo Vidant Health <http://www.youtube.com/watch?v=DF7kPAZv36U>

The information provided is aimed to be educational and does not intend to substitute the evaluation, advice, diagnosis, or treatment recommended by your doctor. This page cannot be photocopied for commercial purposes, unless authorized by the Argentine Society of Cardiology.