

# Long-term Results with Reconstructive Surgery of the Bicuspid Aortic Valve

## *Válvula aórtica bicúspide: resultados a largo plazo de la cirugía reparadora*

CARLOS PORRAS<sup>1,2</sup>, DIERK HEIMANN<sup>3</sup>, DIANA AICHER<sup>3</sup>, MIGUEL SUCH<sup>1,2</sup>, JUAN ROBLEDO-CARMONA<sup>1</sup>, JAVIER CARRERO<sup>3</sup>, JOSÉ MARÍA ARQUE<sup>2</sup>, HANS-JOACHIM SCHÄFFERS<sup>2,3</sup>

### ABSTRACT

**Introduction:** Bicuspid aortic valve is the most common congenital heart disease. Traditionally, aortic valve replacement has been the approach for patients requiring surgery. After introduction of the bicuspid aortic valve repair concept, our group began reproducing these techniques, which have been standardized and homogeneously applied at our institutions.

**Objectives:** The aim of this study was to review the joint experience of three centers and show the mid- and long-term results of bicuspid aortic valve repair.

**Methods:** Between October 1995 and February 2013, 666 patients with bicuspid aortic valve underwent surgery for aortic regurgitation and/or aortic aneurysm. Isolated aortic regurgitation was present in 254 patients, and 412 had aortic aneurysm or dissection. The valve was reconstructed in all the patients (isolated valve repair in 254, “remodelling of the aortic root” in 281, remodelling of the sinotubular junction in 129 and “reimplantation” technique in 2).

**Results:** Mortality was 3/666 (0.5%): 1/254 (0.4%) after isolated valve repair and 2/410 (0.5%) after valve repair plus aortic replacement. In patients with combined procedures (coronary revascularization or mitral/tricuspid valve repair), mortality was 1/77 (1.3%).

During follow-up, 12 patients died (10-year survival: 95%). Freedom from reoperation and from aortic valve replacement at 10 and 15 years was 80% and 77%, and 86% and 83%, respectively. Freedom from reoperation at 10 years was higher with aortic root (86%) or tubular aorta (84%) replacement, compared with isolated valve repair (74%;  $p = 0.005$ ). Freedom from any valve-related complication was 80% and 77% at 10 and 15 years, respectively, and was better for valve repair including “remodelling of the aortic root” (87% and 82%) than for isolated repair (77% and 77%;  $p = 0.04$ ).

**Conclusions:** Bicuspid aortic valve repair is a safe, long-lasting procedure, with a low incidence of mid- and long-term “valve-related complications”.

**Key words:** Bicuspid Aortic Valve - Aortic Regurgitation - Aorta Aneurysm - Reconstructive Valve Surgery

### RESUMEN

**Introducción:** La válvula aórtica bicúspide es la anomalía congénita cardíaca más frecuente. En pacientes con requerimiento de cirugía, el tratamiento tradicional ha sido la sustitución valvular. La introducción del concepto de reparación de la válvula aórtica bicúspide a nuestro grupo a reproducir las técnicas de reparación, las cuales se han estandarizado y aplicado de manera homogénea en nuestras instituciones.

**Objetivos:** Revisar la experiencia conjunta de tres centros, con la presentación de los resultados a mediano y a largo plazos de la reparación valvular.

**Material y métodos:** Entre octubre de 1995 y febrero de 2013 se intervinieron 666 pacientes con válvulas bicúspides e insuficiencia aórtica y/o aneurisma de la aorta. De ellos, 254 presentaban insuficiencia aórtica aislada y 412, aneurisma o disección. Se reconstruyó la válvula en todos los pacientes (en 254 como procedimiento aislado, en 281 “remodelación de la raíz”, en 129 remodelación de la unión sinotubular y en 2 “reimplantación”).

**Resultados:** La mortalidad fue de 3/666 (0,5%): 1/254 (0,4%) tras reparación valvular aislada y 2/410 (0,5%) tras reparación más reemplazo de la aorta. En pacientes con cirugía asociada (coronaria, reparación mitral/tricúspide) fue de 1/77 (1,3%).

Durante el seguimiento murieron 12 pacientes (supervivencia a los 10 años: 95%). Las libertades de reoperación y de sustitución valvular a los 10 y 15 años fueron del 80% y 77% y del 86% y 83%, respectivamente. La libertad de reoperación a los 10 años fue superior en el reemplazo de la raíz (86%) o la aorta tubular (84%) en comparación con la reparación aislada (74%;  $p=0,005$ ). La libertad de cualquier complicación relacionada con la válvula fue del 80% y 77% a los 10 y 15 años, respectivamente, y fue mejor para reparación incluyendo “remodelación de la raíz” (87% y 82%) que para reparación aislada (77% y 77%;  $p=0,04$ ).

**Conclusiones:** La reparación de la válvula aórtica bicúspide es un procedimiento seguro y duradero, con una incidencia baja de “complicaciones relacionadas con la válvula” a mediano y a largo plazos.

**Palabras clave:** Válvula aórtica bicúspide - Insuficiencia aórtica - Aneurisma aorta - Cirugía de reparación valvular.

REV ARGENT CARDIOL 2014;82:481-486. <http://dx.doi.org/10.7775/rac.v82.i6.4362>

SEE RELATED ARTICLE: Rev Argent Cardiol 2014;82:452-453. <http://dx.doi.org/10.7775/rac.v82.i6.5549>

Received: 04/21/2014 Accepted: 09/11/2014

Address for reprints: Carlos Porras. Hospital Universitario Virgen de la Victoria. Málaga, España - e-mail: capoma@yahoo.es

<sup>1</sup> Hospital Universitario Virgen de la Victoria. Málaga, Spain.

<sup>2</sup> Xánit Hospital Internacional. Benalmádena (Málaga), Spain.

<sup>3</sup> Klinik für Thorax und Herz Gefäßchirurgie, Universitätsklinikum des Saarlandes, Homburg/Saar, Germany

## INTRODUCTION

Bicuspid aortic valve is the most common congenital heart disease, and is characterized by fusion of two of the three aortic leaflets. The patterns of fusion are variable, and the most common fusion comprises the right and left cusps. (1) This defect is four times more common in men, and about 50% of subjects with a bicuspid aortic valve develop dilation of the aortic root or the ascending aorta. (2-4) The anatomical diagnosis of bicuspid aortic valve and its function are easily performed with echocardiography, but sometimes it may be difficult to distinguish between a tricuspid aortic valve and a partially fused bicuspid valve.

Normally functioning bicuspid aortic valves can remain hemodynamically normal for over 7 decades, (2-5); yet, many patients will need surgery in the course of their lives, mostly due to aortic stenosis. Only 20% to 25% of patients will require surgery for aortic regurgitation, generally between the third and fourth decades of life, and surgery may also be necessary if the size of the aorta exceeds a certain limit.

Aortic valve replacement has been the traditional treatment of aortic valve disease, but some patients require associated replacement of the aortic valve and aorta. Aortic valve replacement with a mechanical valve is associated with 1% risk of reintervention per year, which is similar to valve-related mortality. (6) The combined incidence of thromboembolic and bleeding complications ranges between 2.5% and 3.5% per year. (6) Degeneration of biological prostheses depends on the patients' age, and although they may be a very good option in elderly patients, they result suboptimal under the age of 50.

The concept of aortic valve repair of insufficient bicuspid aortic valve was introduced in 1992. (7) Our group has been able to reproduce these techniques. (8) We have also developed the concept of bicuspid aortic valve preservation or repair in the presence of aortic root or ascending aorta aneurysm. (9) In addition, we have described that the correction of cusp prolapse could be improved by measuring the effective height as an objective parameter of valve configuration. (10) Increased experience has improved the selection of patients who are candidates for aortic valve repair based on predictors of early failure. (11, 12) Although there are several publications about aortic valve repair, most of the published series are short and with limited follow-up. (12-19)

Repair techniques have been standardized and homogeneously applied at our institutions. The aim of this analysis was to review our joint experience and show mid and long-term results. We present the immediate outcomes (complications and in-hospital mortality) and the outcomes during follow-up (complications, late mortality, freedom from reoperation and freedom from valve-related complications). (20)

## METHODS

### Type of study

We conducted a longitudinal, descriptive and prospective study.

### Study population

Between October 1995 and February 2013, 666 patients were operated on in three centers (SUH, HUVV, HXI) for aneurysm of the aortic root with bicuspid aortic valve and aortic regurgitation and/or aneurysm of the aorta. The population consisted of 579 men (87%) and 87 women (13%) with mean age of  $47 \pm 14$  years (3 - 86 years). Aortic regurgitation was severe in 541 patients (81.2%), moderate in 83 (12.5%) and mild or minor in 42 (6.3%). The primary indication for surgery was aortic regurgitation in 491 patients (73.7%), endocarditis in 11 (1.7%) and double lesion in 11 (1.7%). Other indications were stable aortic aneurysm, (n = 141, 21.1%) and type A acute aortic dissection (n = 12, 1.8%). Isolated aortic regurgitation was present in 254 cases (38.1%) and aortic aneurysm or aortic dissection was seen in 412 (61.9%).

All patients signed an informed consent, and the Ethics Committee of the participating centers authorized the use of patient data for analysis and anonymous publication.

### Surgical technique

All patients underwent aortic valve repair. In 254 patients (38.1%) the procedure was isolated; "aortic root remodeling" was performed in 281 patients (42.2%), remodeling of the sinotubular junction in 129 (19.4%), and "reimplantation technique" in 2 (0.3%). The associated procedures included: aortic arch surgery in 69 patients (10.4%) with total replacement in 3 (0.4%), coronary artery bypass graft surgery in 45 patients (6.8%), and mitral valve repair in 28 patients (4.2%) which was associated with tricuspid valve repair in 6 (0.9%). Radiofrequency catheter ablation of the left atrium was performed in cases of atrial fibrillation (n = 23, 3.5%).

The surgical details have been previously published. (8-13, 21, 22) Standard techniques, with median sternotomy, were used in all cases. The anatomic characteristics of the valve were carefully documented. The valve was repaired in all cases with concomitant ascending aorta replacement if the aortic diameter exceeded 4.5 cm. The aortic root was also replaced when the sinus diameter exceeded 4.3 - 4.5 cm, particularly if the anatomic characteristics of the valve were unfavorable. (12)

The geometric height of the "nonfused" cusp (21) was measured and the valves were repaired if the height was 20 mm or greater. The presence of leaflet prolapse was determined using the concept of effective height, (22) measured with a specific caliper (MSS-1, Fehling Instruments, Karlstein, Germany). Prolapse of the "nonfused" cusp (when its effective height was < 9 mm) was corrected by placing central plicating sutures on the free margin of the cusp. (13) The free margins of the "nonfused" cusp were aligned and the excessive tissue was removed by central plication. In case of intense fibrosis, calcification of the raphe or extensive tissue redundancy making central plication difficult, triangular excision was chosen.

In 129 patients (19.4%) the tubular aorta was replaced by remodelling the sinotubular junction. In another 283 patients (42.5%), the aortic root was also replaced using the aortic root remodelling technique in 281 cases (99.3%).

In the last 275 cases of aortic valve repair with or without aortic root replacement (41.3%) the aortic annular base was supported by a braided polyester suture or a polytetrafluoroethylene suture tied around a 23-mm or 25-mm Hegar dilator. (23)

In 139 patients (20.9%) a pericardial patch was used to replace the valvular tissue after calcium excision or to close a perforation caused by endocarditis.

Seventy-seven patients (12%) underwent combined pro-

cedures, including coronary artery bypass grafting (n = 45; 6.8%), mitral valve repair (n = 28; 4.2%), tricuspid valve repair (n = 6; 0.9%) or aortic root replacement (n = 69; 10.4%, with total replacement in 6 cases, 0.4%). Radiofrequency catheter ablation of the left atrium (n = 23; 3.5%) was performed in cases of atrial fibrillation.

Aortic cross-clamp, cardiopulmonary bypass and circulatory arrest (when necessary) times were  $76 \pm 29$ ,  $53 \pm 22$  and  $7 \pm 6$  minutes, respectively.

### Echocardiography

Valve function was evaluated by intraoperative transeophageal echocardiography (Siemens Acuson Sequoia, Mountain View, USA and General Electric Vivid E9, Wauwatosa, USA). Transthoracic echocardiography was performed to all the patients before the intervention, before discharge and during follow-up visits. Valve function and competence were quantified following the recommendations of practice guidelines. (24) The severity of aortic regurgitation was determined based on the following criteria: grade 0 (absent or trivial), grade 1 or mild (vena contracta  $< 3$ , effective regurgitant orifice area  $< 10$ , regurgitant volume  $< 30$ ), grade 2 or "mild to moderate" (effective regurgitant orifice area 10-19, regurgitant volume 30-44), grade 3 or "moderate to severe" (effective regurgitant orifice area 20-29, regurgitant volume 45-59) and grade 4 or "severe" (vena contracta  $> 6$ , effective regurgitant orifice area  $> 30$ , regurgitant volume  $> 60$ ). (25)

### Follow-up and statistical analysis

Follow-up was performed 30 or 45 days after the intervention, at one year and once a year thereafter, with clinical interview and echocardiography. The information was introduced in an aortic valve repair and aortic aneurysm database, and is included in the international AVIATOR registry since January 2013. (26)

Quantitative variables are expressed as mean  $\pm$  standard deviation. The chi square test was used to compare categorical variables and Student's t test for continuous variables. Kaplan-Meier curves were calculated for survival, freedom from reoperation and freedom from aortic valve replacement. The log-rank test was used to evaluate intergroup differences in the Kaplan-Meier analysis. Statistical analyses were performed using SPSS 17 (SPSS Inc, Chicago, USA) and Prism (Prism, GraphPad Inc, San Diego, USA) statistical packages.

## RESULTS

Conversion to aortic valve replacement during valve repair was not necessary in any case; yet, in 35 patients (4.99%) in whom valve repair was intended (and who are not part of this study) valve replacement was performed due to unfavorable anatomic characteristics (fenestrations, retraction or calcification).

Five patients (0.7%) were reoperated due to bleeding and 2 pacemakers were implanted (0.3%).

Three patients died, resulting in 0.5% in-hospital mortality (mortality within 30 days or during hospital stay). Mortality after isolated valve repair was 1/254 (0.4%) and 2/410 (0.5%) for valve repair plus replacement of the aorta. Mortality of patients with combined procedures (aortic valve replacement associated to coronary artery bypass grafting or mitral or tricuspid repair) was 1/77 (1.3%). The causes of death were

subarachnoid hemorrhage (n = 1; 0.1%), mesenteric ischemia (n = 1; 0.1%) and ventricular fibrillation (n = 1; 0.1%).

Cumulative follow-up involved 3,323 patient-years (mean  $61 \pm 45$  months; median 57 months).

During follow-up, 12 patients (1.8%) died between 2 and 110 months after the intervention. The causes of death were sudden death (n = 4; 0.6%), sepsis (n = 2; 0.3%), endocarditis (n = 1; 0.1%), stroke (n = 1; 0.1%), suicide (n = 1; 0.1%) or unknown causes (n = 3; 0.4%). Actuarial survival at 10 years is 95%.

Among the 663 surviving patients, 73 (10.9%) required reoperation. In 5 (6.9% of reoperations) reoperation was indicated due to calcified aortic stenosis, between 9 and 12 years after the first intervention. These 5 patients belonged to a cohort of 98 followed-up for 9 years or more. In the other 68 patients (93.1% of reoperations) reoperation was due to recurrence of the aortic regurgitation, and in 5 of them as a consequence of endocarditis. Aortic valve replacement was performed in 35 reoperations (51.5%) and 33 patients (48.5%) underwent a new aortic valve repair. Four of the latter required aortic valve replacement in a second reoperation. Freedom from reoperation was 80% at 10 years and 77% at 15 years. Freedom from aortic valve replacement was 86% at 10 years and 83% at 15 years.

Freedom from reoperation at 10 years was significantly higher after replacement of the aortic root as root remodelling (86%) or replacement of the tubular aorta as remodelling of the sinotubular junction (84%), compared with isolated valve repair (74%;  $p = 0.005$ ) (Figure 1).

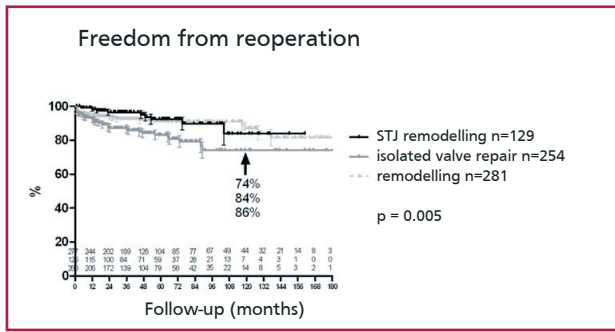
In 139 patients (20.9%) a pericardial patch was used to replace the valvular tissue. Its use was associated with reduced stability of valve repair at 5 years (77%), compared with the procedures that did not include partial replacement of any leaflet (92%;  $p < 0.001$ ) (Figure 2).

Freedom from reoperation at 10 years differed if the primary indication of surgery was aortic regurgitation (78%) or aortic aneurysm (88%;  $p = 0.02$ ). However, freedom from reoperation at 15 years was identical (78%) (Figure 3).

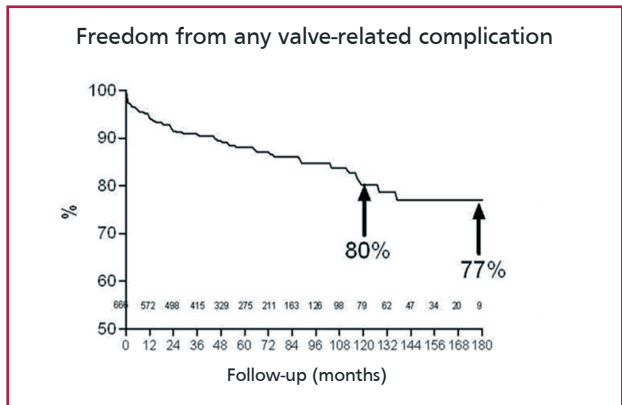
Freedom from any valve-related complication was 80% at 10 years and 77% at 15 years after surgery, and was better for valve repair, including "remodelling of the aortic root" (87% and 82%) than for isolated valve repair (77% and 77%;  $p = 0.04$ ) (Figures 4 and 5).

## DISCUSSION

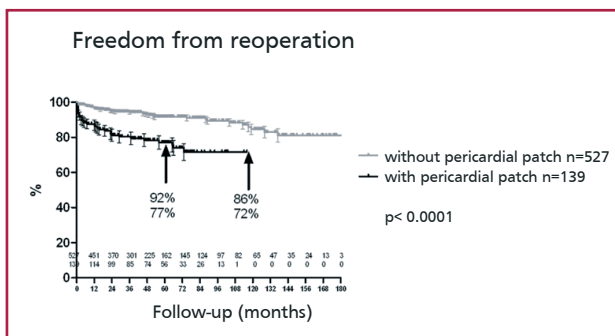
Traditionally, the morphology of bicuspid aortic valve has been considered pathological and, thus, many bicuspid valves are resected and replaced by prostheses, regardless of their functional status (in cases of surgery of aortic root aneurysm). This concept is changing as the knowledge of the natural history of bicuspid aortic valve increases. (1-5) The greater experience with valve replacement has documented evidence that the current prostheses are associated with a signifi-



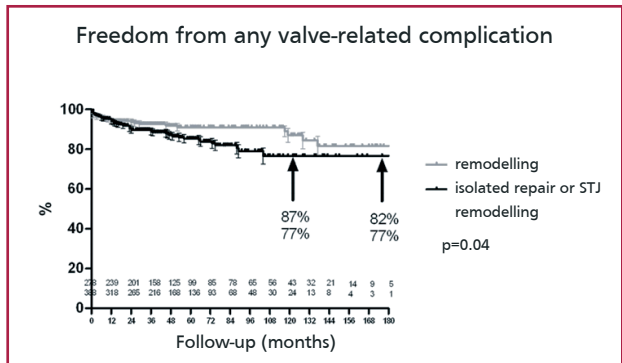
**Fig. 1.** Freedom from reoperation after the three procedures used in bicuspid aortic valve repair. STJ: Sinotubular junction. Remodelling: "Root remodelling".



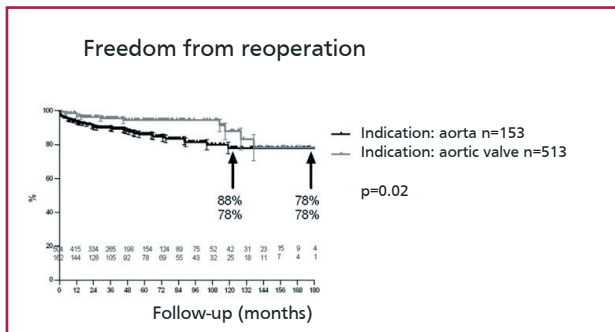
**Fig. 4.** Freedom from any "valve-related complication" after bicuspid aortic valve repair.



**Fig. 2.** Freedom from reoperation after bicuspid aortic valve repair with or without the use of a pericardial patch to replace part of a leaflet.



**Fig. 5.** Freedom from any "valve-related complication" after bicuspid aortic valve repair, including "remodelling of the aortic root", versus isolated valve repair and remodelling of the sinotubular junction (STJ).



**Fig. 3.** Freedom from reoperation after bicuspid aortic valve repair depending on whether the primary indication of surgery is valvular dysfunction or aortic disease (aneurysm or dissection).

cant probability of "valve-related complications" and are therefore not the ideal solution. (6)

Bicuspid aortic valve repair started with Cosgrove et al., (7) who estimated that the rate of complications with this technique would be lower than those of aortic valve replacement. The option of valve repair is specially attractive for young patients with aortic regurgitation that frequently develop severe symptomatic regurgitation. (27) For these young subjects, biological prostheses are not a good option due to their limited durability. Therefore, mechanical pros-

theses are implanted to these patients with the need of lifelong anticoagulation and the subsequent low, though existing risk of thromboembolic and hemorrhagic complications. (6, 28) Valve repair is even more attractive in patients with aneurysm of the aorta and mild or moderate aortic regurgitation.

Different combined series have been published showing the outcomes of bicuspid aortic valve reconstruction, though in general, they include a limited number of patients and short follow-up (12-18) (Table 1).

As a consequence of higher experience, we could identify predictors of stable repair, allowing a reproducible selection of patients and valves that may be candidates for these procedures. We have found that aortic valve repair is feasible in almost all the patients without leaflet calcification at echocardiography. (12) The current results demonstrate that a good stability of valve function can be achieved at 10 and 15 years.

Even more importantly, our results support previous findings reporting that the incidence of "valve-related complications" is significantly lower than the one described for valve replacements. (29) Although complications may appear after repair, particularly

**Table 1.** Different combined series showing bicuspid aortic valve reconstruction outcomes.

Series	Patients	Results	%
Aicher, et al (2004)	60	Freedom from AR > 2 at 5 years	96
		Freedom from reoperation at 5 years	98
Aicher, et al (2011)	316	Survival at 10 years	94
		Freedom from AR > 2 at 10 years	87
		Freedom from reoperation at 10 years	97
Alsoufi, et al (2005)	71	Survival at 8 years	97
		Freedom from AR > 2 at 8 years	44
		Freedom from reoperation at 8 years	82
Ashikhmina, et al (2010)	108	Survival at 10 years	87
		Freedom from reoperation at 10 years	64
Boodhwani, et al (2010)	122	Survival at 8 years	97
		Freedom from AR > 2 at 8 years	94
		Freedom from reoperation at 8 years	83
Casselmann, et al (1999)	94	Freedom from reoperation at 7 years	84
Forteza, et al (2013)	51	Survival at 3 years	100
		Freedom from AR > 2 at 3 years	100
		Freedom from reoperation at 3 years	100

\* Taken from references 12-18. These series generally include a limited number of patients and short follow-up. AR: Aortic regurgitation.

the recurrence of regurgitation, we may speculate that a better valve selection and a generalized use of annular support (30) will further improve the results.

It has been argued that all bicuspid aortic valves will become stenotic and will thus require aortic valve replacement. (31) In our series, we have only found late development of stenosis (between 9 and 12 years after the first surgery) in 5 of the 98 patients followed-up for 9 years or more (5.1%). In addition, stenosis occurred in patients who had calcified leaflets during the initial intervention, while most of the valves maintained good systolic function. Thus, recurrence of regurgitation has been so far a more common cause of reintervention than stenosis development.

It is still early to assure which will be the durability of valve repair with the techniques currently used. A durability of 15 years or more has been achieved using the initial technical approaches, (12) which is higher than that of a bioprosthesis in patients of similar age. Further investigations with longer follow-up periods are necessary to know the real long-term results. We expect that the repairs will last after the seventh decade of life with an adequate, systematic and individualized correction of the pathological elements of each valve.

The limitations of valve repair are basically due to the anatomic characteristics of the valve, as for example, an unfavorable commissural orientation. (12) Although leaflet retraction is rare in a bicuspid aortic valve, it is in general a problem to achieve a good repair. The presence of calcific plaque should probably be considered an exclusion criterion for valve repair. Also, the presence of large tissue defects secondary to endocarditis, or any situation requiring an extensive use of pericardial patches is also a predictor of reduced durability of valve repair. (32)

## CONCLUSIONS

We may conclude that bicuspid aortic valve repair is a safe procedure in the treatment of aortic regurgitation and aneurysms of the ascending aorta. The hemodynamic function of the reconstructed bicuspid valves is good, and the incidence of "valve-related complications" is low. We expect that with the improvement of current techniques, including annular support, future outcomes will be even better.

## Conflicts of interest

None declared.  
(See authors' conflicts of interest forms in the web / Supplementary Material).

## REFERENCES

- Nistri S, Sorbo MD, Marin M, Palisi M, Scognamiglio R, Thiene G. Aortic root dilatation in young men with normally functioning bicuspid aortic valves. *Heart* 1999;82:19-22.
- Sabet HY, Edwards WD, Tazelaar HD, Daly RC. Congenitally bicuspid aortic valves: a surgical pathology study of 542 cases (1991 through 1996) and a literature review of 2,715 additional cases. *Mayo Clin Proc* 1999;74:14-26. <http://doi.org/bbtmpw>
- Tzemos N, Therrien J, Yip J, Thanassoulis G, Tremblay S, Jamorski MT, et al. Outcomes in adults with bicuspid aortic valves. *JAMA* 2008;300:1317-25. <http://doi.org/bkxwbz>
- Carro A, Teixido-Tura G, Evangelista A. Dilatación aórtica en válvula aórtica bicúspide. *Rev Esp Cardiol* 2012;65:977-81. <http://doi.org/f2fsd6>
- Michelena HI, Desjardins VA, Avierinos JF, Russo A, Nkomo VT, Sundt TM, et al. Natural history of asymptomatic patients with normally functioning or minimally dysfunctional bicuspid aortic valve in the community. *Circulation* 2008;117:2776-84. <http://doi.org/cmrvf>
- Hammermeister K, Sethi GK, Henderson WG, Grover FL, Oprian C, Rahimtoola SH. Outcomes 15 years after valve replacement with a mechanical versus a bioprosthetic valve: final report of the Veterans Affairs randomized trial. *J Am Coll Cardiol* 2000;36:1152-8. <http://doi.org/cdzzvww>
- Cosgrove DM, III. Aortic valve repair. *Ann Thorac Surg* 1992;54:1014-5. <http://doi.org/cxmjkj>
- Schäfers HJ, Aicher D, Langer F, Lausberg HF. Preservation of the

- bicuspid aortic valve. *Ann Thorac Surg* 2007;83:S740-S745. <http://doi.org/cctpg5>
9. Schäfers HJ, Kunihara T, Fries P, Brittner B, Aicher D. Valve-preserving root replacement in bicuspid aortic valves. *J Thorac Cardiovasc Surg* 2010;140(6 Suppl):S36-S40. <http://doi.org/bk9gtw>
10. Schäfers HJ, Bierbach B, Aicher D. A new approach to the assessment of aortic cusp geometry. *J Thorac Cardiovasc Surg* 2006;132:436-8. <http://doi.org/dwqk7q>
11. Aicher D, Schäfers HJ. Aortic valve repair-current status, indications, and outcomes. *Semin Thorac Cardiovasc Surg* 2012;24:195-201. <http://doi.org/vs4>
12. Aicher D, Kunihara T, Abou 10, Brittner B, Graber S, Schafers HJ. Valve configuration determines long-term results after repair of the bicuspid aortic valve. *Circulation* 2011;123:178-85. <http://doi.org/fkt74s>
13. Aicher D, Langer F, Kissinger A, Lausberg H, Fries R, Schafers HJ. Valve-sparing aortic root replacement in bicuspid aortic valves: a reasonable option? *J Thorac Cardiovasc Surg* 2004;128:662-8. <http://doi.org/fsx3t5>
14. Alsoufi B, Borger MA, Armstrong S, Maganti M, David TE. Results of valve preservation and repair for bicuspid aortic valve insufficiency. *J Heart Valve Dis* 2005;14:752-8. <http://doi.org/fksbbs>
15. Ashikhmina E, Sundt TM III, Dearani JA, Connolly HM, Li Z, Schaff HV. Repair of the bicuspid aortic valve: a viable alternative to replacement with a bioprosthesis. *J Thorac Cardiovasc Surg* 2010;139:1395-401. <http://doi.org/fksbbs>
16. Boodhwani M, de Kerchove L, Glineur D, Rubay J, Vanoverschelde JL, Noirhomme P, et al. Repair of regurgitant bicuspid aortic valves a systematic approach. *J Thorac Cardiovasc Surg* 2010;140:276-84. <http://doi.org/c6zjns>
17. Casselman FP, Gillinov AM, Akhrass R, Kasirajan V, Blackstone EH, Cosgrove DM. Intermediate-term durability of bicuspid aortic valve repair for prolapsing leaflet. *Eur J Cardiothorac Surg* 1999;15:302-8. <http://doi.org/ffxzr6>
18. Forteza A, Vera F, Centeno J, López-Gude MJ, Pérez-de la Sota E, Sánchez V, et al. Preservación de la válvula aórtica bicúspide asociada a aneurismas de la raíz de aorta y aorta ascendente. *Rev Esp Cardiol* 2013;66:644-8. <http://doi.org/f2kc3k>
19. Méndez I, Prado B, Gallego P, Castro A, Barquero JM, Brunstein G, et al. Reparación valvular en la insuficiencia aórtica por válvula bicúspide: ¿una alternativa? *Rev Esp Cardiol* 2007;60:209-12. <http://doi.org/b9fqxd>
20. Akins C, Miller C, Turina M, Kouchoukos N, Blackstone E, Grunkemeier G, et al. Guidelines for reporting mortality and morbidity after cardiac valve interventions. *Ann Thorac Surg* 2008;85:1490-5. <http://doi.org/c8vzjg>
21. Schäfers HJ, Schmied W, Marom G, Aicher D. Cusp height in aortic valves. *J Thorac Cardiovasc Surg* 2013;146:269-74. <http://doi.org/vs6>
22. Aicher D, Langer F, Adam O, Tscholl D, Lausberg H, Schäfers HJ. Cusp repair in aortic valve reconstruction: does the technique affect stability? *J Thorac Cardiovasc Surg* 2007;134:1533-8. <http://doi.org/dkk89v>
23. Aicher D, Schneider U, Schmied W, Psych D, Kunihara T, Tochii M, et al. Early results with annular support in reconstruction of the bicuspid aortic valve. *J Thorac Cardiovasc Surg* 2012;145(3 Suppl):S30-4. <http://doi.org/vs5>
24. Evangelista A, Flachskampf FA, Erbel R, Antonini-Canterin F, Vlachopoulos C, Rocchi G, et al. Echocardiography in aortic diseases: EAE recommendations for clinical practice. *Eur J Echocardiogr* 2010;11:645-58. <http://doi.org/d8n3xk>
25. Lancellotti P, Tribouilloy C, Hagendorff A, Moura L, Popescu B, Agricola E, et al. European Association of Echocardiography recommendations for the assessment of valvular regurgitation. Part 1: aortic and pulmonary regurgitation (native valve disease). *Eur J Echocardiogr* 2010;11:223-44. <http://doi.org/dj2fsx>
26. <http://shvd.org/Working-Groups/AV-repair/>
27. Lewin MB, Otto CM. The bicuspid aortic valve: adverse outcomes from infancy to old age. *Circulation* 2005;111:832-4. <http://doi.org/bkd5mn>
28. Oxenham H, Bloomfield P, Wheatley DJ, Lee RJ, Cunningham J, Prescott RJ, et al. Twenty year comparison of a Bjork-Shiley mechanical heart valve with porcine bioprostheses. *Heart* 2003;89:715-21. <http://doi.org/bhnxkn>
29. Aicher D, Fries R, Rodionychewa S, Schmidt K, Langer F, Schäfers HJ. Aortic valve repair leads to a low incidence of valve-related complications. *Eur J Cardiothorac Surg* 2010;37:127-32. <http://doi.org/dtrnkk>
30. Aicher D, Schneider U, Schmied W, Kunihara T, Tochii M, Schäfers HJ. Early results with annular support in reconstruction of the bicuspid aortic valve. *J Thorac Cardiovasc Surg* 2013;145(3 Suppl):S30-4. <http://doi.org/vs5>
31. Friedman T, Mani A, Elefteriades JA. Bicuspid aortic valve: clinical approach and scientific review of a common clinical entity. *Expert Rev Cardiovasc Ther* 2008;6:235-48. <http://doi.org/fw7src>
32. Mayer K, Aicher D, Feldner S, Kunihara T, Schäfers HJ. Repair versus replacement of the aortic valve in active infective endocarditis. *Eur J Cardiothorac Surg* 2012;42:122-7. <http://doi.org/vs7>