Severe Accidental Hypothermia with Prolonged Cardiac Arrest: Report of a Case with Successful Treatment

Severe accidental hypothermia is a condition in which body temperature decreases below 30 ºC, exhibiting very high mortality rates. We present the case of a 63 year-old woman, in cardiac arrest, found naked among some bushes in May 2012, partly covered with mud and with a bottle of gin at her side. She had been outdoors for two days, with an average ambient temperature of 10 ºC.

An ambulance was requested which took 7 minutes to arrive. The paramedics confirmed the cardiac arrest and started CPR. After 2 hours, the patient was transferred to the hospital. On arrival, nasal temperature was 23 ºC. A LUCAS™ device was used to provide rhythmic chest compressions. The patient was deemed "recoverable", so she was immediately transferred to the cardiac operation room, where cardiopulmonary bypass (CPB) was established with a centrifugal pump using arterial and venous femoral cannulation, and gradual re-warming was immediately started. Under transesophageal echocardiography (TEE) guidance, the venous cannula was inserted to reach the right atrium. Initially, the patient had ventricular fibrillation, but as temperature rose to 28 - 30 ºC, the heart spontaneously recovered normal sinus rhythm.

To optimize brain protection, CPB was discontinued at mild hypothermia of 36.2 ºC, with MAP of 60 mm Hg, and a very high dose of noradrenaline (0.6 μg/kg/min) was indicated to maintain blood pressure within normal limits. The cardiac index obtained by transesophageal Doppler was 3.5 L/min/m2 and O2 saturation was 93 %. The arterial gas test showed very severe acidosis (pH 7.15) and lactate of 15 mmol/L. Transesophageal echocardiography images displayed a hyperdynamic heart with good biventricular function. Diuresis was normal.

To treat coagulation disorders following ROTEM tests, a unit of platelets and 8 units of cryoprecipitate were used. Also, 6 units of blood were necessary to correct hemoglobin levels.

After decannulation, the persistent high lactate levels and an apparent abdominal distension indicated the possibility of mesenteric ischemia. General surgeons performed an emergency minilaparotomy, but no abnormalities were found.

The patient was transferred to ICU. She was extubated the next day and started treatment with continuous positive airway pressure. She was awake and alert, but unaware of the events before the cardiac arrest. Family interrogation revealed a past medical history of depression and anxiety disorders. Creatine kinase levels reached 30,000 IU/L, which was interpreted as rhabdomyolysis and treated with fluid infusion. Renal function was normal. The patient was transferred to the intermediate care unit and was discharged from the hospital on the 9th postoperative day without neurological deficit.

Fig. 1. LUCAS™ Chest Compression System

Severe accidental hypothermia has a high mortality rate, reaching 80 %. The most common cause is exposure to cold water or air. Essentially, a hypothermic body on cardiac arrest cannot be considered dead until "rewarmed and dead". Based on this principle, it may be advisable to initiate CPR when finding a body under this condition, and continue till the body temperature reaches 33 to 35 ºC. There have been several reports of intact neurological recovery after prolonged cold water immersion if asphyxia does not precede cardiac arrest. It is well known that there is lack of immediate perfusion and surgical team availability in a general hospital at the time of arrival of this kind of patients, and this is the main reason why CPR is usually discontinued before full rewarming. There have been some reports on negative prognostic factors of successful recovery on hospital arrival, like pH < 6.5, K levels > 9 mmol/L, and ACT > 400 seconds. In these cases, death may have preceded hypothermia. None of these factors was present in the case we have reported here.

In conclusion, CPB has been established as a very useful treatment for patients with severe accidental hypothermia and circulatory arrest.

The LUCAS™ Chest Compression System is designed to help improve the outcome of patients undergoing sudden cardiac arrest. The system performs at least 100 compressions per minute with a 2-inch (5 cm) depth, and can be applied quickly with minimal interruption of patient care.

Gustavo Knop
Consultant Cardiac Surgeon.
The Sussex Cardiac Centre, Royal Sussex County Hospital,
Eastern Road, Brighton, UK, BN2 5BE
Gustavo.Knop@bsuh.nhs.uk - drknop@hotmail.com

REFERENCES

1. Singh T, Hallows KR. Hemodialysis for the treatment of severe accidental hypothermia. Semin Dial 2014;27:295-7. http://doi.org/xvv

2. Sawamoto K, Tanno K, Takeyama Y, Asai Y. Successful treatment of severe accidental hypothermia with cardiac arrest for a long time using cardiopulmonary bypass report of a case. Int J Emerg Med 2012;5:9. http://doi.org/xvw

3. Avellanas ML, Ricart A, Botella J, Mengelle F, Soteras I, Veres T, et al. Management of severe accidental hypothermia. Medicina Intensiva 2012;36:200-12. http://doi.org/f2ffq7

4. Walpoth BH, Walpoth-Aslan BN, Mattle HP, et al. Outcome of survivors of accidental deep hypothermia and circulatory arrest treated with extracorporeal blood warming. N Engl J Med 1997;337:1500-5. http://doi.org/cr4x4h

5. Larach MG. Accidental hypothermia. Lancet 1995;345:493-8. http://doi.org/bphbzr

6. Locher T, Walpoth B, Pfluger D, Althaus U. Akzidentelle Hypothermie in der Schweiz (1980-1987) Kasuistik und prognostische Faktoren. Schweiz Med Wochenschr 1991;121:1020-8

Rev Argent Cardiol 2015;83:55-56 - http://dx.doi.org/10.7775/rac.v83.i1.4237

Double Valve Replacement Associated with Mitral-Aortic Intervalvular Fibrosa Reconstruction in Patients with Prosthetic Valve Endocarditis

The mitral and the aortic valves are connected by a fibrous structure extending from the medial to the lateral fibrous trigone. This structure, the mitral-aortic intervalvular fibrosa (MAIVF), is involved in the anatomic and functional integrity of the two valves, and can be injured due to infective endocarditis, degenerative calcification or previous valve surgery. The need for double valve replacement in any of these situations poses an interesting surgical challenge. Below is a description of our initial experience with double valve replacement associated with MAIVF reconstruction.

Between May 2009 and December 2013, four patients underwent double valve replacement associated with MAIVF reconstruction. Prosthetic valve endocarditis was the indication for surgery in all patients. Mean age was 56 ± 20.8 years. Three patients were men. The four patients had a history of two previous valve surgeries, stroke, and renal failure. Patient clinical features and surgical procedure are described in Table 1.

The surgical technique was similar to the one described by David in 1997. (1) An extended aortotomy was performed in the non-coronary sinus, and the incision was extended onto the left atrial roof as a prolongation of the transseptal approach to expose the mitral valve, (2) resulting in excellent exposure of aortic and mitral valves (Figure 1). In all the cases, MAIVF reconstruction was performed using bovine pericardial patches. The pericardial neofibrous membrane allowed anchoring both mitral and aortic prostheses. Once the mitral prosthesis was fixed to the annulus, the posterior end of the patch was used to reconstruct the left atrial roof (Figure 2). The anterior end was employed to reconstruct the aortotomy except for a case in which the aortic valve procedure consisted in aortic root replacement (Bentall-De Bono procedure) due to extensive tissue damage.

Mean aortic cross-clamping and extracorporeal circulation times were 228 ± 33 and 260 ± 48 minutes, respectively.

One patient died during surgery due to bleeding. Another patient died of mycotic endocarditis three months after surgery. The remaining two are alive, free from sepsis and asymptomatic after 1.7 years of

Table 1. Patient characteristics, history and procedures

Patient	Comorbidities	Germ	Prior surgeries	Procedure
# 1	Morbid obesity CRF - AF Ischemic stroke	Staphylococcus aureus	1) Mitral valve repair 2) MVR (bioprosthesis)	MAIVF reconstruction AVR # 25, MVR # 31 (bioprosthesis)
# 2	Diabetes CRF Hemorrhagic stroke	Staphylococcus aureus	1) Mechanical AVR, MVR 2) Mechanical AVR	MAIVF reconstruction AVR # 23, MVR # 29 (bioprosthesis)
# 3	RF in hemodialysis Ischemic stroke	Unidentified	1) Mechanical MVR 2) Mechanical MVR plus reconstruction of the mitral annulus with pericardial patch and CABG	MAIVF reconstruction Mechanical MVR # 25, re-reconstruction of the mitral annulus with Bentall-De Bono bovine pericardium valved conduit # 19, tube # 22
# 4	Diabetes CRF - AF Ischemic stroke	Staphylococcus aureus	1) Mechanical MVR 2) Mechanical AVR	MAIVF reconstruction Mechanical AVR # 23, MVR # 31

CRF: Chronic renal failure. AF: Atrial fibrillation. MVR: Mitral valve replacement. AVR: Aortic valve replacement. MAIVF: Mitral-aortic intervalvular fibrosa. RF: Renal failure.

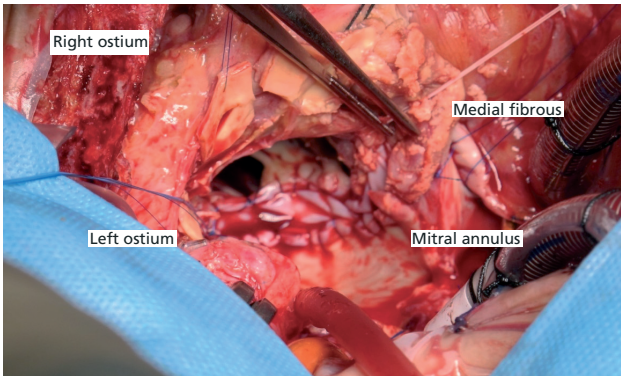

Fig. 1. Case # 3 The aortic root was resected and the coronary ostia were separated. Aortic reconstruction required root replacement due to extensive tissue damage. The mitral annulus was reconstructed using a bovine pericardial patch.

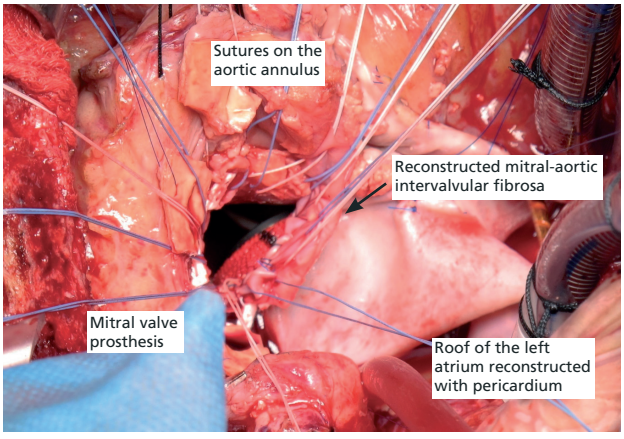

Fig. 2. The mitral valve prosthesis has been fixed to the annulus, the pericardial patch was used to reconstruct the mitral-aortic intervalvular fibrosa, and its posterior end to reconstruct the roof of the left atrium. The attachment points of the aortic prosthesis have been inserted through the annulus and the reconstruction patch.

follow-up.

The basic principle of surgical treatment for endocarditis is the radical excision of all infective tissues, which can include MAIVF debridement. In this situation, usually including double valve replacement, we can reconstruct the structure with a pericardial patch, which generates a strong supporting element for the prostheses used.

This surgical technique was described in 1971, in a series of 43 patients undergoing double valve replacement and MAIVF reconstruction within a period of 11 years in a Canadian center. The series included patients with multiple indications to reconstruct MAIVF (small valve annulus, tissue damage from prior surgeries, extensive calcification) and only 14 patients (32.5%) who had endocarditis. Operative mortality rate was 16%, and actuarial survival rate was 56% at 6 years. In 2005, the same group published the long-term follow-up of a series including 76 cases (3), 20% of them with active endocarditis, operated within a period of 17 years. Fifty-five patients had history of previous operations. Operative mortality rate was 10%. The 10-year survival rate was 50%, and freedom from reoperation within the same period was 73%. The causes for reoperation were repeated prosthetic valve endocarditis and patch dehiscence in similar proportion.

The high risk of operative mortality as a result of prosthetic valve endocarditis is widely known. (4) In the context of the operation described in this report, such concept is endorsed by a recent publication on 25 patients with prosthetic valve endocarditis who underwent double valve replacement with MAIVF reconstruction. In this study, which included patients during a 13-year period in a high-volume European center; 30-day mortality was 32%. (5)

This series shows our initial experience in MAIVF reconstruction in a consecutive group of high-risk surgical patients in a 4-year period. Perioperative and follow-up outcomes, though not representative because of the small number of operated patients, are consistent with data from international publications.

Ricardo Marenchino, Alberto Domenech[MTSAC], Vadim Kotowicz, Jorge Balaguer
Department of Cardiovascular Surgery - Hospital Italiano de Buenos Aires J. D. Perón 4190 (C1181ACH) CABA
Tel. 011-1555960511
Tel./Fax 4959-5803/04
e-mail: ricardo.marenchino@hospitalitaliano.org.ar

REFERENCES

1. David T, Kuo J, Armstrong S. Aortic and mitral valve replacement with reconstruction of intervalvular fibrous body. J Thorac Cardiovasc Surg 1997;114:766-72. http://doi.org/c62xgh

2. Guiraudon GM, Ofiesh JG, Kaushik R. Extended vertical transatrial septal approach to the mitral valve. Ann Thorac Surg 1991;52:1058-62. http://doi.org/d6mr32

3. De Oliveira N, David T, Armstrong S, Ivanov J. Aortic and mitral valve replacement with reconstruction of intervalvular fibrous body: An analysis of clinical outcomes. J Thorac Cardiovasc Surg 2005;129:286-90. http://doi.org/bkwrmm

4. David T, Gavra G, Feindel G, Regesta T, Armstrong S, Maganti M. Surgical treatment of active infective endocarditis. A continued challenge. J Thorac Cardiovasc Surg 2007;133:144-9. http://doi.org/dzg2zh

5. Davierwala P, Binner Ch, Subramanian K, Luer M, Pfannmueller B, Etz Ch, et al. Double valve replacement and reconstruction of the intervalvular fibrous body in patients with active infective endocarditis. Eur J Cardiothorac Surg 2014;45:146-52. http://doi.org/xvx

Rev Argent Cardiol 2015;83:56-57 - http://dx.doi.org/10.7775/rac.v83.i1.4368

Smartphones for Transmission of Digital ECG Images in Patients with Acute Coronary Syndromes

Diagnosis of acute coronary syndrome (ACS) is based on a diagnostic triad in which ECG tracing is essential. In most cases, particularly in patients with ST segment elevation ACS (STE-ACS), the description of

symptoms and the electrocardiogram (ECG) are the tools defining the therapeutic approach. (1)

The latest international guidelines for diagnosis and treatment of STE-ACS highlight the importance of ECG records within 10 minutes of medical contact for patients suspected of acute myocardial infarction, (1)

Prehospital ECG and its prompt interpretation translate into rapid reperfusion therapy, decreasing treatment delays, morbidity and mortality.

In addition to proper ECG interpretation, knowing the infarct site could speed the time to reperfusion, allowing the interventional cardiologist to design the best strategy to approach the infarct-related artery. In many cases, the first attending physician is not trained enough to interpret the tracing, and there is no other trained professional available for consultation. (2)

For this reason, different strategies have been designed as a possible solution to this problem. The ECG recording systems and remote transmission are a highly expensive alternative that is difficult to implement, and require an online specialist for ECG interpretation. (2) In Argentina, some networks have implemented this system but, in practice, the outcomes have been poor. (3)

Smartphones, as well as social networks, are widely used. (4)

The hospital network depending on the Government of the Autonomous City of Buenos Aires (CABA) offers a referral system to the Hospital General de Agudos Dr. Cosme Argerich for patients suspected of STE-ACS requiring primary percutaneous coronary intervention. Referring hospitals (RH) do not always have an on-call cardiologist, making it difficult to interpret ECG correctly, with the resulting delays. In the light of this problem, the practice of taking ECG photographs with the mobile phone and sending them to the on-call interventional cardiologist through social networks while arranging patient referral is being implemented.

The purpose of this study is to present the first experience in the use of smartphones to capture ECG images of STE-ACS patients and transmit them through social networks, and to determine its usefulness in ECG evaluation by the interventional cardiologist.

The study population includes patients suspected of STE-ACS, referred to Hospital General de Agudos Dr. Cosme Argerich from other public and/or private general hospitals of CABA and its outskirts.

Four of the 13 Acute General Care Hospitals do not have on-call cardiologists on a daily basis. The Emergency Medical Care System (SAME) of the CABA Government is in charge of coordination and transfer of patients.

Percutaneous coronary intervention is requested via SAME, which organizes a conference call between the interventional cardiologist and the RH attending physician. The Emergency Interventional Cardiology Team is activated (interventional cardiologist, nurse and catheterization laboratory technician). At the moment of coordinating the transfer, the RH attending physician was asked to send the digital ECG images to the interventional cardiologist via social network. All the interventional cardiologists in the team had a smartphone that could store the information received and enlarge the images with the zoom function.

The patients whose digital ECG images were sent to the interventional cardiologist were assessed retrospectively.

The number of transmissions, delay in tracing reception, tracing quality (clarity, ability to evaluate magnitudes in millimeters, integrity of the tracing and standard visualization), reasons for not sending a tracing, consistency between both ECGs, diagnostic ability, and the possibility of generating algorithms to identify the culprit vessel were analyzed. (5)

The diagnostic report of each ECG performed by two independent cardiologists was compared to assess consistency.

Categorical variables are expressed through frequency and percentage. Numerical variables are expressed as mean ± standard deviation or median and interquartile range (IQR 25-75), depending on the distribution.

Between January 1 and August 31, 2013, referral for primary PCI was requested in 77 patients. Electrocardiographic images were requested and sent for 60 patients (78%) via WhatsApp.

The images were received within 10 minutes in 95% of the cases. On three occasions (5%) images were not received in a timely manner.

The images available from 56/57 patients (98.2%) were adequate for interpretation.

Image quality: heart rate and cardiac rhythm were clearly identified in all cases.

The lines equivalent to 1 mV were identified in 48 patients (85.7%), and the horizontal lines equivalent to 5 mV were identified in all patients (100%). The 0.04'' vertical lines were identified in 39 patients (65%) and the 0.20'' lines in 100% of cases.

Sending multiple images (maximum 6) was necessary in 46 cases (82%) in order to obtain the leads of the original tracing. Consistency between both ECGs was found in 100% of cases with good quality images (56 patients); in these cases it was possible to determine the culprit artery.

ECG is the first-line diagnostic tool for STE-ACS. Misinterpretation leads to frequent referrals with wrong diagnoses, or to lack of alarm and no referral. (2)

Electrocardiographic tracing acquisition and transmission systems have not been widely used due to costs, operative and maintenance constraints, and the need for an online receiver. (2)

In Argentina, there are currently 12 million phone lines with mobile Internet, 90% of which are supported in smartphones. Of the social networks and/or

instant messaging applications available, WhatsApp is preferred by 77% of users in Argentina. (4)

In our case, the ECG tracing image was well received, within 10 minutes in most cases.

Its quality allowed the diagnosis of rhythm, heart rate, and ST and QRS configuration. There was total consistency between images.

In recent studies on smartphone transmission of ECG and complementary tests to the emergency medical services, outcomes were similar. (6)

Based on this experience, the inclusion of ECG images could become a routine in the future.

It is necessary to evaluate whether this approach will improve diagnosis and avoid delays or unnecessary referrals.

This widespread technology enables the transmission and analysis of ECG images in patients suspected of STE-ACS. This first experience has been encouraging, given its cost and the easy analysis by the specialist, and it has been included in the logistics routine of our group.

Acquisition and transmission of the electrocardiographic tracing in STE-ACS, using smartphones, is feasible and useful. Its continuity will let us evaluate whether it translates into reduction of time intervals and improved outcomes in STE-ACS reperfusion.

Alejandro García Escudero[MTSAC], Rodrigo L. Blanco, Federico Blanco[MTSAC], Gerardo Gigena, Jorge L. Szarfer[MTSAC], Juan Gagliardi[MTSAC]
Hospital de Agudos "Dr. Cosme Argerich"
Department of Cardiology Buenos Aires, Argentina
Alejandro García Escudero, M.D. Av. Alte. Brown 240, 2° piso - (C1155ADP) Buenos Aires, Argentina
Tel/Fax: 4121-0873 - e-mail: agescudero@yahoo.com

REFERENCES

1. Yancy CW, Jessup M, Bozkurt B, Butler J, Casey DE, Jr, Drazner MH, et al. 2013 ACCF/AHA guideline for the management of heart failure: a report of the American College of Cardiology Foundation/American Heart Association Task Force on Practice Guidelines. J Am Coll Cardiol 2013;62:e147-239. http://doi.org/f2mtdx

2. Ting HH, Krumholz HM, Bradley EH, Cone DC, Curtis JP, Drew BJ, et al. Implementation and integration of prehospital ECGs into systems of care for acute coronary syndrome: a scientific statement from the American Heart Association Interdisciplinary Council on Quality of Care and Outcomes Research, Emergency Cardiovascular Care Committee, Council on Cardiovascular Nursing, and Council on Clinical Cardiology. Circulation 2008;118:1066-79. http://doi.org/fxfzcn

3. Mariani J, De Abreu M, Tajer C. Tiempos y utilización de terapia de reperfusión en un sistema de atención en red. Rev Argent Cardiol 2013;81:233-9. http://doi.org/s2r

4. Tomoyose G. Quién es el rey de la mensajería en los teléfonos celulares. 2013. http://www.lanacion.com.ar/1617156. 3-ene-2013

5. Engelen DJ, Gorgels AP, Cheriex EC, De Muinck ED, Ophuis AJ, Dassen WR, et al. Value of the electrocardiogram in localizing the occlusion site in the left anterior descending coronary artery in acute anterior myocardial infarction. J Am Coll Cardiol 1999;34:389-95. http://doi.org/d8gtpk

6. Bergrath S, Rossaint R, Lenssen N, Fitzner C, Skorning M. Prehospital digital photography and automated image transmission in an emergency medical service an ancillary retrospective analysis of a prospective controlled trial. Scand J Trauma Resusc Emerg Med 2013;21:3. http://doi.org/xvz

Rev Argent Cardiol 2015;83:57-59 - http://dx.doi.org/10.7775/rac.v83.i1.3833

Hyperdominant Left Anterior Descending Coronary Artery: Clinical Implications

Coronary anomalies are usually discovered incidentally in 0.2% to 1.2% of the overall population.

The anomalous origin of the posterior descending artery from the anterior descending artery in the presence of non-dominant circumflex and right coronary arteries is rare, with very few cases described in the literature.

The posterior descending artery originates in the right coronary artery or the circumflex artery. We describe the case of a patient with severe stenosis of the hyperdominant left anterior descending coronary artery, continuing across the left ventricular apex as posterior descending artery beyond the crux in the presence of circumflex and small right coronary arteries, and its clinical implication.

A 61-year old male patient, hypertensive, smoker, obese, with dyslipidemia and unremarkable past medical history, was admitted to another center for acute myocardial infarction. The ECG during pain showed sinus rhythm, ST-segment elevation in DIII, aVR, V1 and ST-segment depression in DI, aVL, DII, aVF, and V3 to V6, which were interpreted as ECG changes consistent with left main coronary artery (LMCA) disease (Figure 1). Lab tests revealed increased troponin I in the range of infarction (2.63 ng/ml; normal ≤ 0.40 ng/ml). The patient was referred to our center, 48 hours after the initial event, for a coronary angiography which showed no LMCA obstruction, and presence of severe stenosis in the proximal portion of a hyperdominant left anterior descending artery (ADA) continuing across the left ventricular apex as posterior descending artery (PDA). This divided beyond the crux into two branches extending to both sides of the atrioventricular (AV) groove, and also originated the AV node artery, the circumflex artery (Cx) without significant obstructions (Figure 2 A) and the small right coronary artery (RCA) (Figure 2 B) also without significant obstructions.

The LMCA was catheterized using a XB 3.5 6 Fr guiding catheter through the right femoral artery. A 0.014" floppy guidewire was progressed to the distal ADA and two Tango™ cobalt chromium stents (MicroPort Medical), one measuring 3.5 mm diameter and 18 mm length, and the other 3.5 mm diameter and 13 mm length were respectively impacted at 18 atm from distal to proximal, with good angiographic result. (Figures 2C & 2D).

The patient was sent to the coronary care unit and transferred to the referring center without complications, 24 hours after the procedure.

No two coronary anatomic patterns are alike and there is a wide range of variability within the normal

distribution. Coronary artery anomalies represent marked deviations from normal, but have an incidence of 0.2-1.2% across different racial groups. Right dominance (85%) is the pattern where the PDA, the posterolateral branches and the AV node artery arise from the RCA, and left dominance (8%) is the pattern where these vessels originate from the Cx.

Co-dominance (7%) occurs when the PDA arises from the RCA and the posterolateral branches of the Cx. Only a few cases have been reported on the origin of the PDA from a hyperdominant ADA. (1-3) Musselman & Tate reported the first case in which the PDA originated from the ADA and continued beyond the crux. Then, the PDA divided into two branches that went to both sides of the AV groove, and also gave rise to the AV node artery. (4) Boochi Babu described the second case, in which the ADA continued as the PDA beyond the crux into the left posterior AV groove, and the first case for which successful primary percutaneous intervention was done in the middle portion of the ADA in a patient with anterior and inferior wall acute myocardial infarction. (5)

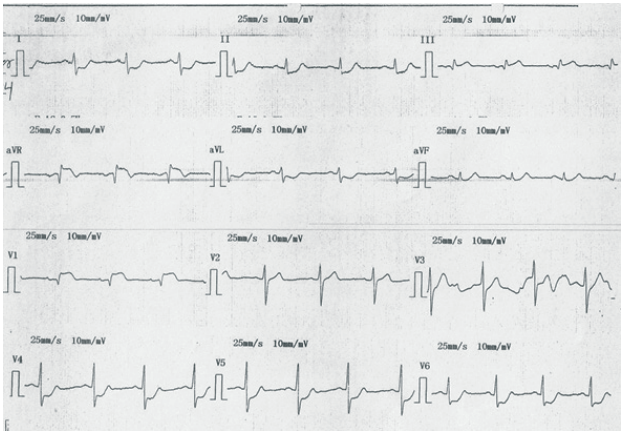

Fig. 1. ECG showing changes consistent with left main coronary artery disease: ST segment elevation in DIII, aVR and V1, and ST segment depression in DI, aVL, DII, aVF and V3 to V6.

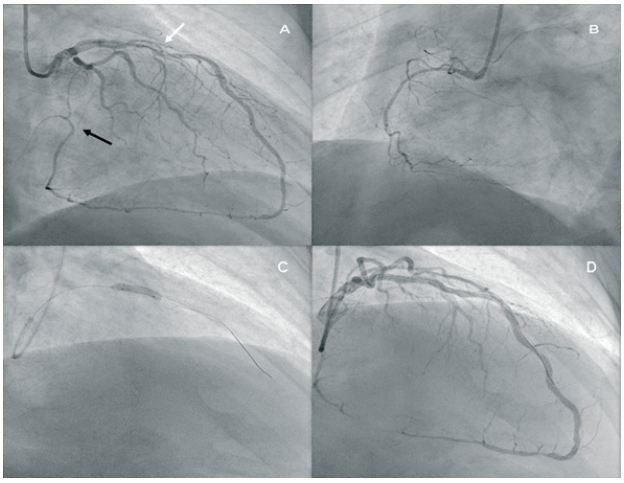

Fig. 2. A. Hyperdominant anterior descending artery with severe proximal stenosis (white arrow) continuing as posterior descending artery. This divides beyond the crux into two branches that extend to both sides of atrioventricular groove and also gives rise to the atrioventricular node artery (black arrow). **B.** Small right coronary artery. **C.** Stent implantation. **D.** Final result of the percutaneous coronary intervention.

Our report constitutes the third case of hyperdominant ADA continuing as PDA beyond the crux, and the second case of successful percutaneous intervention for this type of coronary anomaly.

Kaul described a case of massive biventricular myocardial infarction following acute occlusion of the hyperdominant ADA which caused the development of a large ventricular septal defect and right ventricular free wall rupture. The patient required 6 surgical procedures over a period of 2 years due to extensive myocardial involvement. (6)

In conclusion, the clinical implication of this type of anomaly is that, in case of an event, it will cause a large anterior, septal and inferior myocardial infarction that could lead to cardiogenic shock with high morbidity and mortality, because this type of coronary lesion behaves similarly to that in the LMCA. The interventional cardiologist should be aware of this anomaly when treating a patient with myocardial infarction involving the anterior and inferior walls of the heart, since early revascularization can save their lives and avoid the catastrophic complications following massive myocardial infarction.

Marcel G. Voos Budal Arins, Jorge N. Wisner[MTSAC], Alejandro Tettamanzi
Interventional Cardiology and Hemodynamic Unit
Hospital Universitario CEMIC. Buenos Aires, Argentina
Marcel G. Voos Budal Arins - Av. Triunvirato 4355 - Piso 5º Dpto. B - (1431) CABA - e-mail:marcelvoos@gmail.com

REFERENCES

1. Clark VL, Brymer JF, Lakier JB. Posterior descending artery origin from the left anterior descending: an unusual coronary artery variant. Cath Cardiovasc Diagn 1985;11:167-71. http://doi.org/chxnx9

2. Hamodraka ES, Paravolidakis K, Apostolou T. Posterior descending artery as a continuity from the left anterior descending artery. J Invasive Cardiol 2005;17:343.

3. Javangula K, Kaul P. Hyperdominant left anterior descending artery continuing across left ventricular apex as posterior descending artery coexistent with aortic stenosis. J Cardiothorac Surg 2007;2:42. http://doi.org/b5qmz3

4. Musselman DR, Tate DA. Left coronary dominance due to direct continuation of the left anterior descending to form the posterior descending artery. Chest 1992;102:319-20. http://doi.org/fn89w6

5. Boochi Babu M. Hyperdominant left anterior descending artery continuing as posterior descending posterior artery: A rare coronary artery anomaly. Cath Lab Digest 2013;21:35-6.

6. Kaul P. Repeated successful surgical rescues of early and delayed multiple ruptures of ventricular septum, right ventricle and aneurysmal left ventricle following massive biventricular infarction. J Cardiothorac Surg 2006,1:30. http://doi.org/bgff99

Rev Argent Cardiol 2015;83:59-60 - http://dx.doi.org/10.7775/rac.v83.i1.4857

Transseptal Approach for Surgical Removal of Myxoma

The aim of the surgical treatment of myxoma includes resection of the base of the tumor with good safety margins to prevent recurrence, control of friable mass completeness to avoid embolization, exploration of the rest of the heart chambers for multiple formations, and correction of residual defects after resection. Traditionally, the approach to left atrial myxomas is performed through a left atriotomy below the interatrial groove (left atriotomy). However, this approach does not offer the best exposure when it comes to large tumors in small atria that require careful surgical management. Transseptal approach to left atrial myxoma resection was proposed by Chitwood Jr (1) over two decades ago, as an alternative technique to the method through the interatrial groove. Immediately after, Miralles et al (2) reported a series of 47 tumors in the left atrium using transseptal approach for resection in most cases, and with patch reconstruction of the interatrial septum in 75% of patients. Postoperative mortality was 1.9%, and no complications or recurrences wee reported in the long-term follow-up. Since this report, new studies using this surgical approach have only been sporadically reported.

We have previously described the use of routine transseptal approach for mitral valve surgery. (3) This time, we report the experience of transseptal approach for surgical removal of left atrial myxomas. Between 2004 and 2013, 16 consecutive patients with left atrial myxoma underwent surgical transseptal approach consisting of right atriotomy and opening of the interatrial septum including the left atrial roof (4) (Figures 1 & 2) (See video on the web).

This series corresponded to 0.5% of the cardiac surgeries performed in the same period, in patients with mean age of 54.8 years (range 31-84 years) and prevalence of female patients (75.0%). Transseptal approach allowed easy surgical removal of myxomas in all cases, regardless of the size and implantation site. The average tumor size was 5.3 cm (range 3-8 cm); implantation base was mainly located in the atrial septum (81.3%), and the rest in the inferior and posterior walls. Only 12.5% patients were treated with an autologous pericardial patch to repair the defect resulting from resection.

In our series, no operative mortality or episodes of stroke or residual shunt in the short-term was observed. Conversely, some authors have suggested that the left atrial approach presents higher risk of interatrial shunt, given the difficulty of visualizing a residual defect after myxoma resection. (5)

On the other hand, the principal criticism to transseptal approach is the high incidence of AV block. (5-6) However, these disorders can be significantly reduced by limiting the extent of the right atriotomy and avoiding the injury to the sinus node artery in the roof of the left atrium. Although permanent AV block was observed in 4.8% of patients in our previous report on mitral replacements, (3) in this series of myxomas, none of the patients required permanent pacemaker.

There are no large studies on the transseptal method for myxoma resection, and the ideal approach is still controversial. (7, 8) In a 30-year clinical experience, Jones et al (6) concluded that the biatrial technique is the safest approach to expose and manipulate tumors. On the other hand, other authors consider that left atriotomy is the method of choice, since it is associated with low rate of recurrence. (9) Stevens

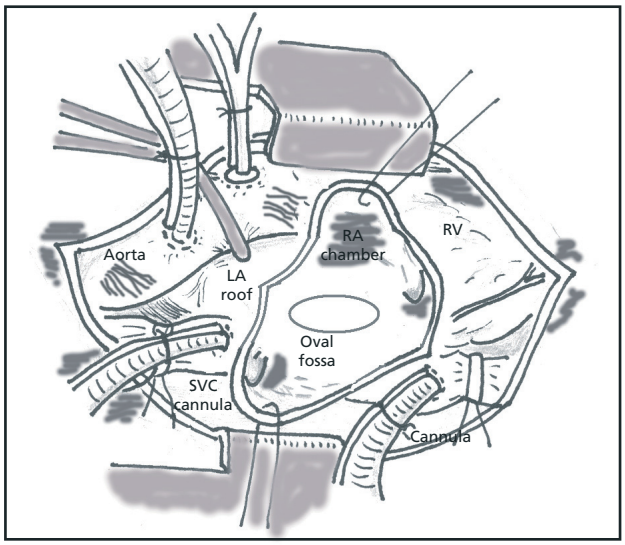

Fig. 1. Initial right atriotomy (RA), exposing the oval fossa. The dotted line shows the incision on the atrial septum extending to the roof of the left atrium (LA). RV: Right ventricle. SVC: Superior vena cava.

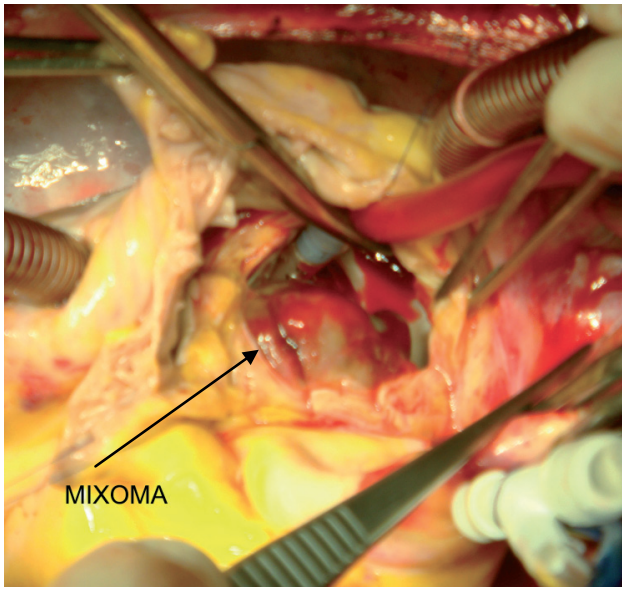

Fig. 2. Photograph of the surgical exposure of a left atrial myxoma with transseptal approach. The large field of view with this approach is significant.

et al (5) presented a retrospective comparison of the outcomes from 58 myxomas surgically removed using atrial or biatrial approach (41% and 59% of cases, respectively). In order of frequency with the biatrial technique, 45% were separate left and right atriotomy, 8% right atriotomy + transseptal incision, and 6% right and left atriotomy + transseptal incision, as those performed in our study. These authors reported that there were no significant differences among the different techniques regarding postoperative bleeding, length of stay, and survival at almost 9 years. Conversely, the biatrial approach required longer cross-clamping time and extracorporeal circulation compared with the left atrial approach (55 vs 41 min and 76 vs 59 min, respectively). In our series, times were much shorter (26 ± 3.9 min and 51 ± 8.2 min), probably due to the experience with this approach for mitral valve surgery. Finally, the transseptal approach was also used to successfully resect a myxoma through a proximal ministernotomy. (10)

Although the sample is small, the series presented here is the largest in the recently published literature, with biatrial approach and transseptal incision.

In conclusion, the transseptal approach is an alternative technique for myxoma resection, because it offers safe and ample exposure to avoid embolic complications.

Raúl A. Borracci[MTSAC], Miguel Rubio[MTSAC], Julio Baldi (h), Ricardo L. Poveda Camargo
Hospital de Clínicas, Facultad de Medicina,
Universidad de Buenos Aires
Av. Córdoba 2351 - Buenos Aires, Argentina
raborracci@gmail.com

REFERENCES

1. Chitwood Wr Jr. Cardiac neoplasms: Current diagnosis, pathology and therapy. J Card Surg 1988;3:119-54. http://doi.org/bq42rp

2. Miralles A, Bracamonte L, Rabago G, Pavie A, Bors V, Gandjbakhch I, et al. Intracardiac myxoma: surgical treatment with trans-septal approach. Helv Chir Acta 1990;57:203-7.

3. Borracci RA, Rubio M, Milani A, Ramírez F, Barrero C, Rapallo CA, et al. Transseptal Approach for mitral Valve Replacement. Rev Argent Cardiol 2010;78:400-4.

4. Pezzella AT, Effler DB, Levy IE. Operative approaches to the left atrium and mitral valve apparatus. Tex Heart Inst J 1983;10:119-23.

5. Stevens LM, Lapierre H, Pellerin M, El-Hamamsy I, Bouchard D, Carrier M, et al. Atrial versus biatrial approaches for cardiac myxomas. Interact Cardiovasc Thorac Surg 2003;2:521-5. http://doi.org/cpwch6

6. Jones DR, Warden HE, Murray GF, Hill RC, Graeber GM, Cruzzavala JL, et al. Biatrial approach to cardiac myxomas: A 30-year clinical experience. Ann Thorac Surg 1995;59:851-6. http://doi.org/dj28qr

7. Dar MI, Khan AB, Aftab S, Rashdi S, Mahmood SA. Management of left atrial myxomas at civil hospital, Karachi. Pak J Surg 2008;24:42-5.

8. Khan MS, Sanki PK, Hossain MZ, Charles A, Bhattacharya S, Sarkar UN. Cardiac myxoma: A surgical experience of 38 patients over 9 years, at SSKM Hospital Kolkata, India. South Asian J Cancer 2013;2:83-6. http://doi.org/vdj

9. Meynes B, Vanclemmput J, Flameng W, Daenen W. Surgery for cardiac myxoma: A 20-year experience with long term follow-up. Eur J Cardiothorac Surg 1993;7:437-40. http://doi.org/cf573r

10. Marumoto A, Ashida Y, Maeta H, Ishiguro S, Kuroda H, Ohgi S. Surgical removal of left atrial myxoma through mini sternotomy and the superior transseptal approach. Jap J Thorac Cardiovasc Surg 2001;49:185-7. http://doi.org/cxtb5c

Rev Argent Cardiol 2015;83:61-62 - http://dx.doi.org/10.7775/rac.v83.i1.4295