

## Quadricuspid Aortic Valve: Echocardiographic Assessment and Anatomic Correlation

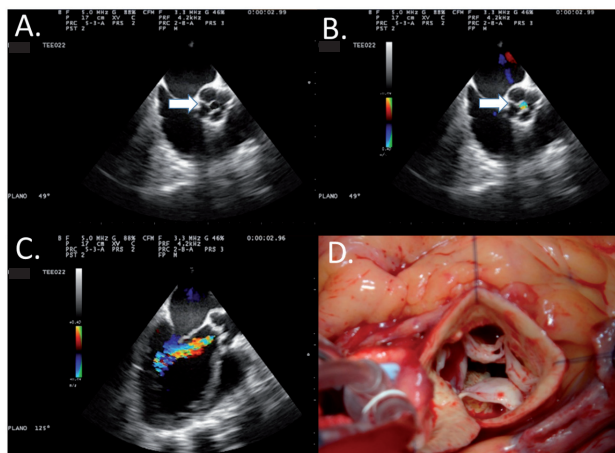
*Válvula aórtica cuadrícuspide: evaluación ecocardiográfica y correlación anatómica*

PABLO ELISSAMBURU<sup>1</sup>, MARIANO CAMPORROTONDO<sup>2</sup>, DIEGO CONDE<sup>1</sup>

Quadricuspid aortic valves are very rare, with a reported incidence of 0.008% in autopsy series and 0.01-0.04% in echocardiography series. (1, 2) Depending on the size of each aortic cusp, seven anatomic types or variants are described: type A, four equal cusps; type B, three equal cusps and one smaller cusp; type C, two equal larger cusps and two equal smaller cusps; type D, one large, two intermediate and one small cusp; type E, three equal cusps and one larger cusp; type F, two equal larger cusps and two unequal smaller cusps; and type G, four unequal cusps. (3) Aortic regurgitation is the most prevalent finding, with an incidence of about 75% of cases, while aortic stenosis is extremely rare (0.7%). (4)

These images correspond to a 63-year-old hypertensive male patient, smoker, with hypertension and dyslipidemia, who was admitted due to non-ST segment elevation acute coronary syndrome. Coronary angiography revealed severe disease in three coronary vessels. Preoperative transthoracic color Doppler ultrasonography showed left ventricular dilatation with severe deterioration of systolic function (EF 30% - biplane Simpson method) due to mid anteroseptal, mid anterior apical, mid lateral apical, and strictly apical akinesia, with hypokinesia in the rest of the segments. The aortic root was not dilated, and the aortic valve appeared to be quadricuspid with mild fibrosis of valve cusps. Color Doppler visualized a central regurgitant jet of moderate intensity, with a pressure half time of 466 msec and vena contracta of 0.4 cm. A preoperative transesophageal echocardiography was performed using GE Vivid 7 equipment with multiplane probe for better assessment of the aortic valve and cusps, and to confirm the mechanism of regurgitation.

Mid-esophageal four-chamber view at 0° with ante-flexion of the probe tip and 44-45° rotation provided a mid-esophageal short axis view of the aortic valve in the center of the image, with its four equal cusps, which would correspond to the type A variant (Image A, arrow), and color Doppler revealed central regurgitant jet originating in the valve coaptation point (Image B, arrow). From this view it is possible to observe in detail the valvular structure, analyze the cusps, insertion, type of lesion and coaptation point. Increasing



the angle to 120-135°, the assessment continues with a long-axis view, which includes the left ventricular outflow tract (LVOT), aortic valve, and proximal portion of the ascending aorta (Image C). The jet width and how it relates to LVOT diameter (jet width / LVOT diameter), together with the vena contracta of the regurgitant jet were quantified from this view. The valve coaptation point, prolapse and restrictions in some of the cusps should also be determined in this view, and all the aortic root measurements should be obtained as possible mechanisms of regurgitation. In our patient, the mechanism of aortic regurgitation was a coaptation deficit associated with mild fibrosis of the cusps. Diameters in the aortic root were normal.

### Conflicts of interest

None Declared

### REFERENCES

1. Timperley J, Milner R, Marshall AJ, Gilber TJ. Quadricuspid aortic valve. *Clin Cardiol* 2002;25:548-52. <http://doi.org/d8jvgr>
2. Oberti P, Falconi M, Arias A. Dos, tres y... ¡cuatro! Válvula aórtica cuadrícuspide. *Rev Argent Cardiol* 2006;74:473.
3. Hurwitz LE, Roberts WC. Quadricuspid semilunar valve. *Am J Cardiol* 1973;31:623-6. <http://doi.org/bxkxhd>
4. Tutarel O. The quadricuspid aortic valve: a comprehensive review. *J Heart Valve Dis* 2004;13:534-7.

*Rev Argent Cardiol* 2015;83:155. <http://dx.doi.org/10.7775.rac.v83.i2.5272>

**Address for reprints:** Dr. Pablo Elissamburu - Av. Del Libertador 6302 - Piso 10 - (1428) CABA, Argentina - e-mail: [elissamburupablo@gmail.com](mailto:elissamburupablo@gmail.com)

Sanatorio Anchorena - Instituto Cardiovascular de Buenos Aires (ICBA)

<sup>1</sup> Department of Cardiology

<sup>2</sup> Department of Cardiac Surgery