

Diagnostic Ability of Physical Examination in Aortic Valve Stenosis

La capacidad diagnóstica del examen físico en la estenosis valvular aórtica

JORGE I. PARRAS, JOSÉ M. ESCALANTE, JUAN M. LANGE

ABSTRACT

Background: Physical examination is essential to detect aortic stenosis but there is scarce information currently available.

Objectives: The goal of this study is to evaluate the diagnostic yield of physical examination, the interobserver agreement of clinical signs, and to establish a score to identify severe aortic stenosis.

Methods: One-hundred patients were included in the study. Before echocardiographic evaluation, two cardiologists independently evaluated the clinical signs of the physical examination in aortic stenosis. Sensitivity, specificity, and inter-observer agreement were calculated, and the area under the curve was analyzed to develop a score for predicting severe aortic stenosis.

Results: The decreased intensity of the first heart sound and the crescendo-decrescendo shape of the murmur had sensitivity >90% and specificity <70%.

The specificities of an absent second sound, a murmur that peaks later in systole and the presence of a parvus et tardus pulse were >95%, but the sensitivities were <50%.

Inter-observer agreement was good for most criteria, except for murmur shape and intensity. The best area under the curve was achieved by the score composed of heart sounds of decreased or absent intensity, duration of the holosystolic murmur, parvus et tardus carotid pulse and a grade 3-4 systolic murmur.

Conclusions: Physical examination findings have low sensitivity but good specificity. Inter-observer agreement of clinical signs of severity was moderately good. Correct identification of patients with severe aortic stenosis can be achieved using a simple score.

Key words: Aortic Valve Stenosis - Diagnosis - Echocardiography

RESUMEN

Introducción: El examen físico es fundamental para detectar estenosis aórtica, pese a lo cual son pocos los datos actuales disponibles.

Objetivos: Evaluar la capacidad diagnóstica del examen físico, el acuerdo entre observadores de los signos y establecer un puntaje que permita identificar estenosis aórtica grave.

Material y métodos: Se incluyeron 100 pacientes. Previo a la realización del estudio ecocardiográfico, dos cardiólogos evaluaron en forma independiente los signos del examen físico de la estenosis aórtica. Se calcularon los valores de sensibilidad, especificidad, acuerdo entre observadores y mediante análisis de área bajo la curva se construyó un puntaje para predecir estenosis aórtica grave.

Resultados: El primer ruido hipofonético y la forma creciente-decreciente del soplo tuvieron una sensibilidad mayor del 90% con una especificidad menor del 70%.

El segundo ruido ausente, el acmé telesistólico del soplo y la presencia de un pulso parvus-tardus tuvieron especificidades mayores del 95% pero sensibilidades menores del 50%.

El acuerdo fue moderadamente bueno en la mayoría de los criterios, con la excepción de la forma y la intensidad del soplo, en los que fue bajo. El puntaje conformado por ruidos cardíacos hipofonéticos/ausentes, duración del soplo holosistólico, pulso carotídeo parvus-tardus e intensidad 3 o 4 del soplo fue el que mostró mejor área bajo la curva.

Conclusiones: Los hallazgos del examen físico son poco sensibles pero específicos. El acuerdo de los signos clínicos de gravedad es moderadamente bueno. Un puntaje de obtención simple permite identificar adecuadamente a pacientes con estenosis aórtica grave.

Palabras clave: Estenosis valvular aórtica - Diagnóstico - Ecocardiografía

Abbreviations

SAS	Severe aortic stenosis	S2	Second heart sound
S1	First heart sound	LR	Likelihood ratio

REV ARGENT CARDIOL 2015;83:204-209. <http://dx.doi.org/10.7775/rac.v83.i3.5680>

Received: 12/21/2014 - Accepted: 02/11/2015

Address for reprints: Dr. Jorge I. Parras - Instituto de Cardiología de Corrientes. Bolívar 1334 - (3400) Corrientes, Argentina
e-mail: jorgeparras@yahoo.com

Instituto de Cardiología de Corrientes "Juana F. Cabral". Corrientes, Argentina
Doppler Echocardiography Laboratory

INTRODUCTION

Aortic valve stenosis is the most common valvular heart disease in the adult population and its prevalence will probably increase in a near future. (1) Physical examination is still essential when the diagnosis is suspected in patients with or without symptoms.

There is scarce statistical information about the diagnostic yield of physical examination and interobserver agreement for the different physical signs in aortic stenosis. Furthermore, the etiology of aortic stenosis has changed worldwide due to several factors, such as reduction in rheumatic etiology and increase in comorbidities as obesity, chronic obstructive pulmonary disease and hypertension, (2) which might affect the findings of physical examination and would justify its re-evaluation. Finally, despite Doppler echocardiography is currently the diagnostic method of choice, the information of physical examination derives from studies based on invasive methods to identify these patients.

The aim of this study was to evaluate the sensitivity and specificity of the different clinical criteria for determining severe aortic stenosis (SAS), evaluate interobserver agreement for the clinical criteria of severity and establish a score for the better identification of SAS.

METHODS

The study included 100 outpatients referred to the Doppler echocardiography laboratory due to a systolic murmur over the aortic area.

Patients with heart valve prostheses in any position and those with other moderate or severe heart valve disease or subaortic or supra-ventricular aortic stenosis were excluded.

Before performing Doppler echocardiography, two cardiologists independently evaluated the presence of the clinical criteria of aortic stenosis severity listed below, using a standardized form:

- Levine scale for grading murmur intensity from 1 to 6.
- Characteristics of the first heart sound (S1) and second heart sound (S2): normal, decreased intensity or absent.
- Murmur duration: short or long.
- Murmur shape: crescendo-decrescendo or other.
- Murmur intensity: early-systolic, mid-systolic or late-systolic.
- Murmur radiation: to the neck, apex or no propagation.
- Presence or absence of apex beat, evaluated with the patient in the left lateral decubitus position.
- If apex beat is present, evaluate position (normal or displaced) and characteristics (sustained or other).
- Carotid artery upstroke was classified as delayed (*parvus et tardus*) or other.

Finally, each evaluator classified the findings in mild, moderate or severe aortic stenosis.

Blood pressure was normal in all the patients at the time of the study.

Immediately after, Doppler echocardiography was performed to all the patients according to the European Association of Echocardiography/American Society of Echocardiography recommendations. (3, 4)

Peak aortic jet velocity, aortic valve area estimated by continuity equation and mean trans-aortic gradient were determined.

Aortic valve stenosis was classified according to the aortic valve area in:

- Severe: $<1 \text{ cm}^2$.
- Moderate: >1 and $<1.5 \text{ cm}^2$.
- Mild or aortic sclerosis: $>1.5 \text{ cm}^2$.

A cohort of 20 additional patients was included for validating the findings of the first 100 patients.

Statistical analysis

Student's *t* test or ANOVA were used to compare the mean values of the different echocardiographic variables among the clinical criteria of severity according to the physical examination.

The statistical association between the physical signs and the presence of aortic stenosis was evaluated with the chi square test. Sensitivity, specificity and likelihood ratio of the different criteria were calculated to identify SAS. Interobserver agreement of the different criteria and of the final interpretation was evaluated using the kappa coefficient. A ROC curve was built to analyze the different scores integrating SAS criteria. The best score was validated in the additional cohort of 20 patients.

All the calculations were estimated using SPSS 21 statistical package. Medcalc version 9 was used for ROC curve analysis and comparison.

RESULTS

One hundred patients were included in the study. Mean age was 66 ± 13 years; 51% were women and 16% had symptoms. Degenerative etiology was considered in 95% of cases.

The clinical characteristics are summarized in Table 1.

Considering aortic valve area, 21 patients had SAS, 28 had moderate stenosis and 51 had mild stenosis (with insignificant trans-aortic gradient). Mean ejection fraction was $64\% \pm 9\%$. Table 2 shows the echocardiographic variables.

Peak jet velocity and mean trans-aortic gradient corresponded with the severity of aortic stenosis (Table 3).

Clinical criteria assessment

All the patients underwent clinical evaluation.

Only the presence and location of the apex beat were not statistically associated with SAS.

Among the remaining physical exam criteria to predict SAS, S1 with decreased intensity or absent and a murmur with a crescendo-decrescendo shape had a sensitivity of 90% and a specificity of 70%.

The specificity and sensitivity of decreased intensity or absent S2, late-systolic peaking and presence of a *parvus et tardus* carotid artery upstroke were $>95\%$ and $<50\%$, respectively.

Murmur intensity grade ranged from 1 to 4. A grade 3 murmur or greater had one of the best combinations of sensitivity and specificity (95.2% and 63.3%, respectively).

Observer final interpretation to diagnose SAS has a sensitivity of 42.9% with a high specificity of 97.5%

When the same criteria are considered to identify

moderate or severe aortic stenosis, the sensitivity does not exceed 90%. However, the specificity is >90% for absent S2, holosystolic murmur, late-systolic peaking and parvus et tardus carotid artery upstroke.

The sensitivity and specificity of a grade 3 murmur to diagnose moderate or severe aortic stenosis were 75.5% and 76.5%, respectively.

Table 4 summarizes the data for all the criteria.

Figure 1 shows significant clinical differences when comparing mean aortic valve areas calculated

by echocardiography among the different categories of murmur intensity, peak intensity and the characteristic of carotid artery upstroke.

Interobserver agreement

Kappa coefficient was moderately good (>0.41) for most criteria, except for murmur shape (kappa 0.25) and intensity (kappa 0.03). Murmur duration had the best agreement (kappa 0.82). Kappa coefficient estimated for agreement of the final interpretation was 0.45. All the values are displayed in Table 4.

The presence of symptoms had a statistical association with SAS.

Several scores were constructed using the different criteria evaluated except for the apex beat due to low interobserver agreement and because it cannot be evaluated in all the patients.

The score composed of decreased intensity or absent S1 and S2, holosystolic murmur duration, parvus et tardus carotid artery upstroke and grade 3-4 murmur (present: 1 point; absent: 0 point) showed the best area under the ROC curve (0.92, 95% CI 0.85 to 0.97). A score of 3 had a sensitivity of 81% and a specificity of 89.9% for the diagnosis of SAS (Figure 2).

When only murmur intensity is used to identify moderate or severe aortic stenosis, a grade 2 murmur or greater has a sensitivity of 98% but a specificity of 27.5%.

For the score previously described, a value of 2 was the best cut-off point for the diagnosis of moderate or severe aortic stenosis, with a sensitivity of 71.4% and a specificity of 82.4%.

The score was validated in 20 additional patients. The clinical and echocardiographic characteristics were similar to those of the original cohort. The area under the ROC curve was 0.92 (95% CI 0.71 to 0.99). A score of 3 had a sensitivity of 67% and a specificity of 93% to diagnose SAS.

DISCUSSION

The diagnostic threshold in aortic stenosis depends on each patient; yet, it is convenient to use evidence-based rules.

The European Society of Cardiology guidelines on the management of valvular heart disease (5) indicate that the systolic murmur typical of aortic stenosis may occasionally be faint and the disappearance of S2 is a specific but not sensitive sign of SAS. On occasions, SAS may present as heart failure of unknown etiology. The guidelines do not mention other physical

Table 1. Clinical characteristics

Characteristic	Value
Age, years, mean (SD)	66 (13)
Weight, kg, mean (SD)	79 (16)
Height, cm, mean (SD)	164 (10)
BMI, mean (SD)	29.3(5.1)
Body surface area, m ² , mean (SD)	1.89 (0.25)
Female gender, %	51
Hypertension, %	79
Smoking, %	10
COPD, %	2
Diabetes, %	22
Previous myocardial infarction, %	8
Previous CABGS, %	1
Previous PCI, %	6
Symptoms, %	16

SD: Standard deviation. BMI: Body mass index. COPD: Chronic obstructive pulmonary disease. CABGS: Coronary artery bypass graft surgery. PCI: Percutaneous coronary intervention.

Table 2. Echocardiographic characteristics

Variable	Mean Value (SD)
Left atrial dimension, mm	42 (6)
End-diastolic ventricular dimension, mm	47 (7)
End-systolic ventricular dimension, mm	29 (7)
Interventricular septum, mm	12 (2)
Posterior wall, mm	12 (2)
End-diastolic volume, mm	94 (33)
End-systolic volume, mm	35 (22)
Ejection fraction, %	64 (10)

Table 3. Echocardiographic characteristics according to the severity of aortic valve stenosis

	Severe (n = 21) Mean (SD)	Moderate (n = 28) Mean (SD)	Mild (n = 51) Mean (SD)
Aortic valve area, cm ²	1.61 (0.1)	1.61 (0.1)	1.61 (0.1)
Peak jet velocity, m/s	2.6 (0.3)	2.6 (0.3)	2.6 (0.3)
Mean trans-aortic gradient, mm Hg.	16 (4)	16 (4)	16 (4)

	Sensitivity (%)	Specificity (%)	LR+	LR-	Kappa
Absent S1	90.5	59.5	11	0.73	0.47
Absent S2	42.9	98.4	2.23	0.16	0.55
Murmur duration (holosystolic)	81	86.1	27	0.58	0.82
Crescendo-decrescendo shape	90.5	63.3	5.83	0.22	0.25
Peak intensity	28.6	97.4	2.47	0.15	0.52
Radiation to neck	81	63.3	2.21	0.3	0.44
Sustained apex beat	54.5	83.7	3.34	0.54	0.51
Carotid pulsus parvus et tardus	38.1	98.7	29	0.63	0.6
Grade 3 murmur or greater	95.2	63.3	2.59	0.08	0.03
Interpretation as SAS	42.9	97.5	17	0.59	0.45

S1: First heart sound S2: Second heart sound. LR: Likelihood ratio. SAS: Severe aortic stenosis.

Table 4. Sensitivity, specificity and likelihood ratio of the different physical examination signs for the diagnosis of severe aortic stenosis and interobserver agreement estimation.

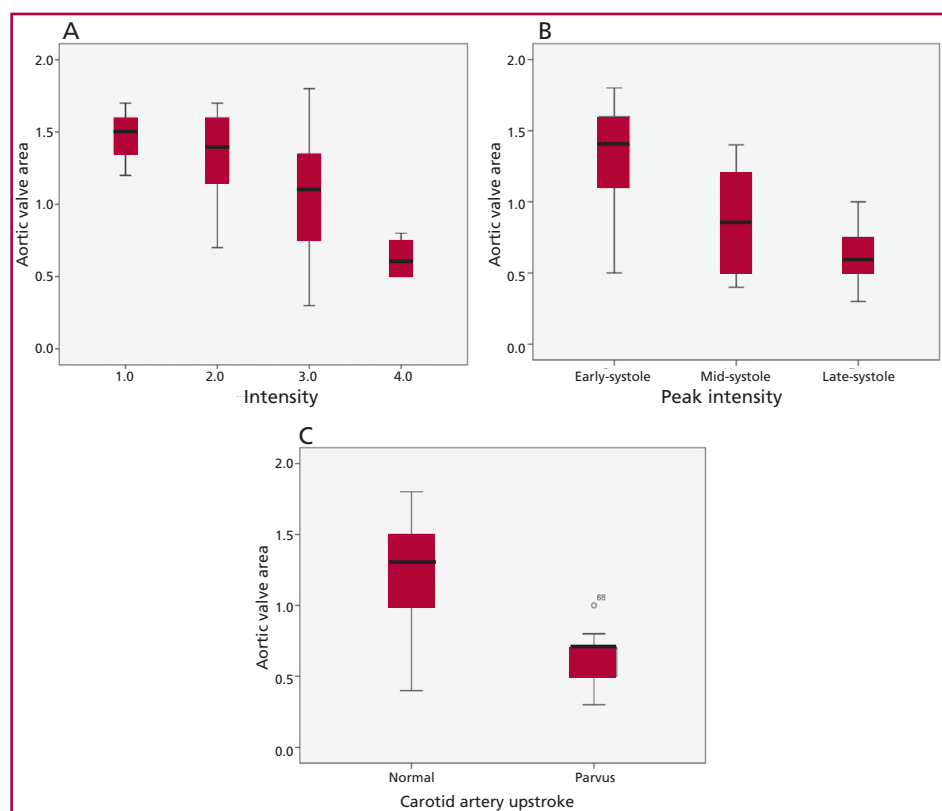


Fig. 1. Mean aortic valve area for murmur intensity (A), peak intensity (B) and the characteristic of carotid artery upstroke (C).

signs suggestive of SAS.

According to the American College of Cardiology/American Heart Association 2006 guidelines (6), the physical signs of aortic stenosis are specific but not sensitive. The guidelines recognize a 4/6 late-peaking systolic murmur that radiates to the carotid arteries and diminished carotid upstroke as classical signs of SAS. However, the murmur may occasionally be faint. The American guidelines recommend Doppler echocardiography in the presence of a grade 3/6 or louder systolic murmur, single S2 or symptoms suggestive of aortic stenosis.

This recommendation has been updated in the 2014 AHA/ACC Guideline (7) and states that Doppler echocardiography is indicated when there is an unexplained systolic murmur or a single S2 that might be due to aortic stenosis.

It can be seen that the evidence available is insufficient and out of date.

Aronow et al. (8) included 75 patients with mean age of 83 years. Prolonged duration of the systolic murmur, late peaking, decreased or absent S2 and prolonged carotid upstroke time were associated with moderate or severe aortic stenosis. However, these

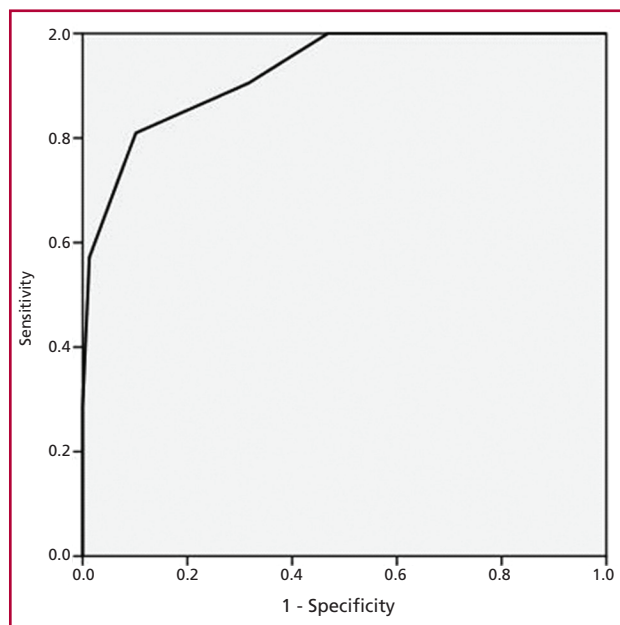


Fig. 2. Area under the score curve to predict severe aortic stenosis.

signs did not differentiate between moderate and severe aortic stenosis. Physical examination was performed by a single observer. In this study, SAS was defined by a peak aortic jet velocity of 3.6 m/s or greater measured by Doppler echocardiography, a criterion that is not currently recommended. These findings were confirmed by the author in a second study including more patients. (9)

McGee (10) reported that in patients with systolic murmurs, several classical signs were associated with peak aortic jet velocity of 2.5 m/s or greater (as seen in mild aortic stenosis). Absent S2 in the second left intercostal space had a positive likelihood ratio (LR+) of 15.7, while the LRs of a murmur radiating to the carotid arteries and delayed carotid upstroke were 12.4 and 6.3, respectively. Holosystolic murmur and grade 3 murmur had a LR+ of 2.6. The evaluation of the signs was performed by a single investigator.

Munt et al. (11) evaluated 123 asymptomatic subjects. Unlike our study, peak aortic jet velocity was 2.5 m/s or greater in all the patients. Physical examination was performed by a single investigator. Severe aortic stenosis was defined with a peak aortic jet velocity of 4 m/s or greater.

The sensitivity and specificity for grade 3 murmur or greater were quite different from those found in our study, but very similar for grade 2 murmur, emphasizing the evidence of poor agreement in the Levine scale.

The authors did not find any combination of variables with acceptable values of sensitivity and specificity.

Etchells et al. (12) reviewed studies evaluating physical signs of aortic stenosis. Most of these stud-

ies used cardiac catheterization as the gold standard for determining the severity of aortic stenosis, while, nowadays, Doppler echocardiography is the method of choice. Although interobserver variability of physical examination signs was not reported, the agreement among cardiologists to assess heart murmurs (not only for aortic stenosis) was established. Similar to our study, the kappa coefficient was low both to determine absence versus presence of murmur (kappa 0.3) as for the comparison of murmur absence/grade 1 versus grade 2-4 (kappa 0.29). These data seem to indicate that a diagnostic strategy based only on murmur intensity is rather imprecise (scarcely repeatable) and hence, it is preferable to evaluate also other signs with better agreement.

Kuperstein et al. also evaluated the physical determinants of systolic murmur intensity in aortic stenosis, (13) and found that the perceived loudness of the murmur is the complex consequence of multiple factors (pressure gradient, transvalvular flow and body mass index). This may explain the lack of diagnostic accuracy of murmur intensity.

Our findings provide further information.

According to our study, if only the intensity of the murmur is evaluated, a grade 3 or 4/6 murmur could identify most patients with SAS at the expense of low specificity and bearing in mind its scarce repeatability. Thus, it is not recommended to rely only on murmur intensity for patient screening, as it is very unlikely that other examiners will consider the same intensity evaluated by us.

However, the score obtained by evaluating S1 and S2 duration, murmur intensity and the presence of pulsus parvus et tardus had the best area under the curve and is built with acceptably accurate signs.

Among these signs, decreased S1 is rarely mentioned in aortic stenosis but has been recognized for a long time. (14) The mechanism is not clear but may be due to increased left ventricular end-diastolic pressure with less excursion of the mitral valve in early systole. Also, a holosystolic murmur can mask S1 perception.

Other scores have been published (15) but with significant methodological differences; thus, they cannot be compared with our study.

The final interpretation of all the clinical examination signs represents the summary of integrating all the information. Overall, physical examination in SAS has high specificity with low sensitivity.

Ethical considerations

The protocol was reviewed and approved by the Institutional Ethical Board.

Study limitations

Our study was not designed for evaluating special situations, as patients with low ejection fraction, other significant valvular diseases, valvular prostheses or paradoxical low-flow, low-gradient SAS. Our findings

should not be extrapolated to these patients.

Recent investigations (16-18) have demonstrated that hypertension may affect not only the estimation of aortic stenosis severity (by echocardiography or cardiac catheterization), but also the physical examination findings. The data of our study should only be applied to patients with controlled blood pressure values.

CONCLUSIONS

Physical examination findings for the diagnosis of SAS have low sensitivity but adequate specificity.

Interobserver agreement for the different clinical signs of severity is, at least, moderately good.

A simple score obtained by physical examination and adequate repeatability can be used to identify patients with SAS.

Conflicts of interest

None declared

(See author's conflicts of interest forms in the web / Supplementary Material)

REFERENCES

1. Eveborn GW, Schirmer H, Heggelund G, Lunde P, Rasmussen K. The evolving epidemiology of valvular aortic stenosis. the Tromsø study. *Heart* 2013;99:396-400. <http://doi.org/2rg>
2. Faggiano P, Antonini-Canterin F, Baldessin F, Lorusso R, D'Aloia A, Cas LD. Epidemiology and cardiovascular risk factors of aortic stenosis. *Cardiovasc Ultrasound* 2006;4:27. <http://doi.org/2rg>
3. Lang RM, Bierig M, Devereux RB, Flachskampf FA, Foster E, Pellikka PA, et al. Recommendations for chamber quantification. *Eur J Echocardiogr* 2006;7:79-108. <http://doi.org/bpjpd>
4. Baumgartner H, Hung J, Bermejo J, Chambers JB, Evangelista A, Griffin BP, et al. Echocardiographic assessment of valve stenosis: EAE/ASE recommendations for clinical practice. *J Am Soc Echocardiogr* 2009;22:1-23. <http://doi.org/cf47k7>
5. Vahanian A, Alfieri O, Andreotti F, Antunes MJ, Barón-Esquivias G, Baumgartner H, et al. Guidelines on the management of valvular heart disease (version 2012). The Joint Task Force on the Management of Valvular Heart Disease of the European Society of Cardiology (ESC) and the European Association for Cardio-Thoracic Surgery (EACTS). *Eur Heart J* 2012;33:2451-96. <http://doi.org/f2z7g6>
6. Bonow RO, Carabello BA, Chatterjee K, de Leon AC Jr, Faxon DP, Freed MD, et al. ACC/AHA 2006 guidelines for the management of patients with valvular heart disease: a report of the American College of Cardiology/American Heart Association Task Force on Practice Guidelines (writing Committee to Revise the 1998 guidelines for the management of patients with valvular heart disease) developed in collaboration with the Society of Cardiovascular Anesthesiologists endorsed by the Society for Cardiovascular Angiography and Interventions and the Society of Thoracic Surgeons. *J Am Coll Cardiol* 2006;48:e1-148. <http://doi.org/b8q4ms>
7. Nishimura RA, Otto CM, Bonow RO, Carabello BA, Erwin JP 3rd, Guyton RA, et al. 2014 AHA/ACC Guideline for the Management of Patients With Valvular Heart Disease: Executive Summary: A Report of the American College of Cardiology/American Heart Association Task Force on Practice Guidelines. *J Am Coll Cardiol* 2014;63:2438-88. <http://doi.org/f2r556>
8. Aronow WS, Kronzon I. Correlation of prevalence and severity of valvular aortic stenosis determined by continuous-wave. *Am J Cardiol* 1987;60:399-401. <http://doi.org/bfqnxw>
9. Aronow WS, Kronzon I. Prevalence and severity of valvular aortic stenosis determined by Doppler echocardiography and its association with echocardiographic and electrocardiographic left ventricular hypertrophy and physical signs of aortic stenosis in elderly patients. *Am J Cardiol* 1991;67:776-7. <http://doi.org/c63rgt>
10. McGee S. Etiology and diagnosis of systolic murmurs in adults. *Am J Med* 2010;123:913-21. <http://doi.org/bfjvge>
11. Munt B, Legget ME, Kraft CD, Miyake-Hull CY, Fujioka M, Otto CM. Physical examination in valvular aortic stenosis: correlation with stenosis severity and prediction of clinical outcome. *Am Heart J* 1999;137:298-306. <http://doi.org/dg6fzk>
12. Etchells E, Bell C, Robb K. Does this patient have an abnormal systolic murmur? *JAMA* 1997;277:564-71. <http://doi.org/cnw8w8>
13. Kuperstein R, Feinberg MS, Eldar M, Schwammenthal E. Physical determinants of systolic murmur intensity in aortic stenosis. *Am J Cardiol* 2005;95:774-6. <http://doi.org/dbcvpt>
14. Braunwald E. Heart Disease: A Textbook of Cardiovascular Medicine, 6th edition. p. 1676.
15. Etchells E, Glenns V, Shadowitz S, Bell C, Siu S. A bedside clinical prediction rule for detecting moderate or severe aortic stenosis. *J Gen Intern Med* 1998;13:699-704. <http://doi.org/dxmn5q>
16. Little SH, Chan KL, Burwash IG. Impact of blood pressure on the Doppler echocardiographic assessment of severity of aortic stenosis. *Heart* 2007;93:848-55. <http://doi.org/djz78n>
17. Kadem L, Dusmenil JG, Rieu R, Durand LG, Garcia D, Pibarot P. Impact of systemic hypertension on the assessment of aortic stenosis. *Heart* 2005;91:354-61. <http://doi.org/c72s5k>
18. Eleid MF, Nishimura RA, Sorajja P, Borlaug BA. Systemic hypertension in low-gradient severe aortic stenosis with preserved ejection fraction. *Circulation* 2013;128:1349-53. <http://doi.org/2rh>