

Paradoxical Low-Gradient Severe Aortic Stenosis. Solving the Mystery

Estenosis aórtica grave con bajo flujo paradójico. Aclarando el misterio

ARTURO EVANGELISTA, LAURA GALIAN

As population survival has increased, aortic stenosis (AS) has become one of the most frequent indications of cardiac surgery. The ESC/AHA guidelines consider that echocardiography is the standard means for evaluation of aortic stenosis (AS) severity and have recommended to classify severe aortic stenosis as aortic valve area (AVA) $<1 \text{ cm}^2$ or AVA index $<0.6 \text{ cm}^2/\text{m}^2$ and mean pressure gradient $>40 \text{ mm Hg}$ in the presence of normal ventricular function (EF $\geq 50\%$). The primary hemodynamic parameter recommended in the algorithm for clinical decision-making is AVA because it is relatively flow independent. The presence of symptoms in severe AS is a Class IB indication of surgery. Therefore, the adequate estimation of the severity of AS is crucial, as in elderly patients the cause of symptoms is not easy to define due to the presence of other conditions that may cause dyspnea or limit their physical activity. Since Hachicha and Pibarot (1) published in 2007 that the survival of patients with paradoxical low-flow, low-gradient (LFLG) severe AS and EF $\geq 50\%$ was lower than that of the rest of the patients with severe AS, several studies have shown controversial results in the outcome of this condition. Lancellotti et al (2) confirmed the adverse outcome of this entity, although it represented only 7% of severe AS in their series. On the other hand, Jander et al. and Tribouilloy et al. did not notice increase in primary aortic events or cardiovascular mortality in a large series of severe symptomatic AS where 29% of patients presented with LFLG, and they concluded that they were indeed moderate AS, (3) questioning the benefit of surgical treatment. (4)

UNDERESTIMATION OF AORTIC VALVE AREA CALCULATED BY THE CONTINUITY EQUATION

As evidenced by Lombardero et al. in an elegant article published in this issue of the Journal, (5) one of the main problems is the systematic underestimation

of the left ventricular outflow tract (LVOT) area calculated from the diameter determined in the longitudinal plane by two-dimensional echocardiography. Although the continuity equation assumes circular areas, it is well established that the aortic annulus and the outflow tract are not circular. Since the aortic annulus has been systematically analyzed for the indication of TAVI, it has been demonstrated that transthoracic echocardiography usually measures the LVOT minimal diameter of the oval section. Three-dimensional transesophageal echocardiography (3D TEE) has been shown to underestimate LVOT area by 20% or more in patients with severe AS, thus conditioning a significant underestimation of AVA (Lombardero et al.). Similar data have been reported using magnetic resonance imaging or computed tomography scan. (6) The use of LVOT area obtained by magnetic resonance imaging instead of using LVOT diameter by echocardiography significantly improves the correlation between the stroke volume calculated by both methods. (7) In the study by Lombardero et al, the three patients with LFLG (17% of the series) were recategorized as normal flow and low gradient, with different prognostic implications.

One of the basic principles of Doppler echocardiography is that every cross-sectional area produces changes in flow velocity; thus, flow volume is obtained by multiplying the velocity-time integral by the cross-sectional area at the same level. In this sense, Lombardero et al. measure LVOT at 5 mm of the aortic annulus. Although this measurement can be more adequate, its reproducibility is still unknown. In any case, it is hard to assume that, in clinical practice, decision-making in AS with AVA $<1 \text{ cm}^2$ is based on the dichotomy of stroke volume $<$ or $>35 \text{ ml/m}^2$ calculated by Doppler echocardiography since there is sufficient evidence that stroke volume is frequently underestimated. (8)

Rev Argent Cardiol 2015;83:279-281. <http://dx.doi.org/10.7775/rac.v83.i4.6729>

SEE RELATED ARTICLE: Rev Argent Cardiol 2015;83:326-332. <http://dx.doi.org/10.7775/rac.v83.i4.5689>

Address for reprints: Arturo Evangelista - Servicio de Cardiología, Hospital Vall d'Hebron, Passeig de la Vall d'Hebron 119-129, 08035 Barcelona, España - e-mail: aevangel@vhebron.net

SEVERE OR MODERATE-SEVERE AORTIC STENOSIS

Several studies question the value of AVA $< 1 \text{ cm}^2$ as an adequate cut-off point to categorize severe AS. In fact, Carabello demonstrated that mean a pressure gradient of 40 mm Hg correlates with an AVA of 0.8 cm^2 in most cases. (9) Later, Minners et al. confirmed these data in a large series of patients with AS evaluated by cardiac catheterization, (10) affecting 30% of the inconsistencies of their sample. Similarly to the results of Carabello (9) an AVA of 1 cm^2 corresponded to a mean pressure gradient of 22.8 mm Hg. Conversely, a mean pressure gradient of 40 mmHg corresponded to an AVA of 0.75 cm^2 and a maximal velocity of 4.0 m/s to an AVA of 0.82 cm^2 . (11) These data suggest that an AVA between 0.80 cm^2 and 1 cm^2 may correspond to moderate AS in most cases.

The estimation of AVA indexed by body surface area is essential in patients with small body surface area. The updated guidelines consider a cut-off point of $0.6 \text{ cm}^2/\text{m}^2$ to define severe AS. However, an indexed AVA of $0.5 \text{ cm}^2/\text{m}^2$ is a more appropriate cut-off point in some series. (12)

IMPLICATIONS IN CLINICAL PRACTICE

In the presence of paradoxical low flow severe AS, the first approach should be the evaluation of aortic valve opening with two-dimensional echocardiography or early peaking of the ascending aorta flow. Stress echocardiography is useful but it cannot be always used in elderly patients. From a practical point of view, an AVA $< 0.8 \text{ cm}^2$ or an indexed AVA $< 0.5 \text{ cm}^2/\text{m}^2$ has high specificity for the diagnosis of severe AS. In patients with AVA between 0.8 cm^2 and 1 cm^2 and uncertain symptoms,

other parameters, as afterload (Z_{va}) and left ventricular global strain should be evaluated. (13) In these cases, evaluation of anatomic valve opening, quantification of valve leaflet calcification, heart failure biomarkers and evaluation of the hemodynamic response to stress may be useful. Of note, the study by Lombardero et al. does not provide information on anatomic AVA planimetry with 3D TEE, but other studies have suggested its usefulness. (14) Computed tomography, in addition to offering LVOT and AVA planimetry, as the techniques previously mentioned, provides information about aortic valve calcification load (15) (Figure1).

Low-flow, low-gradient severe aortic stenosis has specific pathophysiological mechanisms and implies an adverse outcome. However, in most cases the diagnosis of this entity corresponds to methodological errors in calculating left ventricular stroke volume or to moderate-severe AS. Further studies comparing computed tomography scan and magnetic resonance imaging versus 3D TEE are necessary to determine the best method to avoid underestimating LVOT, particularly in cases with AVA between 0.8 cm^2 and 1 cm^2 . It is still necessary to confirm if an AVA between 0.8 cm^2 and 1 cm^2 corresponds to moderate AS or severe AS. Meanwhile, clinicians should integrate this information rather than basing their decisions on cut-off points of scarcely consistent parameters for an adequate management of patients.

Conflicts of interest

None declared.

(See authors' conflicts of interest forms in the website/Supplementary material).

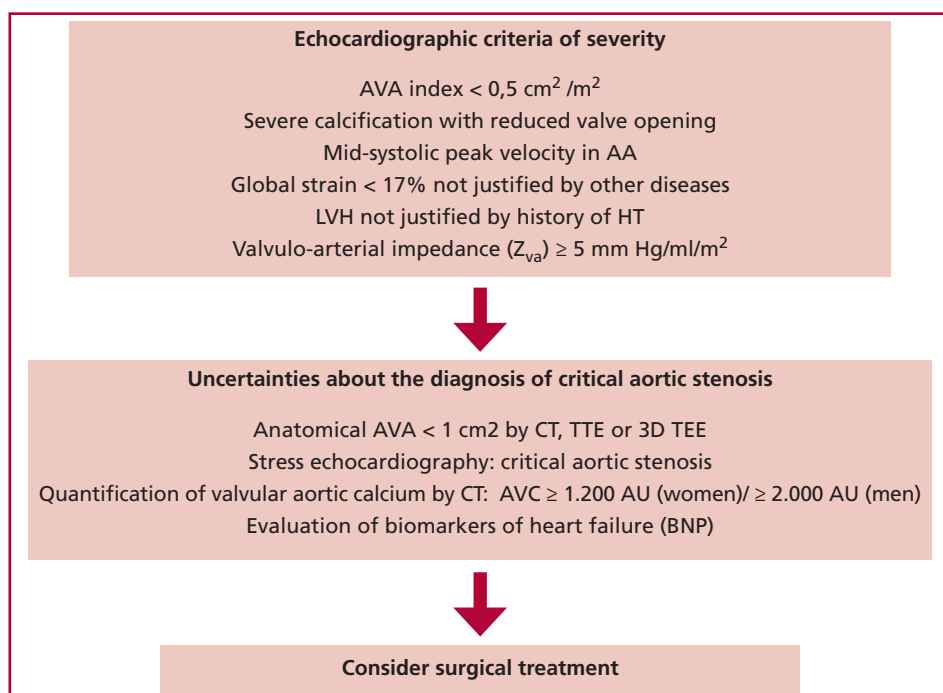


Fig. 1. Algorithm for the diagnosis of aortic stenosis patients with aortic valve area between 0.75 cm^2 and 1 cm^2 , mean pressure gradient $< 40 \text{ mm Hg}$ and ejection fraction $> 50\%$. AVA: Aortic valve area. AA: Ascending aorta. LVH: Left ventricular hypertrophy. HT: Hypertension. CT: Computed tomography. TEE: Transesophageal echocardiogram. 3D: Three-dimensional. AVC: Aortic valve calcium. BNP: B-type natriuretic peptide.

REFERENCES

1. Hachicha Z, Dumesnil JG, Bogaty P, Pibarot P. Paradoxical low-flow, low-gradient severe aortic stenosis despite preserved ejection fraction is associated with higher afterload and reduced survival. *Circulation* 2007;115:2856-64. <http://doi.org/fgrqp7>
2. Lancellotti P, Magne J, Donal E, Davin L, O'Connor K, Rosca M, et al. Clinical outcome in asymptomatic severe aortic stenosis: insights from the new proposed aortic stenosis grading classification. *J Am Coll Cardiol* 2012;59:235-43. <http://doi.org/fzrdfc>
3. Jander N, Minners J, Holme I, Gerds E, Boman K, Brudi P, et al. Outcome of patients with low-gradient "severe" aortic stenosis and preserved ejection fraction. *Circulation* 2011;123:887-95. <http://doi.org/c2sgd9>
4. Tribouilloy C, Rusinaru D, Maréchaux S, Castel AL, Debry N, Maizel J, et al. Low-gradient, low-flow severe aortic stenosis with preserved left ventricular ejection fraction: characteristics, outcome, and implications for surgery. *J Am Coll Cardiol* 2015;65:55-66. <http://doi.org/f2x24t>
5. Lombardero M, Henquin R, Perea G, Tinetti M. Eco 3D transesofágico en la estenosis aórtica con bajo flujo/bajo gradiente paradójico. *Rev Argent Cardiol* 2015;83:326-332.
6. Doddamani S, Grushko MJ, Makaryus AN, Jain VR, Bello R, Friedman MA, et al. Demonstration of left ventricular outflow tract eccentricity by 64-slice multi-detector CT. *Int J Cardiovasc Imaging* 2009;25:175-81. <http://doi.org/cjzqpf>
7. Chin CW, Khaw HJ, Luo E, Tan S, White AC, Newby DE, et al. Echocardiography underestimates stroke volume and aortic valve area: implications for patients with small-area low-gradient aortic stenosis. *Can J Cardiol* 2014;30:1064-72. <http://doi.org/5kt>
8. Evangelista A, García-Dorado D, García del Castillo H, González-Alujas T, Soler-Soler J. Cardiac index quantification by Doppler ultrasound in patients without left ventricular outflow tract abnormalities. *J Am Coll Cardiol* 1995;25:710-6. <http://doi.org/cfr36f>
9. Carabello BA. Clinical practice. Aortic stenosis. *N Engl J Med* 2002;346:677-82. <http://doi.org/cztg5j>
10. Minners J, Allgeier M, Gohlke-Baerwolf C, Kienzle RP, Neumann FJ, Jander N. Inconsistent grading of aortic valve stenosis by current guidelines: haemodynamic studies in patients with apparently normal left ventricular function. *Heart* 2010;96:1463-8. <http://doi.org/b883fm>
11. Minners J, Allgeier M, Gohlke-Baerwolf C, Kienzle RP, Neumann FJ, Jander N. Inconsistencies of echocardiographic criteria for the grading of aortic valve stenosis. *Eur Heart J* 2008;29:1043-8. <http://doi.org/c8sczs>
12. Jander N, Gohlke-Bärwolf C, Bahlmann E, Gerds E, Boman K, Chambers JB, et al. Indexing aortic valve area by body surface area increases the prevalence of severe aortic stenosis. *Heart* 2014;100:28-33. <http://doi.org/f23m9n>
13. Adda J, Mielot C, Giorgi T, Cransac F, Zirphile X, Donal E, et al. Low-flow, low-gradient severe aortic stenosis despite normal ejection fraction is associated with severe left ventricular dysfunction as assessed by speckle-tracking echocardiography: a multicenter study. *Circ Cardiovasc Imaging* 2012;5:27-35. <http://doi.org/fdnmsh>
14. González-Cánovas C, Muñoz-Esparza C, Oliva MJ, González-Carrillo J, López-Cuenca A, Saura D, et al. Severe aortic valve stenosis with low-gradient and preserved ejection fraction: a misclassification issue? *Rev Esp Cardiol (Engl Ed)* 2013;66:255-60. <http://doi.org/f2ffpw>
15. Clavel MA, Messika-Zeitoun D, Pibarot P, Aggarwal SR, Malouf J, Araoz PA, et al. The complex nature of discordant severe calcified aortic valve disease grading: new insights from combined Doppler echocardiographic and computed tomographic study. *J Am Coll Cardiol* 2013;62:2329-38. <http://doi.org/f2qrfx>