

## Acute Coronary Syndrome Secondary to Anomalous Origin of the Left Coronary Artery

*Síndrome coronario agudo secundario a origen anómalo de la arteria coronaria izquierda*

ULISES GODOY, JUAN MEDRANO, MIGUEL CURONE

The anomalous origin of coronary arteries can occur in 0.37% of coronary angiographies. They usually have no clinical impact, but can cause angina, myocardial infarction, heart failure, or sudden death. (1) These are images of a 47 year-old woman, smoker, who was admitted to the Cardiology Service due to non-ST-segment-elevation coronary syndrome. Coronary angiography showed coronary arteries without significant lesions, with anomalous origin of the left coronary artery (LCA) from the right contralateral sinus of Valsalva (Figure 1).

A multislice computed tomography coronary angiography with iodine contrast was performed to establish the course of the LCA, revealing a single coronary ostium in the right coronary sinus giving origin to a short coronary vessel, which in turn divided into the right coronary artery and the left main coronary artery. The latter has a pre-arterial course, which usually gives rise to the anterior descending and circumflex arteries. Figure 2 shows the coronary tree with no atherosclerotic lesions. Since she had a positive clinical outcome, a gated myocardial perfusion SPECT was then performed showing no evidence of myocardial ischemia, adequate post-stress left ventricular function with ejection fraction of 58% and without regional ventricular wall motion abnormalities. Conservative treatment and follow-up at the Cardiology Service was decided.

While diagnosis is usually made through conventional angiography, other diagnostic techniques, such as transesophageal echocardiography, magnetic resonance imaging or computed tomography, can be used to accurately determine the course of coronary artery anomalies. (2) Different hypotheses have been posed to account for this phenomenon: expansion of the roots of both the aortic and pulmonary trunk during systole could produce a compression of the anomalous aortic and pulmonary trunk, or excessive angulation in the origin of the anomalous coronary artery could affect the ostial lumen due to aortic root dilatation. (3) The therapeutic approach should be tailored for each individual case. In case of severe ischemia, the approach should be aggressive (surgical treatment), mainly in young patients, due to the risk of sudden death. (4)

### Conflicts of interest

None declared (See authors' conflict of interest forms in the web/ Supplementary Material).

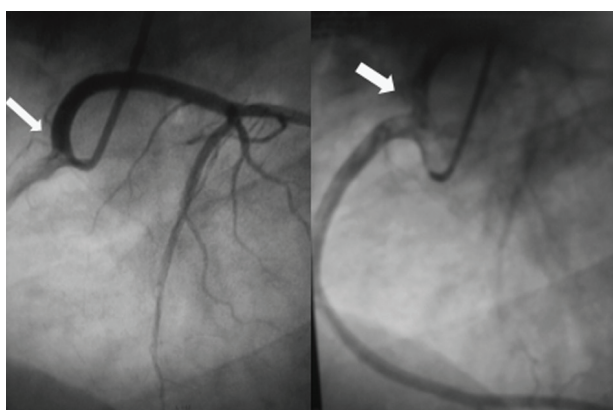


Fig. 1. Coronary angiography. Anomalous origin of the left coronary artery from the right contralateral sinus of Valsalva.

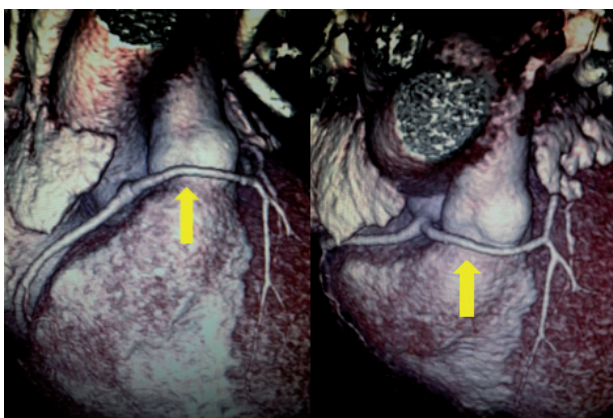


Fig. 2. Multislice computed tomography coronary angiography showing long vessel left coronary trunk following a prepulmonary course

### REFERENCES

1. Iníguez A, Macaya C, Alfonso F, San Román J, Goicolea J, Zarco P. Anomalías congénitas del origen de las arterias coronarias: un reto diagnóstico. *Rev Esp Cardiol* 1991;44:161-7.
2. Angelini P, Velasco J, Flamm S. Coronary anomalies: Incidence. Pathophysiology, and clinical relevance. *Circ* 2002;105:2449-54. <http://doi.org/bh8phc>
3. Barth C, Roberts W. Left main coronary artery originating from the right sinus of Valsalva and coursing between the aorta and pulmonary trunk. *J Am Coll Cardiol* 1986;7:366-73. <http://doi.org/ddnc3c>
4. García J, González-Juanetey J, Amaro A, Amaro Cendón A, Iglesias Carreño C, Castelo Fuentes V y cols. Anomalías congénitas del origen de las arterias coronarias. Aspectos diagnósticos y terapéuticos. *Rev Esp Cardiol* 1994;47:251-4.

REV ARGENT CARDIOL 2016;84:152. <http://dx.doi.org/10.7775/rac.v84.i2.7047>

Address for reprints: Dr. Ulises Godoy - Av. Pueyrredón 1461 - (1118) Buenos Aires, Argentina - Tel. (011) 5239-6071 - e-mail: ulisesgodoy31@gmail.com

Clínica y Maternidad Suizo Argentina - Department of Cardiology and Intensive Care Unit Buenos Aires, Argentina