

# Evidence of Early Cardiomyopathy with Strain in Chagas Disease

## *Evidencia de miocardiopatía incipiente con strain en la enfermedad de Chagas*

MATILDE B. DEL CAMPO CONTRERAS<sup>†</sup>, GRACIELA ROUSSE<sup>†</sup>, MARCELA C. SUN, CARLOS R. KILLINGER<sup>MTSAC</sup>, GUSTAVO CABREJOS, SANDRA FERRADAS, MÁXIMO SENESI

### ABSTRACT

**Background:** In Chagas' disease, cardiomyopathy is the most severe affection produced by this parasitic disease; its slow progression has led to several investigations in search of parameters capable of detecting incipient myocardial damage. Currently, the incorporation of strain by speckle tracking echocardiography opens a new horizon.

**Objective:** The aim of this study was to investigate the role of two-dimensional echocardiography in Chagas disease and in the detection of incipient cardiomyopathy.

**Methods:** A cross-sectional study was performed between December 2009 and March 2011, including 93 patients with Chagas disease. Forty-five patients were men and mean age was  $46 \pm 12$  years. The patients were divided into three groups (G): G1 (n=40) without demonstrable heart disease), G2 (n=17) with abnormal electrocardiogram and G3 (n=36) with cardiomyopathy. A control group consisted of 35 subjects; 19 were men and mean age was  $40 \pm 10$  years. Doppler echocardiography was performed to evaluate left ventricular diameters, left atrial area, left ventricular ejection fraction (Simpson), mitral annular plane systolic excursion and tricuspid annular plane systolic excursion. Mitral inflow pattern evaluated E wave, A wave, mitral E wave deceleration time and E/A ratio. Pulsed tissue Doppler imaging was used to measure and compare velocities at the lateral mitral annulus and tricuspid annulus (E' wave, A' wave, E'/A' ratio and S' wave) and global and segmental longitudinal peak systolic strain.

**Results:** Global longitudinal peak systolic strain correlated with mitral annular plane systolic excursion (r: 0.75) in the pool of patients with Chagas disease. Segmental longitudinal peak systolic strain differentiated two or more abnormal segments (value below -12%) in 10 patients of the group without demonstrable heart disease. This subgroup (n=10) had lower values of global longitudinal peak systolic strain (-19.78% vs. -22.28%; p=0.009), lower E'/A' ratio in the mitral annulus ( $1.23 \pm 0.59$ ; p=0.021) and tricuspid annulus ( $0.73 \pm 0.3$ ; p=0.019), with inverted E'/A' ratio in the tricuspid annulus compared with the rest of the group (n=30).

**Conclusions:** Global longitudinal peak systolic strain correlated with mitral annular plane systolic excursion. Segmental longitudinal peak systolic strain differentiated a subpopulation in the group without demonstrable heart disease with abnormal segments, low values of global longitudinal peak systolic strain and biventricular diastolic dysfunction by pulsed tissue Doppler imaging. The clinical value of this finding requires longitudinal follow-up.

**Key words:** Echocardiography, methods - Chagas Cardiomyopathy - Chagas Disease - Echocardiography, Color Doppler - Diastolic Heart Failure

### RESUMEN

**Introducción:** En la enfermedad de Chagas, la miocardiopatía es la afección más grave provocada por esta parasitosis; su lenta evolución ha llevado a numerosas investigaciones en búsqueda de parámetros que permitan detectar daño miocárdico incipiente. Actualmente, la incorporación del strain por speckle tracking abre un nuevo horizonte.

**Objetivo:** Investigar el rol del strain bidimensional en la enfermedad de Chagas y en la detección de miocardiopatía incipiente.

**Material y métodos:** Estudio transversal, realizado de diciembre de 2009 a marzo de 2011, en el que se incluyeron 93 pacientes con enfermedad de Chagas, 45 hombres, edad promedio  $46 \pm 12$  años, que se dividieron en tres grupos (G): G1 (n = 40) sin cardiopatía demostrada, G2 (n = 17) con electrocardiograma anormal y G3 (n = 36) con miocardiopatía. Se conformó un grupo control de 35 sujetos, 19 hombres, edad promedio de  $40 \pm 10$  años. Por eco-Doppler cardíaco se evaluaron: diámetros del ventrículo izquierdo, área auricular izquierda, fracción de eyección del ventrículo izquierdo (Simpson), excursión sistólica del plano de los anillos mitral y tricuspídeo. Por flujograma mitral: ondas E y A, tiempo de desaceleración de la onda E, relación E/A. Entre el grupo control y el grupo sin cardiopatía demostrada se compararon el Doppler pulsado tisular de los anillos mitral y tricuspídeo (ondas E', A', relación E'/A' y onda S') y el strain longitudinal pico sistólico global y segmentario.

**Resultados:** El strain longitudinal pico sistólico global se correlacionó con la excursión sistólica del plano del anillo mitral (r: 0,75) en los pacientes con enfermedad de Chagas tomados en conjunto. El análisis del strain longitudinal pico sistólico segmentario discriminó dos o más segmentos anormales (valor inferior -12%) en 10 pacientes del grupo sin cardiopatía demostrada. Este subgrupo (n=10) mostró inferior strain longitudinal pico sistólico global (-19,78% vs. -22,28%; p = 0,009), menor valor E'/A' en los anillos

REV ARGENT CARDIOL 2016;84:323-329. <http://dx.doi.org/10.7775/rac.v84.i4.8715>

Received: 05/16/2016 – Accepted: 06/25/2016

Address for reprints: Dra. Matilde B. del Campo Contreras - Campichuelo 272 PB -(1405) CABA - e-mail: matildelcampo@yahoo.com.ar

Hospital General de Agudos "Carlos G. Durand" - CABA  
<sup>MTSAC</sup> Full Member of the Argentine Society of Cardiology

<sup>†</sup>To apply as Full member of the Argentine Society of Cardiology

mitral ( $1,23 \pm 0,59$ ;  $p = 0,021$ ) y tricuspídeo ( $0,73 \pm 0,3$ ;  $p = 0,019$ ), con inversión de la relación E'/A' tricuspídea respecto del resto del grupo ( $n = 30$ ).

**Conclusiones:** El strain longitudinal pico sistólico global se correlacionó con la excursión sistólica del plano del anillo mitral. El strain longitudinal pico sistólico segmentario discriminó en el grupo sin cardiopatía demostrada una subpoblación con segmentos anormales, valores inferiores de strain longitudinal pico sistólico global y disfunción diastólica biventricular por Doppler pulsado tisular; la implicación clínica de este hallazgo requiere seguimiento longitudinal.

**Palabras clave:** Ecocardiografía, métodos - Miocardiopatía chagásica - Enfermedad de Chagas - Eco-Doppler cardíaco - Insuficiencia Cardíaca Diastólica

## Abbreviations

<b>BNP</b>	B-type natriuretic peptide	<b>EF</b>	Ejection fraction
<b>ICC</b>	Intraclass correlation coefficient	<b>GWDHD</b>	Group without demonstrable heart disease
<b>LVDD</b>	Left ventricular diastolic diameter	<b>GLPSS</b>	Global longitudinal peak systolic strain
<b>TDI</b>	Tissue Doppler imaging	<b>SLPSS</b>	Segmental longitudinal peak systolic strain
<b>LVSD</b>	Left ventricular systolic diameter.	<b>EDT</b>	Mitral E wave deceleration time
<b>ECG</b>	Electrocardiogram	<b>RV</b>	Right ventricular
<b>MAPSE</b>	Mitral annular plane systolic excursion	<b>LV</b>	Left ventricular
<b>TAPSE</b>	Tricuspid annular plane systolic excursion		

## INTRODUCTION

Chagas disease is the Latin American endemic parasitic disease with the highest morbidity and mortality. Its etiological agent, *Trypanosoma Cruzi*, has different pathways of human transmission: vector-borne, transplacental and transfusion transmission. Oral transmission is less common (by contamination of food or juices) and was reported for the first time in 1965. (1) Vector-borne transmission is the most common form and the blood-sucking insect host, *Triatoma infestans*, finds a favorable habitat in deprived conditions. Control of Chagas disease is considered a serious public health problem. Although its prevalence has decreased over the past two decades, the World Health Organization (WHO) has recently reported (2016) that about 6 million to 7 million people worldwide are estimated to be infected and only during 2008 11,000 deaths were registered due to Chagas cardiomyopathy. (2) As a consequence of global migration, there are 300,000 persons infected in the United States (3) and 100,000 in Europe. (4)

Cardiomyopathy is, by far, the most severe affection produced by Chagas disease. Most patients with this parasitic disease remain asymptomatic during 10 to 30 years. During this "latency" period of the chronic phase, 30% to 40% of patients develop heart disease. (5, 6) Disease progression is heterogeneous, unpredictable and slow, and mortality is related with the severity of myocardial dysfunction. (7) The pathogenesis of Chagas heart disease is not completely defined and is attributed to different factors: presence of the parasite or parasite antigens in the myocardial tissue and the immune response (mediator of tissue damage and endothelial dysfunction). (8-10) Several investigators, including our group, have analyzed the genetic factors that regulate this immune response using histocompatibility testing methods, but the results have hitherto been inconclusive due to sig-

nificant polymorphism and to the many variables involved. (11, 12)

The 2010 International Consensus on Chagas Disease replaced the terms "indeterminate" and "healthy carrier" of asymptomatic patients during the chronic stage of the disease for "chronic patients without demonstrable pathology", (13) giving importance to the presence of heart disease according to the sensitivity of the diagnostic method used. Previous studies have demonstrated abnormalities in diastolic function, (14) regional wall motion and pulsed tissue Doppler imaging (TDI), (15, 16) and abnormal results in pharmacological stress echocardiography. (17, 18) Biological markers, as B-type natriuretic peptide (BNP) and troponin, (19) in addition to the new technological advances of echocardiography, as two-dimensional strain, aim at detecting incipient myocardial damage. In this sense, speckle-tracking echocardiography is a promising technique. Myocardial deformation can be estimated by longitudinal (predominantly in sub-endocardial fibers) circumferential and radial strain, though circumferential and radial strains require transmural involvement of the myocardial wall analyzed. (20) Taking into account that the subendocardium is the most sensitive myocardial layer to the different types of ischemia (microvascular abnormalities, endothelial dysfunction or vasoconstrictor stimuli in angiographically normal coronary arteries), it is possible that longitudinal strain could be abnormal in the early stages of Chagas cardiomyopathy, as the aforementioned abnormalities may be present in the different stages of the disease.

The aim of this study was to analyze the usefulness of two-dimensional strain by speckle-tracking echocardiography in the chronic stage of Chagas disease and in the identification of incipient myocardial damage in patients without demonstrable heart disease detected by standard echocardiographic parameters.

## METHODS

### Population

Between December 2009 and March 2011, 100 patients with Chagas disease were referred to our laboratory for regular cardiovascular evaluation. The patients came from endemic areas and had at least two serological tests with positive results: indirect immunofluorescence (IIF), enzyme-linked immunosorbent assay (ELISA), and indirect hemagglutination.

All the patients underwent clinical examination, electrocardiogram (ECG) and Doppler echocardiography and were compared with a control group. Patients with the following conditions were excluded: hypertension, coronary artery disease, valvular heart disease, cardiomyopathies, metabolic and toxic disorders, atrial fibrillation, and those with pacemaker implantation or with previous antiparasitic treatment.

Patients were classified into 3 groups and were compared with a control group (35 subjects with mean age of  $40.51 \pm 10.8$  years and negative serology for Chagas disease).

Group 1 involved 43 patients with normal ECG and echocardiography; group without demonstrable heart disease (GWDHD).

Group 2 was composed of 18 patients with normal echocardiogram and abnormal ECG due to the presence of right bundle branch block, left anterior hemiblock, ventricular premature contractions, primary repolarization abnormalities, electrically inactive areas or sinus bradycardia.

Group 3 consisted of 39 patients with abnormal echocardiogram due to regional or global wall motion abnormalities, increased left ventricular (LV) diameters and different levels of systolic dysfunction.

### Doppler echocardiography

Doppler echocardiography was performed with a VIVID 7 ultrasound machine from General Electric Healthcare, using a matrix array transducer M4S (1.7 - 3.4 MHz). The studies were evaluated by two independent observers. The following measurements were estimated: left ventricular diastolic diameter (LVDD), left ventricular systolic diameter (LVSD), fractional shortening, ejection fraction (EF) calculated by Simpson's rule, wall thickness, left atrial area, mitral annular plane systolic excursion (MAPSE) and tricuspid annular plane systolic excursion (TAPSE). E wave, A wave, E/A ratio and mitral E wave deceleration time (EDT) were assessed through mitral inflow velocity. Pulsed TDI evaluated velocities at the lateral mitral annulus (E'm, A'm, E'm/A'm and S'm) and tricuspid annulus (E't, A't, E't/A't and S't). Longitudinal peak systolic strain was evaluated from apical views with a frame rate of 50 to 70 frames per second. The best of 3 cycles was analyzed online using the automated function imaging. (21) Global longitudinal peak systolic strain (GLPSS) was determined as the average of the 16 segments analyzed and was presented as a bull's-eye diagram, and segmental longitudinal peak systolic strain (SLPSS) was defined as that corresponding to each of these segments. The myocardial segments were named following the recommendations of the American Society of Echocardiography. (22)

As the aim of our study was also to evaluate the presence of incipient myocardial damage, and patients in Group 2 and Group 3 had manifestations of Chagas disease cardiomyopathy, mitral inflow velocity, pulsed TDI of the mitral annulus and tricuspid annulus and strain were compared between the control group and Group 1.

### Statistical analysis

Continuous variables are expressed as mean  $\pm$  standard deviation (SD) or median and interquartile range, and categorical variables as percentage. The differences between groups for continuous variables were analyzed using Student's t test or ANOVA, followed by the Bonferroni test or the Mann-Whitney test; the chi square test or Fisher's exact test were used to compare categorical variables. Correlations were analyzed using Pearson's linear correlation coefficient (r). Intraobserver and interobserver variability was estimated using the intraclass correlation coefficient (ICC). A p value  $<0.05$  was considered statistically significant. All the calculations were performed using SPSS 18.0 statistical package (SPSS Inc. 5, Chicago, IL).

The protocol was evaluated and approved by the institutional Ethics Committee.

### Ethical considerations

The protocol was evaluated and approved by the institutional Ethics Committee.

## RESULTS

Among the initial 100 patients, 7 were excluded due to suboptimal ultrasonic window to measure strain (feasibility 94%). The characteristics of the population and echocardiographic results are described in Table 1.

Patients with Chagas disease cardiomyopathy (Group 3) were older (an expected difference considering the long latency period of this disease), had larger ventricular diameters and left atrial area and variable systolic dysfunction reflected by lower MAPSE and EF compared with the other groups ( $p < 0.05$ ) (Table 1). The most common wall motion abnormalities of this group were observed in: apical segment in 13 patients (28%), inferoseptal and inferior segments in 3 patients (6%), other locations (anteroseptal, anterior and anterolateral) in 6 patients (12%) and an apical inferior aneurysm in only 1 patient (2%). Global hypokinesia was present in 22 patients (45%).

There were no significant differences in cardiac diameters and ventricular function between the control group, Group 1 (GWDHD) and Group 2 (abnormal ECG). The analysis of LV diastolic function revealed a non-significant trend toward longer EDT and lower E/A ratio associated with the severity of the groups.

Mitral inflow velocity and pulsed TDI of the mitral annulus were similar in the control group and in the GWDHD. However, pulsed TDI at the level of the tricuspid annulus showed a significant reduction in the E't wave and a significantly lower E't/A't ratio, with inverted E't/A't ratio in 38% of the control group vs. 68% of the GWDHD ( $p=0.007$ ) (Table 2).

### Two-dimensional strain

There was good correlation between GLPSS and MAPSE ( $r$ ; 0.75) in the pool of patients (Figure 1).

When the control group and Group 1 were compared, GLPSS presented lower values without reaching statistical significance. Neither was the analysis of mean SLPSS of each segment significant between both groups. However, SLPSS had abnormal values, below -12%, in 2 or more contiguous segments in 10 patients of Group 1 vs. no abnormal values in the control group ( $p < 0.05$ ). The distribution of segments

**Table 1.** Characteristics of the population and echocardiogram. Controls and patients with Chagas disease

	Controls n=35	Group 1 n=40	Group 2 n=17	Group 3 n=36	p
Age, years	40.51±10.8	40.67±15	45.35±13.5	52.83±12.9	<0.0001
Male sex, n (%)	19 (54)	5 (12)	5 (29)	16 (44)	0.001
HR, bpm	69.48±7.38	66.06±7.68	69.23±10.07	67.11±10.53	ns
LVDD, cm	4.8±0.4	4.7±0.4	4.8±0.5	5.9±1.0	<0.0001
LAA, cm <sup>2</sup>	15.6±2.4	16.6±4.5	16.20±563.8	20.7±6.9	<0.0001
EF, %	63.86±7.09	60.09±8.18	59.08±7.45	37.41±13.61	<0.0001
MAPSE, cm	2.0±0.2	1.8±0.2	1.8±0.2	1.3±13.61	<0.0001
Mitral E/A ratio	1.37±0.38	1.32±0.44	1.26±0.49	1.15±0.66	ns
EDT, ms	211-97±40.7	224.15±54.9	229.56±52.4	230.91±130.07	ns
TAPSE, cm	2.29±0.27	2.27±0.22	2.32±0.48	2.01±0.46	0.002

HR: Heart rate. bpm: Beats per minute. LVDD: Left ventricular diastolic diameter. LAA: Left atrial area. EF: Ejection fraction. MAPSE: Mitral annular plane systolic excursion. Mitral E/A: Mitral inflow velocity ratio. EDT: Mitral E wave deceleration time. TAPSE: Tricuspid annular plane systolic excursion. ns: Non-significant

**Table 2.** Comparison of mitral inflow velocity, pulsed tissue Doppler imaging of the mitral and tricuspid annulus and global longitudinal peak systolic strain. Control Group vs. Group 1.

	Control Group (n=35p)	Group 1 (n=40p)	p
E	0.76±0.16	0.75±0.13	ns
A	0.6±0.23	0.61±0.17	ns
Mitral E/A ratio	1.37±0.38	1.32±0.44	ns
EDT, ms	211±40	224±55	ns
S'm	10.40±2.12	9.65±2.64	ns
E'm	14.37±4.12	13.89±4.15	ns
A'm	9.11±2.65	9.12±2.47	ns
E'm/A'm	1.71±0.73	1.63±0.64	ns
S't	13.03±1.85	12.58±2.20	ns
E't, m/s	14.14±2.29	11.97±3.73	0.007
A't, m/s	12.60±3.11	13.38±3.51	ns
E't/A't	1.19±0.39	0.94±0.34	0.005
Global strain, %	-22.19±2.54	-21.56±2.63	ns

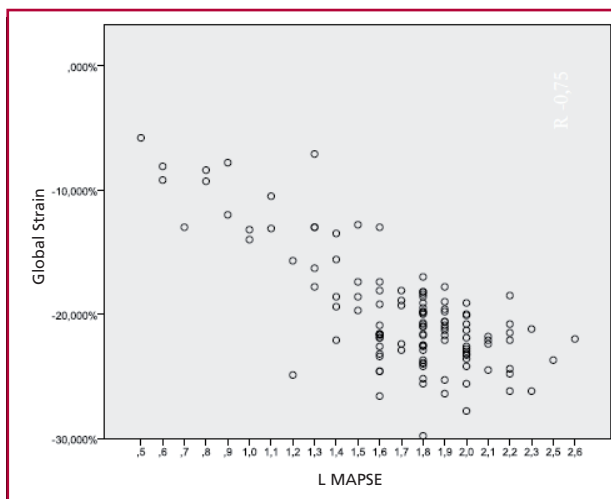
E: E mitral wave. A: A mitral wave. Mitral E/A: E/A ratio of mitral inflow velocity. EDT: Mitral E wave deceleration time. S'm, E'm and A'm: S, E and A waves of mitral annulus pulsed tissue Doppler imaging. S't, E't and A't: S, E and A waves of tricuspid annulus pulsed tissue Doppler.

with abnormal SLPSS was the following: inferior segments 40% (inferoseptal, inferior and inferolateral), anterior segments 40% (anteroseptal, anterior and anterolateral) and apical segments 29% (Figure 2).

The ICC for intraobserver variability was 0.93 and 0.9 for interobserver variability.

#### Results of Group 1 analysis

Patients in Group 1 were divided into two subgroups due to SLPSS ≤ -12% in two or more segments in 10

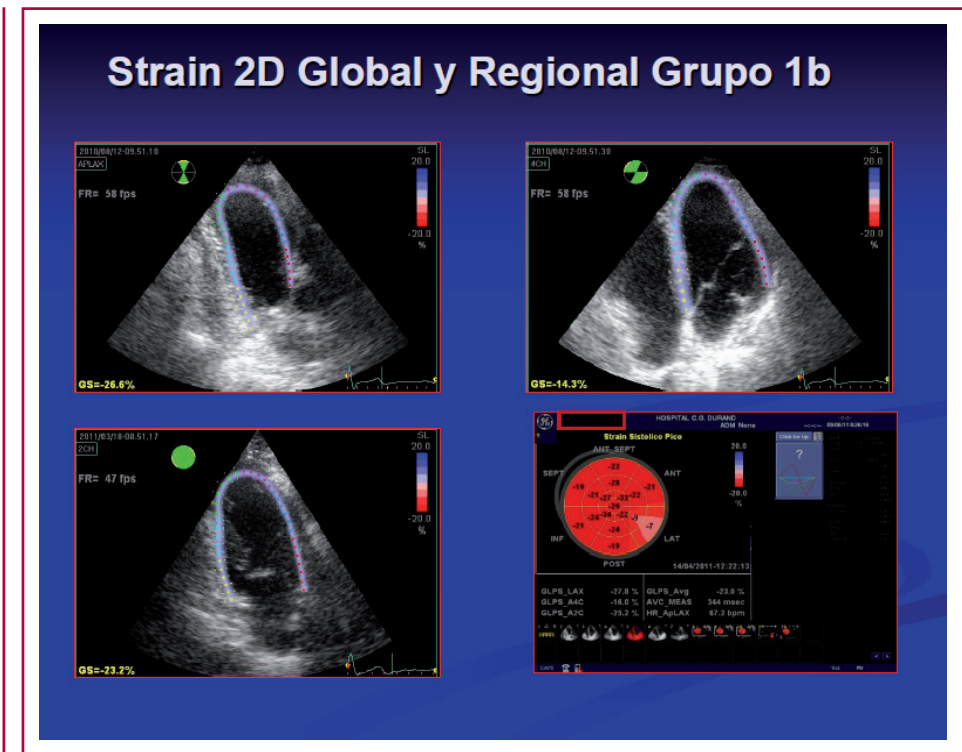
**Fig. 1.** Correlation between global longitudinal peak systolic strain (GLPSS) and mitral annular plane (longitudinal) systolic excursion (MAPSE) ( $r=0.75$ ) in the pool of patients with Chagas disease ( $n=93$ )

patients: 1a (patients with normal segments) and 1b (patients with abnormal segments). Mitral inflow velocity, pulsed TDI of the mitral annulus and tricuspid annulus and strain were compared in these subgroups (Table 3).

In Group 1b, EDT was longer, but did not reach statistical significance while the A wave was significantly increased ( $0.73±0.22$  vs.  $0.58±0.13$ ,  $p=0.013$ ). The E/A ratio of mitral inflow velocity and the E'm/A'm of pulsed TDI at the level of the mitral annulus were significantly decreased. An inverted E't/A't ratio was observed in the pulsed TDI at the level of the tricuspid annulus ( $0.73±0.31$  Group 1b vs.  $1.02±0.33$  Group 1a,  $p=0.005$ ), with a significant reduction of the E't wave ( $9.4±0.96$  cm/s vs.  $12.83±3.91$  cm/s,  $p=0.007$ ).

GLPSS was significantly lower in Group 1b

**Fig. 2.** 2D longitudinal strain by speckle tracking echocardiography obtained from the apical view of a patient in Group 1b. *Upper, left:* Long axis view with normal segmental strain. *Upper, right:* 4-chamber view showing strain values below -12% in the basal anterolateral and mid-anterolateral segments (pink color; see color image in the web). *Lower, left:* 2-chamber view showing normal segmental strain. *Lower, right:* Bull's eye diagram obtained from longitudinal peak systolic strain of each segment and global strain (average of all the segments).



compared with Group 1a ( $-19.78\% \pm 2.4\%$  vs.  $-22.28\% \pm 2.4\%$ ,  $p=0.009$ ). This could explain the lower value of GLPSS seen in patients of the GWDHD (Table 3).

## DISCUSSION

Chagas cardiomyopathy is the most important and severe manifestation of Chagas disease. The main anatomopathological finding is progressive and chronic fibrous myocarditis, and focal myocarditis that occurs even in the indeterminate phase of the disease and becomes more intense while disease progresses. Loss of cardiomyocytes and their replacement by fibrotic tissue predisposes to ventricular arrhythmias and different degrees of diastolic and systolic dysfunction during its progression. (23) Chagas cardiomyopathy produces diastolic dysfunction in both phases of ventricular filling: relaxation is initially impaired with subsequent involvement of chamber compliance as it affects not only myocardial fibers but different components, as the interstitial space, conduction system, autonomic nervous system and vascular integrity. (16)

Considering that Chagas cardiomyopathy develops during decades, the search for any echocardiographic parameter that could warn about its clinical evolution in the chronic stage without demonstrable heart disease, led to multiple research studies with the available tools. In this sense, mitral inflow velocity, pulsed TDI of the mitral annulus (at rest and during dobutamine stress echocardiography) and of the tricuspid annulus were analyzed. (14-19) At present, the incorporation of strain by speckle tracking echocardiography opens a new horizon.

**Table 3.** Comparison of mitral inflow velocity, pulsed tissue Doppler imaging of the mitral and tricuspid annulus and global longitudinal peak systolic strain. Group 1a vs. Group 1b.

	Group 1a (n=30)	Group 1b (n=10)	p
E, m/s	0.77±0.13	0.71±0.11	ns
A, m/s	0.58±0.13	0.73±0.22	0.013
Mitral E/A ratio	1.41±0.43	1.08±0.41	0.04
EDT, ms	214.73±50.87	252.40±59.63	0.059
S'm, cm/s	9.90±2.7	8.90±2.4	ns
E'm, cm/s	14.77±3.78	10.90±3.95	0.09
A'm, cm/s	9±2.62	9.5±2.01	ns
E'm/A'm	1,76±0.61	1.23±0.59	0.021
S't	12.90±2.1	11.60±2.3	ns
E't	12.83±3.91	9.4±0.96	0.001
A't	12.93±2.59	14.70±5.37	ns
E't/A't	1.02± 0.33	0.73±0.31	0.019
GLPSS (%)	-22.28±2.4	-19.78±2.4	0.009

E: E mitral wave. A: A mitral wave. Mitral E/A: E/A ratio of mitral inflow velocity. EDT: Mitral E wave deceleration time. S'm, E'm and A'm : S, E and A waves of mitral annulus pulsed tissue Doppler imaging. S't, E't and A't: S, E and A waves of tricuspid annulus pulsed tissue Doppler. GLPSS: Global longitudinal peak systolic strain.

In our study, diastolic dysfunction, reflected by longer EDT and lower value of the E/A ratio in patients of the GWDHD compared with the control group, was not statistically significant. This finding is similar to the one reported by Pazin-Filho et al. (6) and opposed to that of Cianciulli et al. (14). Other authors,

as García Alvarez et al., (19) found that only half of patients in the undetermined form had this pattern of diastolic dysfunction associated with elevated BNP (>37 pg/ml).

Conversely, the results obtained with pulsed TDI in different investigations are more homogeneous. In our population, the value of the mitral E' wave was lower in the GWDHD, but this reduction was non-significant compared with the control group. Nascimiento et al. (24), identify the mitral E' wave as a useful tool for the follow-up of patients with and without heart disease, and this finding is coincidental with the publications of Migliori et al. (25) and Barros et al. (26)

The evaluation of right ventricular (RV) diastolic function by pulsed TDI of the tricuspid annulus revealed that patients from the GWDHD had lower E' wave and E'/A' ratio compared with the control group (see Table 2). This finding, also reported by Barros et al., (27) indicates that concomitant RV diastolic dysfunction is also present either by ventricular interdependence and/or early damage in the initial stages of the disease. Therefore, RV diastolic function should be assessed as part of the routine evaluation of patients with Chagas heart disease due to its early involvement.

We did not find significant differences in the S' wave measured by pulsed TDI of the mitral annulus in patients with Chagas disease without demonstrable heart disease and the control group, while Barros et al. observed lower values related with the severity of heart disease in baseline conditions. (28) Using dobutamine stress echocardiography, Killinger (17) and Acquatella (18) showed that these patients presented an abnormal contractile response (insufficient increase of S' wave after stress) and chronotropic incompetence.

Considering that diastolic dysfunction precedes or accompanies systolic dysfunction, its presence demands the search for global or segmental contractile abnormalities that might be present but have not been detected by conventional methods. In this sense, speckle-tracking echocardiography is a promising technique.

In our study, GLPSS was lower in patients without demonstrable heart disease but did not reach statistical significance compared with controls. A similar result was reached by Barbosa et al. in 78 patients without symptoms, where GLPSS and global circumferential strain, though lower, were not statistically significant, but segmental analysis showed significant differences in different segments, and global radial and segmental strain were significantly decreased. (29) Similarly, Silva et al. found lower values of radial and longitudinal strain as myocardial involvement increased. (30) Garcia-Alvarez et al. found significantly lower global circumferential strain in patients with more severe myocardial involvement. In this study, global radial strain was significantly lower in the GWDHD compared with controls and radial strain was lower in the LV midinferior segment. (31)

The analysis of SLPSS differentiated two subgroups: one with two or more contiguous abnormal segments (value below -12%) (20) and another with normal values in all the segments. This subgroup with abnormal SLPSS in two or more contiguous segments (predominantly in the inferior and apical segments) evidenced greater biventricular diastolic dysfunction reflected by higher A wave and lower E/A ratio, lower E'm/A'm ratio in pulsed TDI of the mitral annulus and lower E't/A't and E't of the tricuspid annulus (Table 4).

In our study, the good correlation between GLPSS and MAPSE in all the groups of patients with Chagas disease was an additional finding, and this measurement should be reconsidered as it is easily available and reproducible.

The evaluation of strain improved the diagnostic sensitivity to detect contractile abnormalities in all the cases. As only 30% of the patients without demonstrable heart disease will eventually develop cardiomyopathy, it is necessary to investigate the variables that may differentiate this subgroup. Among the GWDHD, we found a group of patients with abnormal segmental longitudinal strain with significantly lower GLPSS associated with biventricular systolic dysfunction. This finding confirms the usefulness of the method in patients with Chagas disease without demonstrable heart disease.

## CONCLUSIONS

Myocardial strain could identify a subgroup of patients without demonstrable heart disease with abnormal segmental longitudinal strain and lower GLPSS that presented associated biventricular diastolic dysfunction. Further clinical research in patients without demonstrable heart disease is necessary to evaluate the outcome and clinical implications of this finding in the progression of cardiomyopathy.

## Acknowledgments

We are grateful to Dr. Stella Maris Luna (in memoriam) for her helpful cooperation in the Chagas disease outpatient clinic at the Cardiology Department, Hospital "Carlos G. Durand"

## Conflicts of interest

None declared. (See authors' conflicts of interest forms in the website/Supplementary material).

## REFERENCES

1. Toso A, Vial F, Galanti N. Transmisión de la enfermedad de Chagas por vía oral. *Rev Med Chile* 2011;139:258-66. <http://doi.org/c9gnjg>
2. <http://www.who.int/mediacentre/factsheets/fs340/es/>
3. Bern C, Montgomery SP. An estimated of the burden of Chagas' disease in the United States. *Clin Infect Dis* 2009;49:e52-4. <http://doi.org/fkd63c>
4. Schumuni GA, Yadon ZE. Chagas disease: A Latin American health problem becoming a world heart problem. *Acta Trop* 2010;115:14-21. <http://doi.org/chhkm8>
5. Prata A. Clinical and epidemiological aspects of Chagas disease. *Lancet Infect Disease* 2001;1:92-100. <http://doi.org/d7kmb>

6. Pazin-Filho A, Romano MM, Gomes Furtado R, de Almeida Filho OC, Schmidt A, Marin-Neto JA, et al. Left ventricular global performance and diastolic function in indeterminate and cardiac forms of Chagas' disease. *J Am Soc Echocardiogr* 2007;20:1338-43. <http://doi.org/b82dhd>
7. WHA. 63/2010/REC/1 Organización Mundial de la Salud. 63.ª Asamblea Mundial de la Salud (Ginebra, 17-21 de mayo de 2010. Resoluciones y decisiones anexos).
8. Viotti R, Vigliano C, Lococo B, Petti M, Bertocchi G, Alvarez MG, et al. [Clinical predictors of chronic chagasic myocarditis progression]. *Rev Esp Cardiol* 2005;58:1037-44. <http://doi.org/ddhqr>
9. Marin-Neto JA, Rassi A Jr. Update on Chagas heart disease on the first centenary of its discovery. *Rev Esp Cardiol* 2009;62:1211-6. <http://doi.org/bg9mc2>
10. Acquatella H, Gómez Mancebo J, Cataliotti F, Puigbó J. Imaging Techniques in the Diagnosis and Prognosis of Chagas Disease. *Rev Argent Cardiol* 2013;81:184-95.
11. Del Campo M, Sun M, Cabrejos G, Rouse G, Killinger C, Bierfast G, et al. Histocompatibilidad en la enfermedad de Chagas: distribución de los alelos HLA Clases I y II en pacientes con y sin miocardiopatía. XXXVIII Congreso de la Sociedad Argentina de Cardiología en CABA, 2012, Abstract 168.
12. García Borrás S, Racca L, Cotorruelo C, Biondi C, Beloscar J, Racca A. Distribution of HLA-DRB1 alleles in Argentinean patients with Chagas' disease cardiomyopathy. *Immunological Investigations* 2009;38:268-75. <http://doi.org/fdxnr2>
13. Clasificación Enfermedad de Chagas. Consenso Internacional Buenos Aires 2010.
14. Cianciulli TF, Lax JA, Saccheri MC, Papantoniou A, Morita LA, Prado NG, et al. Early detection of left ventricular diastolic dysfunction in Chagas' disease. *Cardiovasc Ultrasound* 2006;4:18. <http://doi.org/c5wj2>
15. Barros M, Rocha M, Ribeiro A, Machado F. Doppler tissue imaging to evaluate early myocardium damage in patients with undetermined form of Chagas' disease and normal echocardiogram. *Echocardiography* 2001;18:131-6. <http://doi.org/bj4gbj>
16. Nascimento CA, Gomes VA, Silva SK, Santos CR, Chambela MC, Madeira FS, et al. Left atrial and left ventricular diastolic function in chronic Chagas disease. *J Am Soc Echocardiogr* 2013;26:1424-33. <http://doi.org/bkdn>
17. Killinger C, Lozano D, Castro E, De Rosa M, del Campo M, Lapresa S, et al. Premio farmacológico en la enfermedad de Chagas. Estudio con eco-Doppler. *Rev Argent Cardiol* 2007;75:35-42.
18. Acquatella H, Perez J, Condado JA, Sanchez I. Limited myocardial contractile reserve and chronotropic incompetence in patients with chronic Chagas' disease. *JACC* 1999;33:522-9. <http://doi.org/bd9tk7>
19. Garcia-Alvarez A, Sitges M, Pinazo MJ, Regueiro-Cueva A, Posada E, Poyatos S, et al. Chagas cardiomyopathy: the potential of diastolic dysfunction and brain natriuretic peptide in the early identification of cardiac damage. *P LoS Negl Trop Dis* 2010;4:e826. <http://doi.org/bc88kj>
20. Mor-Avi V, Lang R, Badano L, Belohlavek M, Cardim N, Derumeaux G, et al. Current and evolving echocardiographic techniques for the quantitative evaluation of cardiac mechanics: ASE/EAE Consensus Statement on Methodology and Indications. *J Am Soc Echocardiogr* 2011;24:277-313. <http://doi.org/dkm94m>
21. Amundsen BH, Helle-Valle T, Edvardsen T, Torp H, Crosby J, Lyseggen E, et al. Noninvasive myocardial strain measurement by speckle tracking echocardiography: validation against sonomicrometry and tagged magnetic resonance imaging. *J Am Coll Cardiol* 2006;47:789-93. <http://doi.org/fgf695>
22. Lang R, Badano L, Mor-Avi V, Afalalo J, Armstrong A, Ernande L, et al. Recommendations for Cardiac Chamber Quantification by Echocardiography in Adults: An Update from the American Society of Echocardiography and the European Association of Cardiovascular Imaging. *J Am Soc Echocardiogr* 2015;28:1-39. <http://doi.org/bhj5>
23. Marin-Neto JA, Cunha-Neto E, Maciel BC, Simões MV. Pathogenesis of chronic Chagas heart disease. *Circulation* 2007;115:1109-23. <http://doi.org/cnstwr>
24. Nascimento CA, Gomes VA, Silva SK, Santos CR, Chambela MC, Madeira FS, et al. Left atrial and left ventricular diastolic function in chronic Chagas disease. *J Am Soc Echocardiogr* 2013;26:1424-33. <http://doi.org/bkdn>
25. Migliore R, Adaniya M, Tamagusuku H, Lapuente A. Evaluación de la función diastólica en la enfermedad de Chagas con Doppler tisular pulsado. *Medicina* 2003;63:692-6.
26. Barros MV, Machado FS, Ribeiro AL, Rocha MO. Diastolic function in Chagas' disease: an echo and tissue Doppler imaging study. *Eur J Echocardiogr* 2004;5:182-8. <http://doi.org/brq7j8>
27. Barros MV, Machado FS, Ribeiro AL, Da Costa Rocha MO. Detection of early right ventricular dysfunction in Chagas' disease using Doppler tissue imaging. *J Am Soc Echocardiogr* 2002;15:1197-201. <http://doi.org/d7hsqz>
28. Barros MV, Ribeiro AL, Machado FS, Da Costa Rocha MO. Doppler tissue imaging to assess systolic function in Chagas' disease. *Arq Bras Cardiol* 2003;80:36-40. <http://doi.org/c55b7d>
29. Barbosa MM, Costa Rocha MO, Vidigal DF, Bicalho Carneiro R de C, Araújo RD, et al. Early detection of left ventricular contractility abnormalities by two-dimensional speckle tracking strain in Chagas' disease. *Echocardiography* 2014;31:623-30. <http://doi.org/bkdp>
30. Silva CE, Ferreira LD, Peixoto LB, Monaco CG, Gil MA, Ortiz J, et al. [Evaluation of segmentary contractility in Chagas' disease by using the integral of the myocardial velocity gradient (myocardial strain) obtained through tissue Doppler echocardiography]. *Arq Bras Cardiol* 2005;84:285-91. <http://doi.org/fss83t>
31. Garcia-Alvarez A, Sitges M, Regueiro A, Poyatos S, Jesus Pinazo M, Posada E, et al. Myocardial deformation analysis in Chagas heart disease with the use of speckle tracking echocardiography. *J Cardiac Fail* 2011;17:1028-34. <http://doi.org/excwwf>