

Usefulness of Adenosine Testing in the Differential Diagnosis Between Fasciculoventricular Pathways and Wolff-Parkinson-White-type Ventricular Preexcitation

Utilidad de la prueba de adenosina en el diagnóstico diferencial entre vías fasciculoventriculares y preexcitación ventricular tipo Wolff-Parkinson-White

ANDRÉS BOCHOEYER¹, NATALIA SCHNETZER², MAURICIO PELLIZA², JUAN C. LÓPEZ DIEZ², RAFAEL RABINOVICH², CLAUDIO A. MILITELLO², MARÍA GRIPPO¹

ABSTRACT

Background: The diagnosis of Wolff-Parkinson-White-type ventricular preexcitation on the surface electrocardiogram is generally easy. However, in patients with minimal or subtle electrocardiographic manifestations, the differential diagnosis with other types of preexcitation, as fasciculoventricular fibers, may be difficult. Adenosine testing is a useful tool for that purpose.

Objective: The aim of this study was to describe our experience with adenosine testing in the differential diagnosis of patients with minimal ventricular preexcitation.

Methods: Among 313 consecutive patients with diagnosis of Wolff-Parkinson-White, 26 patients with minimal preexcitation on the electrocardiogram that questioned the diagnosis were analyzed.

Results: Adenosine testing produced transient first-degree, second-degree and complete atrioventricular block without changing the ventricular activation pattern, ruling out Wolff-Parkinson-White syndrome. Twenty patients underwent an electrophysiology study which confirmed the diagnosis of fasciculoventricular pathways in 16 cases.

Conclusion: In patients with suspected Wolff-Parkinson-White ventricular preexcitation, adenosine testing proved to be an efficient and safe tool to establish or rule out the diagnosis.

Key words: Wolff-Parkinson-White Syndrome - Adenosine - Accessory Atrioventricular Bundle

RESUMEN

Introducción: El diagnóstico de preexcitación ventricular tipo Wolff-Parkinson-White generalmente es sencillo a partir del electrocardiograma. No obstante, en los pacientes con manifestaciones electrocardiográficas mínimas o sutiles, la confirmación diagnóstica y la diferenciación con otras formas de preexcitación, como las fibras fasciculoventriculares, plantea dificultades. La prueba de adenosina se presenta como una herramienta útil para tal fin.

Objetivo: Describir nuestra experiencia con el uso de adenosina en el diagnóstico diferencial de pacientes con mínima preexcitación ventricular.

Material y métodos: De 313 pacientes consecutivos con diagnóstico de Wolff-Parkinson-White, se analizaron 26 pacientes con preexcitación mínima en el electrocardiograma que puso en duda el diagnóstico.

Resultados: La prueba de adenosina permitió descartar Wolff-Parkinson-White en 26 pacientes al documentarse bloqueo auriculoventricular de primer, segundo y/o tercer grado transitorio, sin cambios en el patrón de activación ventricular. En 20 pacientes se realizó estudio electrofisiológico, que confirmó la presencia de vías accesorias fasciculoventriculares en 16 casos.

Conclusión: Ante la sospecha de Wolff-Parkinson-White, la prueba de adenosina resultó eficaz y segura para establecer o descartar el diagnóstico.

Palabras clave: Síndromes de preexcitación - Adenosina - Vía fascículo ventricular

Abbreviations

AV	Atrioventricular	EFS	Electrophysiology study
ECG	Electrocardiogram	WPW	Wolff-Parkinson-White

REV ARGENT CARDIOL 2017;85:353-356. <http://dx.doi.org/10.7775/rac.v85.i4.9288>

Received: 02/02/2017 - Accepted: 03/17/2017

Address for reprints: Dr. Andrés Bochoeyer - Hospital de Niños Ricardo Gutiérrez, Servicio de Cardiología - Sánchez de Bustamante 1451- (C1425DUD) CABA - e-mail: andyboch@gmail.com

¹ Hospital de Niños Ricardo Gutiérrez

² Sanatorio Sagrado Corazón

INTRODUCTION

Ventricular preexcitation syndromes are defined by early ventricular activation due to the presence of a functional antegrade accessory pathway. These pathways may be atrioventricular, atriofascicular, nodoventricular, nodofascicular, and fasciculoventricular bypass tracts with particular clinical, electrocardiographic and electrophysiologic characteristics.

Wolff-Parkinson-White (WPW)-type atrioventricular (AV) accessory pathways are the most common type of preexcitation with a short PR interval and a characteristic slow start of the QRS complex (delta wave) on the surface electrocardiogram (ECG). The resultant QRS complex represents a fusion that may present significant variations in the level of preexcitation.

Ventricular preexcitation syndromes may produce AV reentrant arrhythmias which, under certain circumstances, are associated with risk of sudden death; therefore, the correct diagnosis is essential.

The diagnosis of WPW syndrome is easy in cases with pronounced delta wave, but in patients with minimal preexcitation the diagnosis is doubtful. In these cases, complementary tests may be necessary to make the differential diagnosis with other types of preexcitation, as fasciculoventricular, atriofascicular and nodoventricular pathways.

The adequate diagnosis is important because fasciculoventricular pathways do not constitute an anatomic substrate for reentrant arrhythmias and neither represent a risk associated with atrial or ventricular arrhythmias. (1)

Adenosine has been described as a diagnostic tool in WPW syndrome as it slows down or blocks AV conduction and unmasks preexcitation. (2, 3)

On the contrary, in the presence of a fasciculoventricular pathway, the administration of adenosine slows down AV conduction and produces transient first-degree, second-degree or complete AV block without changing the morphology of the QRS complex or the pattern of ventricular activation. (4)

The aim of this study was to describe our experience with adenosine testing in the differential diagnosis of patients with minimal ventricular preexcitation.

METHODS

A total of 313 consecutive patients referred to the electrophysiology laboratory with suspected WPW syndrome were evaluated. The electrocardiographic evaluation performed by a specialist confirmed the diagnosis in 285 cases (91%).

In the remaining 28 patients, the suspected diagnosis could not be confirmed due to minimal electrocardiographic changes and because the complementary tests (Holter monitoring and exercise stress test) were not conclusive.

These patients were selected to undergo adenosine testing with an intravenous bolus of 0.2 mg/kg under continuous electrocardiographic monitoring. Two types of responses were defined: a) Increased preexcitation, considered as a WPW-type response; b) PR interval prolongation and/or second-degree or complete AV block associated with absence of modifications in the pattern of ventricular activation, considered as non-WPW response. In case adenosine did not produce any

of the responses described, a second dose of 0.3 mg/kg was injected. The difference between the WPW-like response and the non-WPW response depended on the criterion of at least two specialists.

In 20 patients it was possible to perform an invasive electrophysiology study (EPS) to establish the mechanism and confirm the diagnosis.

Statistical Analysis

Categorical variables were expressed as absolute values and percentage, while metric variables were presented as mean, standard deviation and/or range. The goodness of fit test was used to analyze normality of distributions. Statistical analysis was performed using the SPSS 17.0 statistical package for Windows, Chicago, SPSS Inc.

Ethical considerations

All patients or their legal representatives signed an informed consent form for this type of procedure.

RESULTS

Twenty (71%) of the 28 patients were asymptomatic and were referred after a routine clinical examination. The remaining 8 patients had unspecific symptoms as palpitations and dizziness. One patient presented vasovagal syncope. None of the patients had history of supraventricular tachycardia; however, the initial diagnosis of WPW syndrome had a significant impact on the patients as 85% of them received the recommendation of limiting their physical activity (Table 1).

Twelve patients (43%) responded to 0.2 mg/kg of adenosine and 16 patients (57%) required 0.3 mg/kg. In all cases it was possible to differentiate between type a and type b response. No complications or adverse effects were observed.

Two patients presented type a response, confirming the diagnosis of WPW syndrome. Type b response was observed in 26 patients, ruling out the presence of AV accessory pathways. Transient AV block, defined as the presence of at least one blocked P wave, was documented in all the cases of type b response (Figure 1).

An EPS was performed in the 2 patients with WPW-type response, confirming the presence of a left lateral accessory pathway in both cases. In 16 of these 18 cases with non-WPW response, the EPS documented HV (His-ventricular) intervals <35 ms which remained "fixed" during atrial pacing at increasing frequencies (Figure

Table 1. Patients' characteristics

Medication	Suspected preexcitation (28 patients)
Mean age (range)	14.4 years (8-18)
Male sex	62.5%
Asymptomatic	71.4%
Mean PR interval	110 ms
Mean QRS duration	104 ms
History of supraventricular tachycardia	0 (0%)

2). The mean AH (atrio-Hisian) interval was 68 ± 7 ms and the mean HV interval was 17 ± 4 ms. Atrial pacing at decreasing cycle lengths showed progressive prolongation of nodal conduction time until the Wenckebach point was reached (range 280-350 ms) with no changes in the morphology of conducted QRS beats. The EPS was normal in the remaining 2 patients.

DISCUSSION

The usefulness of verapamil and adenosine to unmask ventricular preexcitation has been previously reported, (5) as the accuracy of ECG to predict the accessory pathway location is higher when the level of preexcitation is greater. This type of test is used to accurately locate the accessory pathway in patients with low level of preexcitation and thus define the adequate therapeutic strategy.

In our study, adenosine testing proved to be an efficient tool to define the diagnosis in patients with minimal ECG preexcitation, particularly in children, when complementary tests do not reach conclusive results. The administration of adenosine was useful to differentiate a significant number of type-b response patients and rule out WPW syndrome. A significant number of patients with a response suggestive of fasciculoventricular pathways was also identified. These findings were

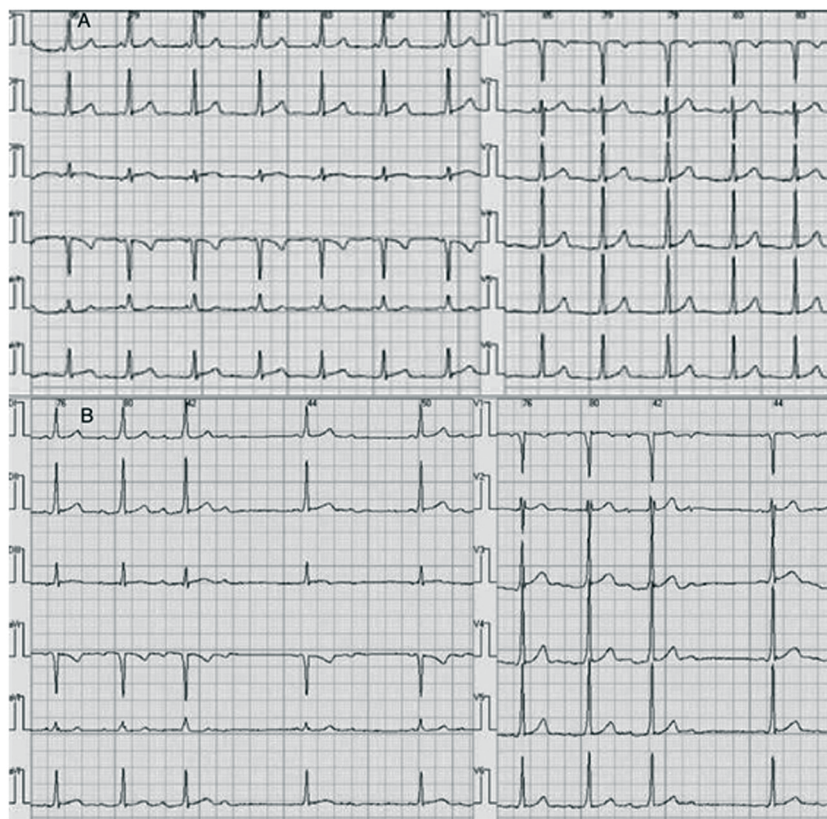
confirmed in 16 cases by EPS, which showed normal AH intervals and short HV intervals, suprahisian deceleration conduction properties during incremental atrial pacing and absence of changes in the level of preexcitation.

Fasciculoventricular accessory pathways were originally described by Mahaim and Benatt.(6) These pathways connect the bundle of His or its branches with the common ventricular myocardium and their ECG features include normal or slightly short PR intervals with a fixed pattern of ventricular preexcitation which does not vary with heart rate changes. (7) These connections do not provide any substrate for the development of reentrant supra-ventricular arrhythmias and do not require specific treatment. However, the diagnostic error may lead to their incorrect classification as WPW syndrome, leading to medical restrictions and unnecessary invasive procedures.

Although the incidence of this type of connections is extremely low in the medical literature, some studies showed a percentage similar to the one described in our study (26/313 patients, 8,3%). (8) Probably, its prevalence may be underestimated due to underdiagnosis, as this entity has a minimal electrocardiographic expression and does not produce arrhythmias.

Finally, despite some reports describe a depressant

Fig. 1. A. Subtle electrocardiographic pattern that provides elements to consider the diagnosis of WPW. **B.** Progressive increase in PR interval, with sequences of second-degree and complete AV block, without significant changes in the pattern of ventricular activation after the administration of adenosine.



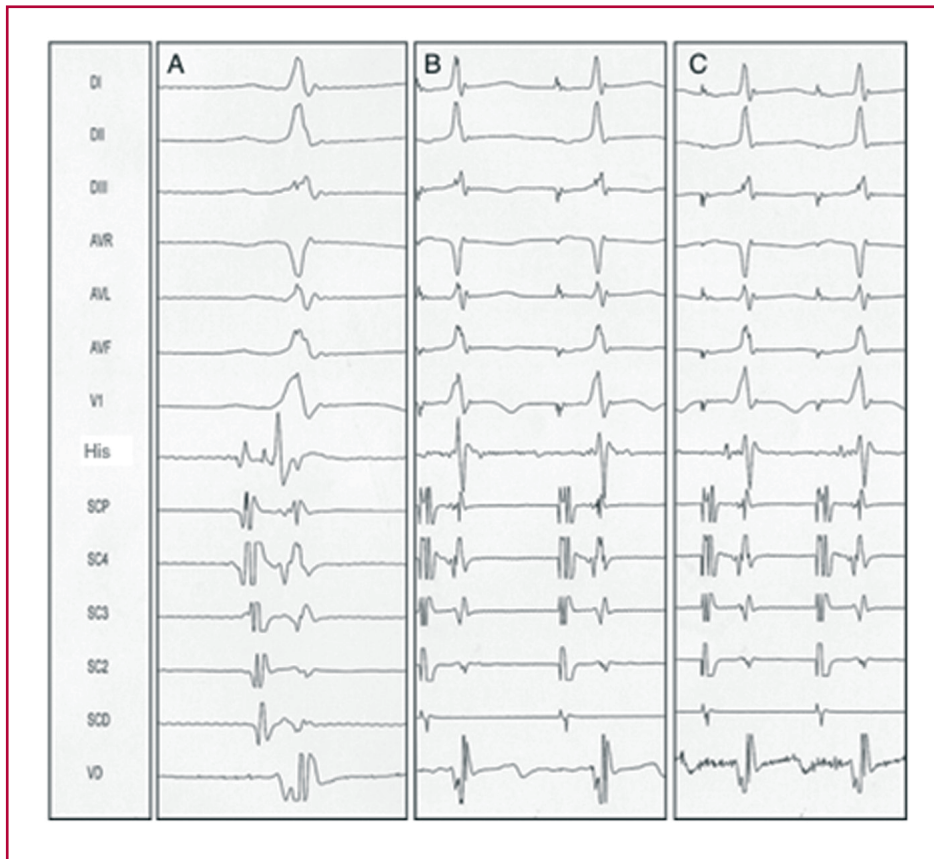


Fig. 1. Electrophysiology study with His recording in the ABL channel (A) at 100 mm/s, atrial pacing, CL 600 ms, 50 mm/s (B), atrial pacing, CL 400 ms, 50 mm/s (C). Progressive increase in AV conduction is seen, at the expense of AH conduction, without changes in the preexcitation level. CL: Cycle length.

adenosine effect on antegrade conduction in certain AV accessory pathways, we could not confirm this “adenosine sensitivity” in our experience. (9, 10)

CONCLUSIONS

Adenosine testing proved to be useful to confirm or rule out WPW syndrome in patients with minimal electrocardiographic expression and allowed the differential diagnosis with other types of preexcitation.

In these patients, adenosine testing could be used as a safe and conclusive tool to define the diagnosis with no need to perform invasive tests.

Conflicts of interest

None declared

(See authors' conflict of interest forms on the website/ Supplementary Material).

REFERENCES

1. Josephson ME. Preexcitation syndromes. En: Josephson ME. Clinical Cardiac Electrophysiology: Techniques and Interpretations. Philadelphia: Lippincott Williams & Wilkins 2008:440-2.
2. Rinne C, Sharma AD, Klein GJ, Yee R, Szabo T. Comparative effects of adenosine triphosphate on accessory pathway and atrioven-

tricular nodal conduction. *Am Heart J* 1988;115:1042-7.<http://doi.org/dgz9cv>

3. Garratt CJ, Antoniou A, Griffith MJ, Ward DE, Camm AJ. Use of intravenous adenosine in sinus rhythm as a diagnostic test for latent preexcitation. *Am J Cardiol* 1990;65:868-73.<http://doi.org/b3x927>

4. Chisari C, Schimberg J, Militello C, Contreras L, Elizari M, Chiale P. Pharmacological responses of a fasciculoventricular fibre: usefulness for its electrocardiographic diagnosis. *Rev Argent Cardiol* 2000;68:719-23.

5. Garro HA, Franco A, Selva HO, Militello CA, Schimberg JM, Alvarez CM, et al. Usefulness of verapamil for the electrocardiographic identification of AV accessory pathway location. *Rev Argent Cardiol* 2000;68:211-7.

6. Mahaim I, Benatt A. Nouvelles recherches sur les connexions supérieures de la branche gauche du faisceau de His-Tawara avec cloison interventriculaire. *Cardiologia* 1938;1:61.<http://doi.org/b8zgn4>

7. Seil Oh, Yun-Shik Choi, Eue-Keun Choi, Hyo-soo Kim, Dae-Won Sohn, Byung-Hee Oh, et al. Electrocardiographic characteristics of fasciculoventricular pathways. *Pacing Clin Electrophysiol* 2005;28:25-8. <http://doi.org/dzs267>

8. Sallee D, Van Hare G. Preexcitation secondary to fasciculoventricular pathways in children. *J Cardiovasc Electrophysiol* 1999;10:36-42. <http://doi.org/b3qrb>

9. Wackel P, Beerman L, Arora G. Wolff- Parkinson-White syndrome and adenosine response in pediatric patients. *Pacing Clin Electrophysiol* 2013;36:491-6.<http://doi.org/ccpp>

10. Perrot B, Clozel JP, Faivre G. Effects of adenosine triphosphate on the accessory pathways. *Eur Heart J* 1984;5:382-93.<http://doi.org/ccpq>