

Trigemino-cardiac Reflex: an Overview

Breve reseña del reflejo trigémino cardíaco

TUMUL CHOWDHURY, MD, DM, FRCP, ¹ THOMAS ROSEMANN, ² AND BERNHARD SCHALLER, MD, ²

ABSTRACT

Background: Trigemino-cardiac reflex is a unique brain stem reflex that manifests as negative cardio-respiratory perturbations. This reflex is largely reported in skull base surgeries/interventions; however, in recent times, it has been also linked with many neurosurgical, neurointerventional procedures, non-neurosurgical and non-surgical conditions. This reflex presents with many cardiovascular changes that can create catastrophic complications, worse outcome as well as diagnostic dilemmas. Therefore, this narrative review intends to elaborate on its mechanisms, definition, pathophysiology, manifestations, diagnosis and management.

Key words: Trigemino-cardiac reflex - Bradycardia - Asystole - Brainstem - Autonomic reflex

RESUMEN

Introducción: El reflejo trigémino cardíaco es un reflejo único del tallo cerebral que se manifiesta como perturbaciones cardiorrespiratorias, y ocurre principalmente en cirugías o intervenciones de la base del cráneo. Sin embargo, recientemente se lo ha vinculado a muchos procedimientos de neurocirugía e intervenciones neurológicas y condiciones no relacionadas a neurocirugía y no quirúrgicas. Este reflejo presenta muchas alteraciones cardiovasculares que pueden provocar complicaciones adversas, empeorar la evolución y producir problemas diagnósticos. Esta reseña intenta profundizar su definición, mecanismos, fisiopatología, manifestaciones, diagnóstico y manejo.

Palabras clave: Reflejo trigémino cardíaco - Bradicardia - Asistolia - Tallo cerebral - Reflejo autónomo

INTRODUCTION

The trigeminocardiac reflex (TCR) is one of the most powerful brain stem reflexes related to the stimulation of any of the sensory divisions of the trigeminal nerve. First described as Kratschmer's reflex in cats and rabbits, (1, 2) TCR is now being increasingly studied. This reflex has been given many names including trigeminodepressor, trigeminovagal, oculo-cardiac reflex, etc. (1, 3) The response may be elicited by the stimulation of any part of the sensory branches of the fifth nerve along their intracranial or extracranial courses. (1, 4, 5) In addition, the recent inclusion of the Gasserian ganglion variant and the chronic variant are also a part of the TCR. (6) The TCR causes a wide array of manifestations that include from hy-

potension to hypertension, bradycardia to asystole, bradypnea to apnea and gastric motility changes. Importantly, in the beginning, this reflex was mainly highlighted in neurosurgical procedures (especially, skull base operations), but now it has been explored in many other domains, (7-25) not being limited to the boundaries of the intraoperative period but investigated in many other non-neurosurgical/surgical procedures. This reflex presents with many cardiovascular perturbations and may create catastrophic complications and diagnostic dilemmas for other physicians, so it becomes imperative to understand and know the mechanism, definition, pathophysiology, predisposing factors, manifestations, diagnosis and management of the TCR. Therefore, the present narrative review

REV ARGENT CARDIOL 2018;86:276-282. <http://dx.doi.org/10.7775/rac.v86.i4.13415>

Address for reprints: Bernhard Schaller - Department of Primary Care, University of Zurich, Switzerland e-mail: bernhardjschaller@gmail.com

¹ Department of Anesthesiology and Perioperative Medicine, University of Manitoba, Winnipeg, Manitoba, Canada

² Department of Primary Care, University of Zurich, Zurich, Switzerland

aims to provide a better understanding of TCR and various related facts that are important to physicians.

DEFINITION AND DIAGNOSIS

The TCR is an autonomic reflex that is governed by the brainstem. It involves the three major anatomic components: the sensory division of the fifth nerve, the brainstem nuclei, and the vagus nerve. As a result of the stimulation of the trigeminal nerve (anywhere along its course) it incites and commonly manifests as a sudden development of cardiac perturbations (mainly negative) including bradycardia, asystole, and hypotension. (6, 26) As this reflex is mainly reported and studied intraoperatively under general anesthesia, the other classically described symptoms (apnea, gastric hypermotility) may not have been appreciated so far, as most of the studies are done during operations. (27-39) The classical definition of the TCR is suggested as a reduction in mean arterial blood pressure and heart rate by more than 20% of its baseline values and should coincide with the stimulation of the trigeminal nerve. (40) The subtle TCR manifestations cannot be recorded by this definition; however, it must be noted that apparent events of TCR usually occur with significant hemodynamic changes. (12) Importantly, sometimes, few episodes of the TCR can occur without preceding warning signs; for example, a sudden intense stimulation of the central part of the fifth cranial nerve may produce asystole without warning signs of bradycardia or hypotension. (12) As TCR episodes produce similar hemodynamic changes as those elicited by various other common factors including (18) physiological, anesthetic, bleeding, venous air embolism, anaphylaxis, and position related factors, our group has also developed a more valid definition of the TCR (9) based on two major (plausibility, reversibility) and two minor (repetition, prevention) criteria. The definition established on these criteria can be used to eliminate other causes as well. (9)

ETIOPATHOGENESIS AND TYPES

The TCR is predominantly investigated and reported during the intraoperative period. In the beginning of TCR research, it was commonly described in neurosurgical procedures. (1) Thereafter, it was also reported during maxillo-facial, (3) ophthalmic, (4) nasal, (7) dental (8) and other surgeries. (9)

The TCR is a complex brainstem reflex that includes cranial nerves, ganglion, and various nuclei. The afferent pathway is formed by the fifth nerve, central relay center, brain stem nuclei and the efferent connections are through the tenth nerve. When there is a stimulus (physiological, or pathological) around the sensory division of the fifth nerve, signals are relayed to the sensory nucleus of the trigeminal nerve via the Gasserian ganglion (Fig 1). The afferent pathway continues along the short internuncial nerve fibers in the reticular formation to connect with the efferent pathway in the motor nucleus of the vagus nerve. The common outcome of this reflex is a negative cardiovascular perturbation that is due to the stimulation of the depressor fibers of the vagus nerve that end in the myocardium. (32-33) This is the simplistic elaboration of this reflex arc; however, multiple nuclei and connecting fibers also constitute this reflex pathway. Though the exact mechanism is still unknown, many nuclei described include the sensory nucleus of the trigeminal nerve, the trigeminal nucleus caudalis, the parabrachial nucleus, the rostral ventro-lateral medulla oblongata, the dorsal medullary reticular field and the paratrigenial nucleus. As the TCR is an autonomic reflex, the imbalance between parasympathetic and sympathetic outflows is mainly responsible for the end result of the TCR. Usually, there is a co-activation of both the parasympathetic and sympathetic nervous system. Three common manifestations of the TCR include bradycardia (parasympathetic activation), vasoconstriction (sympathetic activation) and apnea (modulated by the trigeminal

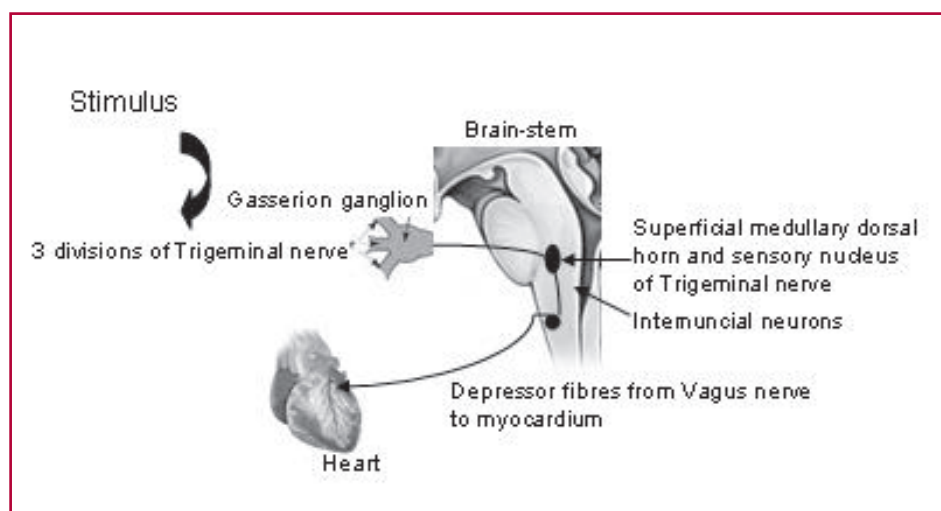


Fig. 1. Schematic diagram showing the mechanism of the trigeminocardiac reflex

system within the brainstem). (6) However, the rapid and transient bradycardia but more prolonged and slightly delayed recovery of hypotension can be partly explained by the fact (33) that parasympathetic fibers primarily innervate the atria and the conducting tissues, whereas sympathetic fibers are more widely distributed throughout the heart. It has been suggested that the myelination status of the nerve may not be a major risk factor, and phenotypic heterogeneity could be the basis of susceptibility for simultaneous autonomic nerve activation. (33)

Anatomically, the occurrence of the TCR may be either due to (a) a peripheral or (b) to the central stimulation of the fifth nerve. (34-35). Commonly, the reflex can be elicited by stimulation of any of the three divisions of the fifth cranial nerve, that is, ophthalmic, maxillary or mandibular nerves. The role of the Gasserian ganglion has also been highlighted recently and thus creates a new subtype of TCR. (1) The anatomical basis of this classification does not provide the exact nature of TCR variants; therefore, our group suggested and elaborated the physiological, embryological and functional basis of TCR classification. (29, 31, 32, 41-46)

Few studies have suggested that during percutaneous radiofrequency thermocoagulation, a pressor rather than a depressor response usually occurs. (36) In our center, we also often encounter pressor responses during Gasserian ganglion rhizolysis or thermocoagulation. However, on the other hand, the balloon compression of a trigeminal ganglion produces intense bradycardia and even, asystole. Sometimes, other forms of arrhythmias, including ventricular fibrillation and cardiac arrest have been reported during the same procedure. Why is it so? We don't know the exact mechanism. Whether or not the stretch or compression of the Gasserian ganglion incites selective trigeminal pathways that eventually causes negative chronotropic response is a matter of further investigation. However, it can be partly explained by the fact that the TCR triggered by peripheral stimulation via the spinal nucleus of the trigeminal nerve to the Kolliker-Fuse nucleus is different from the TCR triggered by central stimulation via the nucleus of the solitary tract to the lateral parabrachial nucleus (37).

INCITING FACTORS

First of all, any surgical procedure in and around the area of distribution of any of the trigeminal nerve branches can incite the TCR. Some of the reported surgical procedures are ophthalmic surgery, (28) craniofacial surgery, (27) skull-base surgery, (31) dental surgery, (27) trigeminal rhizolysis (38) and any other procedure on the head. Interestingly, some of the reported TCR episodes were not related to major surgery at all, but to relatively minor procedures such as suturing of the skin, skull pin fixation, and scalp nerve block. (16-18) Therefore, the perioperative physician should be cognizant about these facts. Almost

all of the literature related to the TCR describes it as an acute intraoperative phenomenon; however, recent articles have also highlighted the chronic form of this reflex. This chronic presentation of the TCR often produces some debilitating symptoms, which impose difficulty in diagnosing this phenomenon. Various inciting factors have been reported for predisposing TCR episodes directly or indirectly. These factors include hypercapnia, hypoxemia, the depth of anesthesia (lighter), younger age group (with high resting vagal tone), narcotics, preoperative use of beta-blockers and calcium-channel blockers, and acidosis. (1, 2, 7, 20) Some intraoperative factors such as light plane of anesthesia, hypercarbia, hypoxia and acidosis are correctable, therefore, these need to be promptly managed. (1, 2, 6, 7, 11) Recent work by our group highlighted the importance of anesthetic depth in the context of TCR occurrence and have suggested that the lighter depth of anesthesia is a potential risk factor for the incidence of TCR episodes. Importantly, there is a stronger link between lighter depth of anesthesia and more episodes of asystole than with deep plane of anesthesia. This study further highlighted that there is almost 4.5-fold pooled risk of asystole in the light anesthesia subgroup of the TCR. In another report by Chowdhury et al., TCR episodes were aborted by boluses of propofol. (25) The authors postulated a surrogate concept of the depth of anesthesia related to TCR occurrence. (25) Whether or not increasing depth with volatile agents would result in a similar abolition of the reflex as seen in the case with propofol is a matter of further investigation.

SYMPTOMATOLOGY

The classical symptoms include a triad of negative cardiovascular changes, apnea and gastric hypermotility. However, as mentioned earlier, all symptoms may or may not be present in patients. Cardiovascular responses are the commonest ones. These include bradycardia, asystole, non-fatal as well as fatal arrhythmias. A non-specific feature may include electrocardiographic changes such as T wave inversion and shortening of the QT interval (33-39) following the occurrence of the TCR. In a review of coronary spasm in neurosurgical patients, the authors highlighted that the majority of coronary spasms were the result of TCR episodes which were usually manifested as ST segment-T wave abnormalities without the evidence of echocardiographic abnormalities, and substantial derangements in cardiac biomarkers. (3) Furthermore, the existence of both major subtypes of TCR (peripheral and central) in the same patient was also reported and thus suggested that both types can co-manifest in the same patient. (16) Why in some patients, fatal arrhythmias and cardiovascular perturbations happen and in others, only few mild, trivial changes occur is a matter of investigation. However, the explanation would be understood on the basis of fine yet differential anatomical, physiological and ge-

netic balance of sympathetic and parasympathetic innervations.

MANAGEMENT (PREVENTION AND TREATMENT)

Most of the preventive strategies were reported for a peripheral variant (oculocardiac) of the TCR. (1, 2, 6, 7, 11) Few studies highlighted the regular use of anticholinergic premedications. (47-50) However, it is now clear that premedication with anticholinergic agents such as atropine and glycopyrrolate do not always prevent the occurrence of TCR. Stratification of risks on the basis of type of surgical procedures, incidences, preoperative and intraoperative risk factors and amendments in the anesthetic and surgical techniques can be regarded as preventive steps. Recently, the use of topical anesthetics has also been proposed to prevent the TCR. (48) But local anesthetics differentially block the various nerve fibers and hence would not be useful in many other cases. More so, use of local anesthetics near the brainstem area could lead to devastating complications (complete brainstem anesthesia).

Concerning TCR management, one of the first and most important steps is to inform the surgeon so that cessation of the stimulus can be immediately done. Most of the times it reverses the phenomenon. Administration of anticholinergics such as atropine or glycopyrrolate may be required in some cases where bradycardia is severe or persists despite termination of the stimulus. (35, 38) However, atropine only blocks cholinergic fibers but does not totally prevent either bradycardia or hypotension in animals, possibly be-

cause their trigeminal depressor response includes both activation of vagal cardioinhibitory fibers and inhibition of adrenergic vasoconstriction after electrical stimulation of the spinal trigeminal tract and trigeminal nuclear complex. (51) In most of the previously published cases, however, the patient responds to the above treatment. But, at times, the TCR may be refractory to the conventional methods of treatment. In such rare situations, use of vasopressors such as epinephrine and other immediate cardiac life support may be required. (52) A recent report of our group highlighted that the light plane of anesthesia is an independent risk factor for TCR episodes, but also the use of atropine was lesser in the deep plane of anesthesia group to abort TCR episodes. (14) In this report, the second step of treatment includes assessment of the depth of anesthesia. Therefore, the algorithm of TCR management should also incorporate this pivotal step.

A prophylactic measure for TCR prevention has been suggested with local anesthetic infiltration or block of the nerve/nerves which convey afferent stimuli. (43) However, the use of lidocaine has been also challenged. (20)

Because the TCR may occur without prior signals, the vigilant role of the anesthetist and knowledge of the TCR cannot be overemphasized.

Arasho and colleagues (49) categorized the management of patients with TCR that should also incorporate depth of anesthesia assessment (20) as follows (Figure 2):

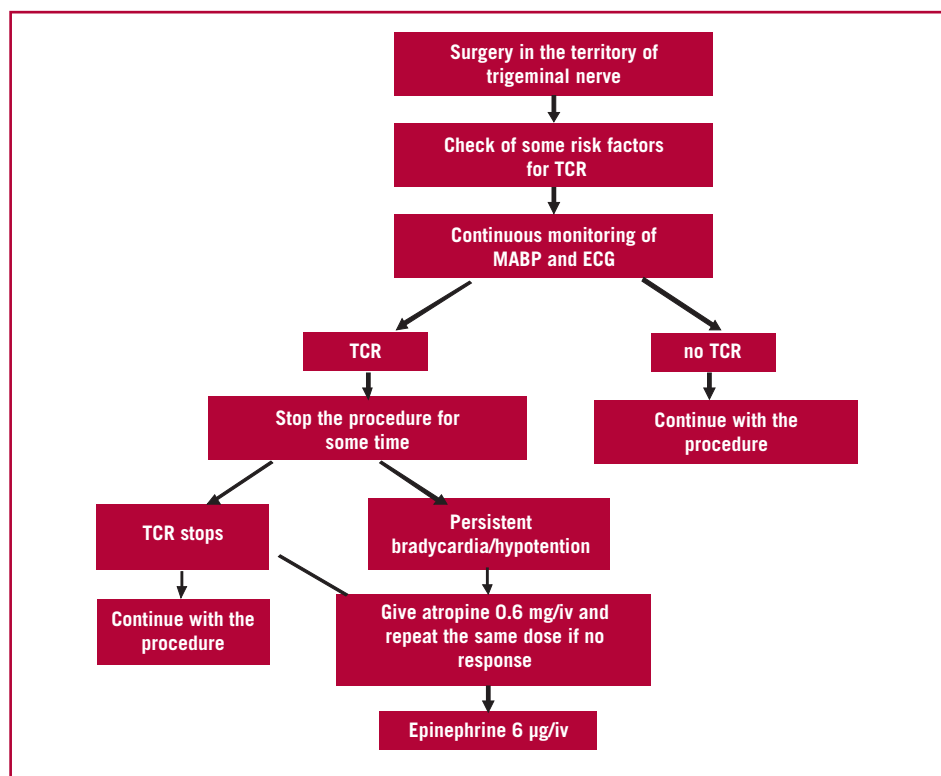


Fig. 2. Algorithm to treat the TCR

1. Risk factor identification and modification
2. Depth of anesthesia assessment
3. Prophylactic treatment with either vagolytic agents or peripheral nerve block in case of peripheral manipulations of the nerve.
4. Careful cardiovascular monitoring during anesthesia, especially in those with a risk factor for TCR.
5. Treatment of the condition when it occurs: cessation of the manipulation, and administration of vagolytic agents and adrenaline.

CLINICAL RELEVANCE

A review by Chowdhury et al. revealed that the TCR is a common cause of cardiac emergencies in elective neurosurgical interventions. (8) Most of TCR episodes were transient and did not significantly affect the neurological outcomes postoperatively. However, other studies highlighted the pathological nature of the TCR and noted functional consequences after intraoperative TCR episodes. As the TCR may take place without prior hemodynamic changes, (34) it is important to identify warning signs that may precede the TCR and to better understand the influence on clinical outcome of such a response. The results of a prospective study suggest that serum biomarkers of ischemia may be useful as surrogate markers to prevent the occurrence of TCR. (44) A recent study also supported that intraoperative TCR episodes were linked to adverse functional outcome in pituitary surgeries. They measured hormone levels before and after pituitary surgery and found inadequacy of pituitary hormones in the TCR group. (12) The role of electrophysiological monitoring during the TCR has also been suggested by Gharabaghi et al. (45) Their preliminary results indicate that intraoperative monitoring of auditory evoked potential changes related to the TCR predict postoperative hearing function and serve as a valuable prognostic tool. Further studies may, however, be needed to evaluate the possible role of electrophysiological monitoring in the detection and prevention of TCR, but it underlines that the intraoperative occurrence of TCR can have a substantial impact on the postoperative functional outcome. In their work on TCR, on the other hand, Schaller and colleagues have suggested that the TCR may be an "oxygen-conserving reflex", (6) so that especially the duration of bradycardia and hypotonia might be necessary depending on which of the two sides the pendulum strikes.

It is, in general, believed that appropriate detection and management of the TCR depends on the tumor characteristics, surgical maneuver, and changes in auditory evoked potentials, which in turn will lead to the successful clinical application of this entity. (45) There is another school of thought where the possible role of serum biomarkers in the occurrence of the TCR is being considered by investigators. Schaller and colleagues (46) believe that serum biomarkers on ischemia may be useful as surrogate markers to prevent the occurrence

of the TCR. The same authors also suggest that radiological indicators of potential anoxic cerebral damage may also be of clinical importance. (46, 53-77) From different studies it seems that reflex-evoked coactivation of cardiac autonomic outflows appears to be the norm rather than the exception. (77) Although coactivation of cardiac vagal and sympathetic outflows can be physiologically appropriate, it is apparent that there can also be pathological outcomes (i.e. generation of arrhythmias), because it does not simply reflect the summation of opposing influences. Paton has proposed that this cardiac autonomic coactivation may allow greater cardiac output during bradycardia (increased ventricular filling time and stronger contraction) than activation of the sympathetic limb alone. (77) This may be important when pumping blood into a constricted vascular tree, such as is the case during the peripheral TCR and the diving response. This knowledge has opened the door for some first clinical cardiac studies.

VIEW TO THE FUTURE

The TCR has certainly its place in perioperative medicine. Current knowledge also indicates that the TCR is also linked to a substantial part of neurological disorders. Beyond this there is only rare literature. But it seems that the TCR also plays a role in cerebral preconditioning (e.g. oxygen-conserving reflex). Altogether, the TCR is - without doubt - an important physiological reaction in mammals.

Not yet published personal observations of the senior author suggest some links of the TCR to certain cardiologic diseases. Its importance remains a question for further research.

Despite the importance and strength of the TCR there is still little information about the cellular mechanisms and brainstem pathways that constitute this reflex. (6) Stimulation of trigeminal fibers evokes a powerful excitatory and polysynaptic pathway to cardiac vagal neurons, (6) and this pathway is endogenously modulated and differentially enhanced, and depressed, by serotonin (5-HT_{1A} and 5-HT₂, respectively) receptors. Inasmuch as such or still more detailed knowledge may open the door for therapeutic use of the TCR in different neurological or cardiac disorders, is not yet clear.

CONCLUSION

The TCR is a ubiquitous phenomenon in mammals and can present from a mild physiological change to severe pathological cardiovascular perturbations. As newer reports related to the TCR are coming from different surgical and more non-surgical conditions, it is imperative for all physicians to know about this unique reflex in detail. This will certainly help the better understanding of the TCR and develop not only future diagnostic but also therapeutic models to manage various neurological and also cardiac disorders. But the better knowledge of the TCR may also allow to better understand the physiological function of the heart.

Conflicts of interest

None declared. (See authors' conflicts of interest forms on the website/Supplementary material).

REFERENCES

- Chowdhury T, Sandu N, Meuwly C, Cappellani RB, Schaller B. Trigeminal cardiac reflex: differential behavior and risk factors around the course of the trigeminal nerve. *Future Neurology* 2014;9:41-7. <http://doi.org/cr3s>
- Chowdhury T, Sandu N, Meuwly C, Schaller B. Trigeminal cardiac reflex: Current trends. *Expert Review of Cardiovascular Therapy* Jan 2014;12:9-11. <http://doi.org/cr3t>
- Chowdhury T, Meuwly C, Sandu N, Schaller B, Cappellani RB. Coronary spasm in neurosurgical patients and role of Trigemino-Cardiac Reflex: A review. *Neurology Research International* 2014;2014:974930. <http://doi.org/gb6272>
- Sandu N, Chowdhury T, Sadr-Eshkevari P, Filis A, Arasho B, Spiriev T, Schaller B. Trigemino-cardiac reflex during cerebellopontine angle surgery: Anatomical location as a new risk factor. *Future Neurology* 2015;10:7-13. <http://doi.org/cr3v>
- Sadr-Eshkevari P, Schaller BJ, Bohluli B. Trigemino-cardiac reflex: Some thought to the definition. *Surg Neurol Int* 2014;5:43. <http://doi.org/cr3w>
- Schaller B, Cornelius JF, Prabhakar H, Koerbel A, Gnanalingham K, Sandu N, et al. For the Trigemino-Cardiac Reflex Examination Group (TCREG). The trigemino-cardiac reflex: An update of the current knowledge. *J Neurosurg Anesthesiol* 2009;21:187-95. <http://doi.org/br5bhk>
- Chowdhury T, Mendelowitz D, Govlanov, E, Spiriev, T, Belachew A, Sandu N, et al. Trigemino-cardiac reflex: An update of the current clinical and physiological knowledge. *J Neurosurg Anesthesiol*. 2015;27:136-47. <http://doi.org/br5bhk>
- Chowdhury T, Petropolis A, Cappellani RB. Cardiac emergencies in neurosurgical patients. *Bio Med Res Int* 2015;2015:751320. <http://doi.org/gb57zf>
- Meuwly C, Golanov E, Chowdhury T, Erne P, Schaller B. Trigemino cardiac reflex: New thinking model about the definition based on a literature review." *Medicine (Baltimore)*. 2015;94:e484. <http://doi.org/cr3x>
- Lemaitre F, Chowdhury T, Schaller B. The trigemino-cardiac reflex – A comparison with the diving reflex in humans. *Arch Med Sci* 2015;11:419-26. <http://doi.org/gcbnj6>
- Meuwly C, Chowdhury T, Sandu N, Reck M, Erne P, Schaller B. Has anesthesia any influence on occurrence and treatment of the Trigemino-cardiac re-flex? A systematic review. *Medicine (Baltimore)*. 2015;94:e807. <http://doi.org/cr3z>
- Chowdhury T, Nöthen C, Filis A, Sandu N, Buchfelder M, Schaller B. Surgery for pituitary adenomas and intraoperative trigemino-cardiac reflex: First description of functional influence. *Medicine (Baltimore)*. 2015;94:e1463. <http://doi.org/cr32>
- Sandu N, Chowdhury T, Schaller BJ; Trigemino-Cardiac Reflex Examination Group (TCREG). How to apply case reports in clinical practice using surrogate models via example of the trigemino-cardiac reflex. *J Med Case Rep*. 2016;10:84. <http://doi.org/cr33>
- Meuwly C, Chowdhury T, Gelpi R, Reck M, Erne P, Schaller B. The trigemino-cardiac reflex - Treatment with atropine still justifiable? *J Neurosurg Anesthesiol*. 2016; in press.
- Chowdhury T, West M. Intraoperative asystole in a patient undergoing craniotomy under monitored anesthesia care: Is it TCR? *J Neurosurg Anesthesiol* 2013;25:92-3. <http://doi.org/cr34>
- Chowdhury T, Cappellani RB, West M. Recurrent bradycardia and asystole in a patient undergoing supratentorial tumor resection: Different types of Trigeminal Cardiac Reflex in same patient. *Saudi J Anesth* 2013;7:216-8. <http://doi.org/cr35>
- Chowdhury T, Baron K, Cappellani RB. Severe bradycardia during scalp nerve block in a patient undergoing awake craniotomy. *Saudi J Anesth* 2013;7:356-7. <http://doi.org/cr36>
- Chowdhury T, Cappellani RB. Isolated bradycardia due to skull pin fixation: Raised ICP or TCR? *J Neurosurg Anesthesiol* 2013;25:207. <http://doi.org/cr37>
- Chowdhury T, Schaller B, Cappellani R. Severe bradycardia in a patient undergoing retrogasserian glycerol rhizolysis: First description of trigemino-cardiac reflex. *J Neurosurg Anesthesiol* 2013;26:86-7. <http://doi.org/cr38>
- Meuwly C, Chowdhury T, Schaller B. Topical lidocaine and Trigemino-cardiac reflex. *Br J Anesth (E-letters)* April 29, 2013.
- Chowdhury T, Goyal K, Sapra H. Chronic Hemodynamic Disturbances in Neurointensive care: First Description. *Nigerian Medical Journal* 2013;54:361. <http://doi.org/cr39>
- Chowdhury T, Sandu N, Schaller B, Cappellani R. Chronic trigemino-cardiac reflex in a patient with orbital floor fracture: role of surgery and first description". *J Neurosurg Anesthesiol* 2013;26:91-2. <http://doi.org/cr4b>
- Chowdhury T, Meuwly C, Sandu N, Schaller B. Peripheral Trigemino-cardiac Reflex. *Am J Otolaryngol* 2013;34:616. <http://doi.org/f2xr5k>
- Meuwly C, Chowdhury T, Schaller B. Trigemino-cardiac reflex trigger points within the skull base. Neuroanatomical thinking model based on a systematic review and on embryological considerations. *J Neurosurg Anesthesiol* 2015.
- Chowdhury T, Ahuja N, Schaller B. Severe bradycardia during neurosurgical procedure: Depth of anesthesia matters and leads to a new surrogate model of the trigemino-cardiac reflex: A case report. *Medicine (Baltimore)* 2015;94: e2118. <http://doi.org/cr4c>
- Kratschmer F. Über Reflexe von der Nasenschleimhaut auf Atmung und Kreislauf. (About reflexes of the nasal mucosa on breathing and circulation). *Sher Akad Wis Wien* 1870;62:147-70.
- Bohluli B, Bayat M, Sarkarat F, Moradi B, Tabrizi MH, Sadr-Eshkevari P. Trigemino-cardiac reflex during Le Fort I osteotomy: a case-crossover study. *Oral Surg Oral Med Oral Radiol Endod* 2010;110:178-81. <http://doi.org/b74sh3>
- Simon JW. Complications of strabismus surgery. *Curr Opin Ophthalmol* 2010;21:361-6. <http://doi.org/b535xk>
- Yorgancilar E, Gun R, Yildirim M, Bakir S, Akkus Z, Topcu I. Determination of trigemino-cardiac reflex during rhinoplasty. *Int J Oral Maxillofac Surg* 2012; 41:389-93. <http://doi.org/fzhwsm>
- Arakeri G, Arali V. A new hypothesis of cause of syncope: trigemino-cardiac reflex during extraction of teeth. *Med Hypotheses* 2010;74: 248-51. <http://doi.org/bbjbkm>
- Koerbel A, Gharabaghi A, Samii A, Gerganov V, von Gösseln H, Tatagiba M, Samii M. Trigemino-cardiac reflex during skull base surgery: mechanism and management. *Acta Neurochir (Wien)* 2005;147:727-32. <http://doi.org/dpq5n8>
- Lang S, Lanigan DT, van der Wal M. Trigemino-cardiac reflexes: maxillary and mandibular variants of the oculocardiac reflex. *Can J Anaesth* 1991;38:757-60. <http://doi.org/bddr6z>
- Khurana H, Dewan P, Ali Z, Prabhakar H. Electrocardiographic changes due to vagosympathetic coactivation during the trigemino-cardiac reflex. *J Neurosurg Anesthesiol* 2009;21:270. <http://doi.org/dm8kjb>
- Prabhakar H, Anand N, Chouhan RS, Bithal PK. Sudden asystole during surgery in the cerebellopontine angle. *Acta Neurochir (Wien)* 2006;148:699-700. <http://doi.org/cv5rkJ>
- Prabhakar H, Rath GP, Arora R. Sudden cardiac standstill during skin flap elevation in a patient undergoing craniotomy. *J Neurosurg Anesthesiol* 2007;19:203-4. <http://doi.org/frksgm>
- Meng Q, Zhang W, Yang Y, Zhou M, Li X. Cardiovascular responses during percutaneous radiofrequency thermocoagulation therapy in primary trigeminal neuralgia. *J Neurosurg Anesthesiol* 2008; 20:131-5. <http://doi.org/cv6pgs>
- Schaller B, Sandu N, Filis A, Buchfelder M. Cardiovascular responses during percutaneous radiofrequency thermocoagulation therapy in primary trigeminal neuralgia: An explanation of the trigemino-cardiac reflex? *J Neurosurg Anesthesiol* 2008;20:270. <http://doi.org/dp8snc>
- Rath GP, Dash HH, Prabhakar H, Pandia MP. Cardiopulmonary arrest during trigeminal rhizolysis. *Anaesthesia* 2007;62:971-2. <http://doi.org/c9fpr5>
- Schaller BJ, Filis A, Buchfelder M. Trigemino-cardiac reflex in humans initiated by peripheral stimulation during neurosurgical skull-base operations. Its first description. *Acta Neurochir (Wien)* 2008;150:715-8. <http://doi.org/c9fpr5>
- Schaller B, Probst R, Strebel S, Gratzl O. Trigemino-cardiac reflex during surgery in the cerebellopontine angle. *J Neurosurg* 1999;90:215-20. <http://doi.org/bmdmn5>
- Kumada M, Dampney RAL, Reis DJ. The trigeminal depressor response: a novel vasodepressor response originating from the trigeminal system. 1977;119:305-26.

42. Prabhakar H, Ali Z, Rath GP. Trigemino-cardiac reflex may be refractory to conventional management in adults. *Acta Neurochir (Wien)* 2008;150: 509-10. <http://doi.org/d7kpv2>
43. Blanc VF. Trigemino-cardiac reflexes (editorial). *Can J Anaesth* 1991;38:696-9. <http://doi.org/d7s28b>
44. Filis A, Schaller B, Buchfelder M. Trigemino-cardiac reflex in pituitary surgery. A prospective pilot study. *Nervenarzt* 2008;79:669-75. <http://doi.org/fgw3kb>
45. Gharabaghi A, Acioly MA, Koerbel A, Tatagiba M. Prognostic factors for hearing loss following the trigeminocardiac reflex. *Acta Neurochir (Wien)* 2007;149:737-8. <http://doi.org/cz6sgd>
46. Schaller BJ, Filis A, Buchfelder M. Detection and prevention of the trigeminocardiac reflex during skull base surgery. *Acta Neurochir (Wien)* 2007; 149:331. <http://doi.org/b46dgs>
47. Schaller BJ, Filis A, Buchfelder M. Detection and prevention of the trigeminocardiac reflex during skull base surgery. *Acta Neurochir (Wien)* 2007; 149:331. <http://doi.org/b46dgs>
48. Chigurupati K, Vemuri NN, Velivela SR, Mastan SS, Thotakura AK. Topical lidocaine to suppress trigemino-cardiac reflex. *Br J Anaesth*. 2013;110:145. <http://doi.org/cr4d>
49. Arasho B, Sandu N, Spiriev T, Prabhakar H, Schaller B. Management of the trigeminocardiac reflex: Facts and own experience. *Neurol India* 2009;57:375-80. <http://doi.org/d9zns2>
50. Prabhakar H, Schaller BJ. Trigemino-cardiac reflex. In Prabhakar H (ed). *Complications in Neuroanesthesia*. Elsevier, 2016. <http://doi.org/cr4f>
51. Schaller B. Trigemino-cardiac reflex. *J Neurol* 2004;251:658-65. <http://doi.org/bn37rr>
52. Schaller B. Trigemino-cardiac reflex during microvascular trigeminal decompression in cases of trigeminal neuralgia. *J Neurosurg Anesthesiol* 2005;17:45-8.
53. Schaller B. Trigemino-cardiac reflex during transsphenoidal surgery for pituitary adenoma. *Clin Neurol Neurosurg* 2005;107:468-74. <http://doi.org/b2k4wr>
54. Schaller BJ. Trigemino-cardiac reflex. *J Neurosurg* 2007;107:243. <http://doi.org/cfvugd>
55. Schaller BJ, Weigel D, Filis A, Buchfelder M. Trigemino-cardiac adenomas. Methodological description of a prospective skull base study protocol. *Brain Res* 2007;1149:69-75. <http://doi.org/fg9hjj>
56. Schaller B, Cornelius JF, Sandu N, Ottaviani G, Perez-Pinzon MA. Oxygen-conserving reflexes of the brain: The current molecular knowledge. *J Cell Mol Med* 2009;13:644-47. <http://doi.org/djp9s4>
57. Schaller BJ, Rasper J, Filis A, Buchfelder M. Differences in functional outcome of ipsilateral tinnitus after intraoperative occurrence of the trigemino-cardiac reflex in surgery for vestibular schwannoma. *Acta Neurochir (Wien)* 2008; 150:157-60. <http://doi.org/cfrfgc>
58. Spiriev T, Sandu N, Arasho B, Kondoff S, Tzekov C, Schaller B. A new predisposing factor for trigemino-cardiac reflex during subdural empyema drainage: A case report. *J Med Case Rep* 2010;4:391. <http://doi.org/cr4h>
59. Schaller BJ, Buchfelder M. Trigemino-cardiac reflex: A recently discovered "oxygen-conserving" response? The potential therapeutic role of a physiological reflex. *Arch Med Sci* 2006;2:3-5.
60. Spiriev T, Kondoff S, Schaller B. Trigemino-cardiac reflex during temporary clipping in aneurysmal surgery. First description. *J Neurosurg Anesthesiol* 2011; 23:271-2. <http://doi.org/fmqvmz>
61. Schaller BJ, Buchfelder M. Delayed trigeminocardiac reflex induced by an intraorbital foreign body. *Ophthalmologica* 2006; 220:348. <http://doi.org/cvq28v>
62. Schaller BJ, Knauth M, Buchfelder M. Trigemino-cardiac reflex during skull base surgery. A new entity of ischaemic preconditioning/The potential role of imaging. *Eur J Nucl Med Mol Imag* 2006; 33:384-5. <http://doi.org/b6krh3>
63. Schaller BJ, Buchfelder M. Trigemino-cardiac reflex in skull base surgery. From a better understanding to a better outcome? *Acta Neurochir (Wien)* 2006; 148:1029-31. <http://doi.org/dj3fs9>
64. Filis A, Schaller B, Buchfelder M. Trigemino-cardiac reflex in pituitary surgery. A prospective pilot study. *Nervenarzt* 2008;79:669-75. <http://doi.org/fgw3kb>
65. Spiriev T, Tzekov C, Kondoff S, Laleva L, Sandu N, Arasho B, Schaller B. Trigemino-cardiac reflex during chronic subdural haematoma removal: Report of chemical initiation of dural sensitization. *JRSM Short Rep* 2011; 2:27.
66. Sandu N, Sadr-Eshkevari P, Schaller B. Usefulness of case report to improve medical knowledge regarding trigemino-cardiac reflex in skull base surgery. *J Med Case Rep* 2011;5:1-3. <http://doi.org/fn3mf6>
67. Cornelius JF, Sadr-Eshkevari P, Arasho BD, Sandu N, Spiriev T, Lemaitre F, Schaller B. The trigemino-cardiac reflex in adults: Own experience. *Exp Rev Cardiovasc Ther* 2010;8:895-8. <http://doi.org/cxp34f>
68. Nöthen C, Sandu N, Prabhakar H, Filis A, Arasho BD, Buchfelder M, Schaller BJ. Trigemino-cardiac reflex and antecedent transient ischemic attacks. *Exp Rev Cardiovasc Ther* 2010;8:509-12. <http://doi.org/d28ns7>
69. Schaller B, Sandu N, Filis A, Buchfelder M. Peribulbar block or topical application of local anaesthesia combined for pediatric strabismus surgery. *Anaesthesia* 2008;63:1142-3. <http://doi.org/fdznmn>
70. Abdulazim A, Bohluli B, Schaller B, Stienen MN, Prochnow N, Sandu N, Sadr-Eshkevari P. Trigemino-cardiac reflex in neurosurgery – current knowledge and prospects. In: Signorelli F (ed) *Explicative Cases of Controversial Issues in Neurosurgery*. INTECH Publisher, 2012. <http://doi.org/cr4j>
71. Sandu N, Spiriev T, Lemaitre F, Filis A, Schaller B. New molecular knowledge towards the trigeminocardiac reflex as a cerebral oxygen-conserving reflex. *The Scientific World Journal* 2010;10:811-7. <http://doi.org/cwmpg8>
72. Spiriev T, Sandu N, Kondoff S, Tzekov C, Schaller B. Tic and autonomic symptoms. *J Neurosurg* 2012;116:1397-8. <http://doi.org/cr4k>
73. Spiriev T, Kondoff S, Schaller B. Cardiovascular changes after subarachnoidal haemorrhage initiated by the trigeminocardiac reflex: First description of a case series. *J Neurosurg Anesthesiol* 2011;23:379-80. <http://doi.org/bcsc5k>
74. Spiriev T, Tzekov C, Laleva L, Kostadinova C, Kondoff S, Sandu N, Schaller B. Central trigeminocardiac reflex in pediatric neurosurgery: A case report. *J Med Case Rep* 2012;6:1-5. <http://doi.org/cr4m>
75. Spiriev T, Prabhakar H, Sandu N, Tzekov C, Kondoff S, Laleva L, Schaller B. Use of hydrogen peroxide in neurosurgery: Case series of cardiovascular complications. *JRSM Short Rep* 2012;3:6. <http://doi.org/fix734>
76. Schaller BJ, Filis A, Buchfelder M. Prognostic factors of hearing loss following the trigeminocardiac reflex. *Acta Neurochir (Wien)* 2007;149:737-8. <http://doi.org/cz6sgd>
77. Paton JF, Nalivaiko E, Boscan P, Pickering AE. (2006). Reflexly evoked coactivation of cardiac vagal and sympathetic motor outflows: Observations and functional implications. *Clin Exp Pharmacol Physiol* 2006;33:1245–50. <http://doi.org/dqndcq>