

Two-dimensional Strain Echocardiography in the Evaluation of Ventricular Function in Patients with Newly Diagnosed Hereditary Hemochromatosis

Ecografía Doppler strain 2D en la evaluación de la función ventricular en pacientes con diagnóstico reciente de hemocromatosis hereditaria

J. MARTÍN ALADIO^{1,2}, FLORENCIA YAMASATO³, ARIEL K. SAAD¹, JUAN SORDÁ³, OSCAR GROSSO¹, ESTEBAN GONZÁLEZ BALLERGA³, JORGE DARUICH³, SARA BERENSZTEIN¹

ABSTRACT

Background: Hereditary hemochromatosis is a genetic disorder characterized by systemic iron overload which can involve the heart in advanced stages. Early myocardial involvement has not been thoroughly investigated.

Objective: The aim of our study was to evaluate the performance of conventional Doppler-echocardiography and 2D strain echocardiography in a group of patients with newly diagnosed hereditary hemochromatosis vs. a control group.

Methods: Patients with newly diagnosed hereditary hemochromatosis without treatment were included. All the patients underwent conventional Doppler echocardiography and 2D strain echocardiography with evaluation of left ventricular longitudinal, radial and circumferential strain, twist and torsion.

Results: Twenty-three male patients with hereditary hemochromatosis (46±18 years) and 20 male controls (45±15 years) were included. There were no differences in ventricular dimensions and wall thickness. Left ventricular ejection fraction was lower in patients with hereditary hemochromatosis (59±4% vs. 62±4%; p=0.01). There were no differences in MAPSE, TAPSE and left ventricular s' velocity. There was a significant decrease in global strain in patients with hereditary hemochromatosis, with greater involvement of radial strain (37±12 % vs. 55±17 %; p=0.01) and circumferential strain (-19.5±2.8 % vs. -22.5±2.8 %; p=0.001), and less involvement of longitudinal strain (-19±1.8 % vs. -21.1±2.5 %; p=0.04). Myocardial rotation showed lower twist (17.7±13° vs. 25±7°; p=0.03) and lower torsion (2.3±1.8°/cm vs. 3.3±1.1°/cm; p=0.03). There was no correlation between the different strain parameters and iron metabolism.

Conclusions: Echocardiography, and particularly 2D strain analysis can detect early abnormalities of ventricular mechanics in asymptomatic patients with systemic iron overload due to hereditary hemochromatosis.

Key words: Echocardiography - Hemochromatosis - Heart Diseases - Iron

RESUMEN

Introducción: La hemocromatosis hereditaria es una enfermedad genética que genera una sobrecarga sistémica de hierro, y en etapas avanzadas puede afectar el corazón. El compromiso miocárdico precoz por esta enfermedad no ha sido suficientemente investigado.

Objetivo: Comparar mediante ecocardiografía Doppler convencional y strain 2D un grupo de pacientes con diagnóstico reciente de hemocromatosis hereditaria vs. un grupo control.

Materiales y métodos: Se estudiaron pacientes con diagnóstico reciente de hemocromatosis hereditaria, no tratados. Se les realizó un ecocardiograma Doppler convencional y strain bidimensional, evaluándose la deformación longitudinal, radial, circunferencial, giro y torsión del ventrículo izquierdo.

Resultados: Participaron 23 varones con hemocromatosis hereditaria (46 ± 18 años) y 20 controles (45 ± 15 años). No hubo diferencias en los espesores y tamaños ventriculares. Los pacientes con hemocromatosis hereditaria tuvieron una fracción de eyección del ventrículo izquierdo menor (59 ± 4% vs 62 ± 4%; p=0,01). No hubo diferencias en ESPAM, el TAPSE y onda s' del ventrículo izquierdo. Se observó una disminución significativa del strain en los pacientes enfermos, con mayor compromiso de la deformación radial (37 ± 12 % vs 55 ± 17 %; p=0,01), y circunferencial (-19,5 ± 2,8 % vs -22,5 ± 2,8 %; p=0,001), y en menor medida de la longitudinal (-19 ± 1,8 % vs -21,1 ± 2,5 %; p=0,04). También este grupo tuvo menor rotación apical, menor giro (17,7 ± 13° vs 25 ± 7°; p=0,03) y menor torsión (2,3 ± 1,8°/cm vs 3,3 ± 1,1°/cm; p=0,03). No hubo correlación entre los diferentes tipos de deformación y los parámetros bioquímicos del metabolismo férrico.

Conclusiones: La ecocardiografía y especialmente la evaluación del strain 2D es capaz de detectar de manera temprana ligeras alteraciones de la mecánica ventricular, en pacientes asintomáticos, con sobrecarga sistémica de hierro por hemocromatosis hereditaria.

Palabras clave: Ecocardiografía - Hemocromatosis - Cardiopatías - Hierro

REV ARGENT CARDIOL 2019;87:429-435. <http://dx.doi.org/10.7775/rac.v87.i6.16591>

Received: 08/11/2019 – Accepted: 10/21/2019

Address for reprints: José Martín Aladio - Av. Córdoba 2351, piso 10, sala 1 - (C1120AAF) CABA, República Argentina - e-mail: martinaladio@hotmail.com

¹ Department of Cardiology, Hospital de Clínicas "José de San Martín" - Universidad de Buenos Aires, Argentina.

² Coronary Care Unit, Hospital de Clínicas "José de San Martín" - Universidad de Buenos Aires, Argentina.

³ Hepatology Unit, Department of Gastroenterology, Hospital de Clínicas "José de San Martín" - Universidad de Buenos Aires, Argentina.

INTRODUCTION

Hereditary hemochromatosis (HH) is a term used to describe a group of genetic disorders characterized by increased iron absorption, in the presence of normal or elevated body iron levels. (1, 2) The accumulation of excess body iron saturates the mechanisms of iron transportation and storage and leads to the formation of reactive oxygen species, the main determinants of cell dysfunction and death, via the Fenton reaction. (3, 4) Epidemiological data show that cardiomyopathy is one of the main causes of morbidity and mortality in patients with HH. (5-7)

In patients with iron overload secondary to β -thalassemia, two-dimensional (2D) strain analysis can detect impairment of contractile function, even in those with preserved left ventricular ejection fraction (LVEF). (8-10) Even though some authors have observed an association between myocardial iron load evaluated by T2* magnetic resonance imaging (MRI) and abnormal strain values, this was not confirmed in other studies. (11, 12)

Patients with β -thalassemia are usually younger and have higher body iron load than those with HH, particularly in the heart; therefore, it is difficult to extrapolate the results obtained from this population to those with HH. Early myocardial involvement in patients with HH has not been thoroughly investigated. The aim of our study was to evaluate the performance of conventional Doppler-echocardiography and 2D strain analysis in a group of untreated patients with recent diagnosis of HH and systemic iron overload versus a control group.

METHODS

Population

A prospective, observational and analytical study was performed including patients with recent diagnosis of HH (<3 months). The following criteria were used for diagnosis: serum ferritin >200 ng/ml in women or >300 ng/ml in men or transferrin saturation >45%, without a secondary cause of iron overload and liver biopsy suggestive of HH with absent/mild fibrosis. (2, 3) The patients had not received specific treatment and were recruited between November 2017 and May 2019 in the Hepatology Unit of the Department of Gastroenterology, Hospital de Clínicas "José de San Martín" (Universidad de Buenos Aires, Buenos Aires, Argentina). The following exclusion criteria were considered: NYHA functional class > I, history of any structural heart disease (as coronary artery disease, hypertrophic or idiopathic cardiomyopathy or heart valve disease), history of atrial fibrillation, diabetes, alcoholism, use of cancer treatment drugs, left bundle branch block or suboptimal ultrasonic window. The results were compared with those of a control group from the institutional outpatient Cardiology clinic, considering sex, age and cardiovascular risk factors. These patients had undergone an exercise stress test or stress echocardiography to rule out myocardial ischemia, with normal results.

Echocardiography

The echocardiographic examination was performed at the Echocardiography Laboratory with a Vivid E9 (GE Health-

Care, Milwaukee) or Vivid E95 (GE HealthCare) ultrasound machine equipped with M5S multi-frequency transducers. The images were acquired at a frame rate of 60-80 frames/s at rest. Left ventricular chamber dimensions and wall thickness, as well as transvalvular blood flow assessment was carried out according to the guidelines of the American Society of Echocardiography. (13, 14) Speckle tracking echocardiography was used to analyze global longitudinal strain (GLS), circumferential strain (CS) and radial strain (RS). Global longitudinal strain was obtained from apical 4-chamber, 3-chamber and 2-chamber views. Radial strain was calculated from the short-axis view at the level of the papillary muscles. Circumferential strain and left ventricular (LV) rotational parameters were obtained from the analysis of LV basal and apical short-axis views. Twist ($^{\circ}$) was calculated as the algebraic sum of basal and apical rotation, and torsion ($^{\circ}/\text{cm}$) as the ratio between twist and LV base-apex distance.

Strain analysis was performed offline, with the EchoPAC PC v202 software provided by the same manufacturer and in a semi-automatic fashion, with delimitation of the myocardial region of interest and making the adjustments that were considered necessary for adequate speckle tracking. The quality of speckle tracking is validated both by the program and by the operator, having the possibility of excluding from the analysis those segments with defective tracking (Figure 1).

Additional evaluation of the patients with HH

All the patients underwent ultrasound or laparoscopic guided liver biopsy. The histology was suggestive of HH (presence of iron in liver acinar zones 1 and 2). In all the cases genetic testing was carried out to analyze C282Y, H63D and S65C HFE gene mutations, as well as cardiac and hepatic T2* MRI with a Philips Ingenia 3.0T system.

Statistical analysis

All the calculations were performed using IBM SPSS® Statistics 20.0 software package. Categorical variables were expressed as percentages and quantitative variables as mean and standard deviation or median with interquartile range (IQR), as applicable. Normality of variable distribution was assessed using the Kolmogorov-Smirnov test or the Shapiro-Wilk test. The results were compared using the corresponding hypothesis tests (Student's t test, Mann-Whitney or chi square test) according to the type of variable and data distribution. Intraobserver variability was analyzed using the intraclass correlation coefficient. A p value < 0.05 was considered statistically significant.

Ethical considerations

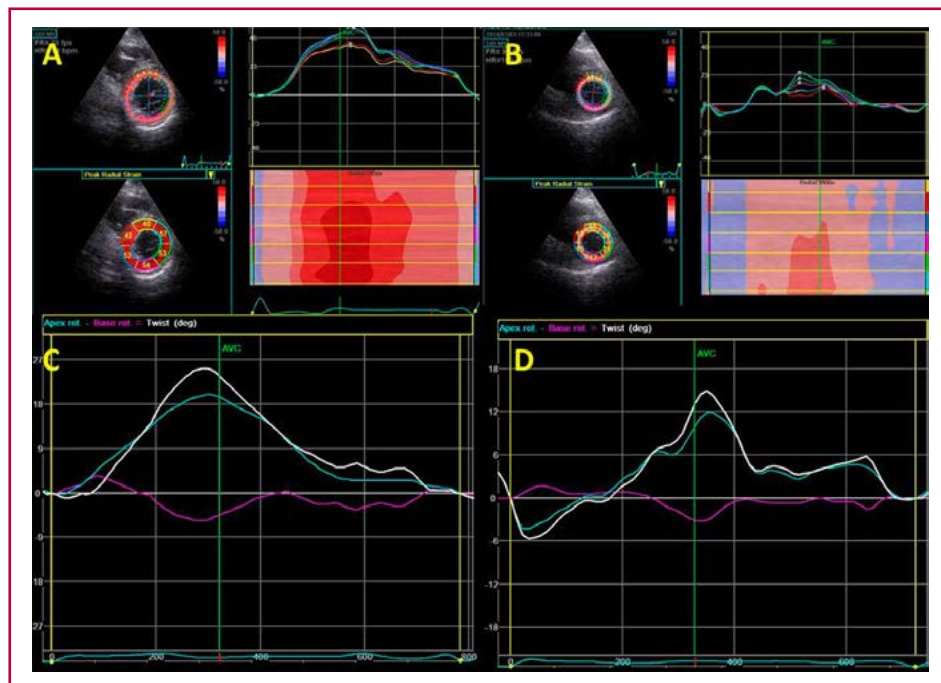
The protocol was approved by Hospital de Clínicas Ethics Committee and was conducted following the recommendations of the Declaration of Helsinki for observational studies.

RESULTS

Population characteristics

Twenty-three male patients with HH (mean age 46 ± 18 years) and 20 male controls (mean age 45 ± 15 years) were included in the study. There were no significant differences in age, heart rate, blood pressure and cardiovascular risk factors. Table 1 describes the population characteristics and the results of iron tests in patients with HH.

Fig. 1. **A** and **B:** Radial strain in a control patient and in a patient with hereditary hemochromatosis (HH), respectively. **C** and **D:** Twist in a control patient and in a patient with HH, respectively.



Genetic testing for HFE mutations reported 1 (4%) C282Y homozygous and 3 (13%) C282Y heterozygous patients, 3 (13%) H63D homozygous and 5 (22%) H63D heterozygous cases, and no mutations in the rest of the cases.

The liver biopsy showed absence of fibrosis in 48% of the patients and mild fibrosis in 52%. In patients with HH, liver iron overload estimated by MRI was moderate in 39.1% of the cases and severe in 60.9%. None of the cases presented iron overload in the heart by T2* MRI (≥ 20 ms in 100% of cases).

Conventional Doppler echocardiography

Patients with HH had a non-significant trend toward greater left atrial volume (36 ± 10 ml/m² vs. 32 ± 6 ml/m²; $p=0.15$) and greater right atrial area (17 ± 3.5 cm² vs. 15.1 ± 2 cm²; $p=0.12$). There were no differences in ventricular dimensions and wall thickness. Left ventricular ejection fraction was lower in patients with HH ($59 \pm 4\%$ vs. $62 \pm 4\%$; $p=0.01$) but was not $< 50\%$ in any of the cases. The parameters of longitudinal function (MAPSE, TAPSE and the s' velocity determined by tissue Doppler imaging) were similar in both groups. In the evaluation of diastolic function, although early diastolic (E) and late (A) wave velocities of both ventricles was similar in both groups, patients with HH showed a tendency toward lower e' wave velocity determined by tissue Doppler imaging: 0.09 ± 0.02 m/s vs. 0.11 ± 0.03 m/s; $p=0.05$ in the left ventricle, and 0.13 ± 0.03 m/s vs. 0.15 ± 0.03 m/s; $p=0.10$ in the right ventricle. Table 2 summarizes the most relevant findings

2D strain analysis

In the analysis of ventricular mechanics, there was a significant decrease of GLS in patients with HH, with greater involvement of RS (37 ± 12 vs. $55 \pm 17\%$; $p=0.01$) and CS ($-19.5 \pm 2.8\%$ vs. $-22.5 \pm 2.8\%$; $p=0.001$), and less involvement of LS ($-19 \pm 1.8\%$ vs. $-21.1 \pm 2.5\%$; $p=0.04$). The analysis of myocardial rotation showed lower twist ($17.7 \pm 13^\circ$ vs. $25 \pm 7^\circ$; $p=0.03$) and torsion ($2.3 \pm 1.8^\circ/\text{cm}$ vs. $3.3 \pm 1.1^\circ/\text{cm}$; $p=0.03$) in the apical segments (Table 3). There was no correlation between the different types of strain and biochemical parameters of iron metabolism (Table 4).

Intraobserver correlation

The reproducibility of the different deformation indices was tested in 10 randomly selected patients. Intraclass-intraobserver correlation coefficient was 0.98 (95% CI, 0.92-0.99; $p < 0.0001$) for LS, 0.92 (95% CI, 0.85-0.95; $p < 0.0001$) for RS, 0.92 (95% CI 0.80-0.97; $p < 0.0001$) for CS and 0.95 (95% CI, 0.81-0.98; $p < 0.0001$) for twist.

DISCUSSION

This study analyzed a population with recently diagnosed HH, systemic iron overload documented by laboratory tests, MRI and liver biopsy, and without cardiovascular symptoms. Chamber diameters, wall thickness and LVEF were preserved, which is consistent with the early diagnosis of the disease, as opposed to the typical descriptions of dilated cardiomyopathy and LV dysfunction characteristic of more advanced stages of HH. However, there were differ-

	HH group (n=23)	Control group (n=20)	p
Age (years)	46 ± 18	45 ± 15	0.78
Weight (kg)	67.4 ± 16.2	58.9 ± 7.9	0.02
Body mass index (kg/m ²)	26 ± 6.7	25 ± 3	0.65
Heart rate	68 ± 9	68 ± 10	0.98
SBP (mm Hg)	132 ± 13	129 ± 16	0.53
DBP (mm Hg)	81 ± 8	80 ± 8	0.92
HT	27%	35%	0.60
Dyslipidemia	14%	21%	0.65
Smoking habit	13%	14%	0.95
Serum ferritin (ng/mL)	866 ± 426		
Serum iron (µg/ml)	151 ± 48		
Serum transferrin (µg/ml)	227 ± 36		
Transferrin saturation (%)	52 ± 14		
Transferrin saturation capacity (µg/ml)	307 ± 44		
Hematocrit (%)	42 ± 3		

HH: Hereditary hemochromatosis; DBP: Diastolic blood pressure; SBP: Systolic blood pressure. HT: Hypertension

Table 1. Population characteristics and iron tests in patients with hereditary hemochromatosis

	HH group (n=23)	Control group (n=20)	p
LVDD (mm)	46 ± 3.7	45 ± 3.7	0.78
IVSd (mm)	9.3 ± 1.5	9.1 ± 1	0.67
LVMI (g/m ²)	74 ± 18	75 ± 12	0.83
Left atrial volume index (ml/m ²)	36 ± 10	32 ± 6	0.15
Right atrial area (cm ²)	17 ± 3.5	15.1 ± 2	0.12
LVEF (%)	59 ± 4	62 ± 4	0.01
MAPSE (mm)	15 ± 1.9	15 ± 1.6	0.63
TAPSE (mm)	24 ± 3.3	23 ± 3.2	0.58
Mitral E wave (m/s)	0.73 ± 0.14	0.78 ± 0.15	0.30
Mitral A wave (m/s)	0.65 ± 0.26	0.59 ± 0.2	0.38
Mitral s' wave (m/s)	0.08 ± 0.1	0.08 ± 0.1	0.85
Mitral e' wave (m/s)	0.09 ± 0.2	0.11 ± 0.03	0.05
Mitral a' wave (m/s)	0.09 ± 0.02	0.1 ± 0.2	0.50
Tricuspid s' wave (m/s)	0.13 ± 0.02	0.14 ± 0.02	0.58
Tricuspid e' wave (m/s)	0.13 ± 0.03	0.15 ± 0.03	0.10
Tricuspid a' wave (m/s)	0.14 ± 0.04	0.16 ± 0.05	0.35

HH: Hereditary hemochromatosis; LVDD: Left ventricular diastolic dimension; IVSd: Interventricular septum thickness at end-diastole; LVMI: Left ventricular mass index; LVEF: Left ventricular ejection fraction; MAPSE: Mitral annular plane systolic excursion; TAPSE: Tricuspid annular plane systolic excursion.

Table 2. Two-dimensional Doppler echocardiography

ences between the two groups in LVEF, which were not explained by markers of longitudinal function as MAPSE and Doppler tissue imaging (DTI)-derived mitral annular peak systolic velocity (s').

This observation justifies a more profound analysis of the pathophysiology of myocardial involvement due to hereditary iron overload.

Iron accumulation in the subepicardial layers of both ventricles has been described in pathology reports. (15, 16) This preferential involvement of the more external myocardial fibers motivates our interest in the study of ventricular mechanics in these pa-

tients. Given the normal double helical arrangement of the myocardial fibers with opposite orientation, the involvement of the outermost fibers would justify CS impairment and ventricular torsion in early stages of the disease, even when the subendocardial fibers, which contribute to LS, may be less affected or even preserved. (17-21) Therefore, a selective analysis of the different types of strain that contribute to the complex ventricular mechanics demonstrates a predominant involvement of CS, RS, twist and torsion, even below reference values in some patients, and with significant differences compared to the control group.

Table 3. Analysis of the contractile mechanics of the left ventricle using two-dimensional strain

	HH group (n=23)	Control group (n=20)	p
Longitudinal strain (%)	-19 ± 1.8	-20.7 ± 2	0.04
Radial strain (%)	37 ± 12	55 ± 17	0.01
Circumferential strain (%)	-19.5 ± 2.8	-22.6 ± 2.8	0.001
Apical CS (%)	-26.3 ± 5.9	-33 ± 5.9	0.001
Basal rotation (°)	-5.9 ± 5.2	-4.4 ± 3.3	0.29
Apical rotation (°)	13.8 ± 9	20.7 ± 6	0.01
Twist (°)	17.7 ± 13	25 ± 7	0.03
Torsion (°/cm)	2.3 ± 1.8	3.3 ± 1.1	0.03

HH: Hereditary hemochromatosis; CS: Circumferential strain.

Table 4. Correlation between 2D strain and parameters of iron metabolism

	Serum iron		Serum ferritin		Transferrin saturation	
	R	P	R	P	R	P
LVEF	-0.09	0.71	0.39	0.10	-0.07	0.78
Longitudinal strain	0.17	0.48	0.22	0.35	0.19	0.43
Radial strain	0.13	0.55	0.40	0.06	-0.27	0.22
Circumferential strain	-0.29	0.18	-0.38	0.07	0.13	0.55
Apical CS	0.08	0.72	-0.38	0.08	0.28	0.20
Twist	0.06	0.78	0.19	0.38	-0.16	0.47
Torsion	-0.08	0.72	0.06	0.78	-0.21	0.33

LVEF: Left ventricular ejection fraction; CS: Circumferential strain.

This could explain the difference found in LVEF between both groups and a mild but also significant involvement of LS. It is worth mentioning that similar findings have been reported in studies that also evaluated ventricular mechanics in β -thalassemia, another disease associated with myocardial iron overload. In a study comparing 27 patients with β -thalassemia and very high serum ferritin with 27 controls, Monte et al. observed a significant reduction in rotation, twist and torsion with no differences in LS. (11) Recently, Rozwadowska et al. reported a significant reduction in rotation, twist and torsion in 24 patients with HH, with LS reduction as in our study and no differences in LVEF. (22) Byrne et al. evaluated 25 cases with HH and reported a decrease in RS similar to our results, with significantly improvement following a 1-year course of venesection. (23)

Looking at myocardial strain analysis from a pathophysiological point of view, we would like to emphasize that there are not many conditions generating a predominant involvement of the subepicardial layers, as hypertension, coronary artery disease and amyloidosis, to mention a few examples, cause more involvement of subendocardial fibers and LS. (19, 24, 25) Iron overload and pericardial diseases are two of the few entities with subepicardial involvement, resulting in CS impairment, making them an interesting object of study.

Another interesting fact is that in our population with HH, T2* showed absence of myocardial iron deposition. This observation is opposed to the echocardiographic findings suggesting early LV function impairment. Two explanations could justify these findings. Firstly, iron deposition is not the only determining factor in the pathophysiology of the disease, and a possible abnormality of systemic redox status, together with inflammatory, immunological, genetic and environmental factors could directly participate or favor certain susceptibility to cardiac injury caused by iron. (4, 26-28). In fact, in an unpublished investigation, members of this working group together with researchers from the School of Pharmacy and Biochemistry of the University of Buenos Aires found decreased serum levels of coenzyme Q10 (a potent endogenous antioxidant) in patients with HH. Furthermore, this hypothesis could be supported by the lack of correlation observed between echocardiographic parameters and biochemical markers of iron overload, which has also been reported in other studies. (12) Another explanation could be that the normal value of cardiac T2* would be around 40 ms, but that a cutoff point of 20 ms has been accepted to avoid false positive results. (29, 30) In addition, we should add the findings of a recent study of cardiac MRI with T1 mapping technique, which showed that up to two-thirds of patients with systemic iron overload and T2* >20 ms

may have myocardial iron deposition; therefore, some investigators have already proposed T1 mapping as a complement to T2* in the evaluation of these patients. (31, 32)

Beyond these hypotheses, we know that MRI has an undeniable value in the early stages of myocardial iron overload diagnosis; yet, we should bear in mind that Doppler echocardiography is a much more accessible method and that the evaluation of ventricular mechanics by speckle tracking echocardiography provides a more accurate functional evaluation, even in the early stages of the disease, and a more complete understanding of the pathophysiology of myocardial involvement by iron overload.

We consider that this research contributes to the understanding of myocardial involvement due to iron overload especially in patients with HH, since most of the current evidence comes from studies in patients with β -thalassemia. In addition, we think that the study of these diseases broadens the field of investigation of ventricular mechanics, focusing on LV rotational dynamics and CS.

The impact of the early diagnosis of myocardial functional involvement in patients with HH remains unknown as well as whether these findings can be translated into a specific treatment with clinical benefit, as has already been proposed for patients with β -thalassemia. (33)

Study limitations

Although the number of patients is significant considering the rarity of the disease, it is a limiting factor for statistical purposes.

CONCLUSION

Patients with recent diagnosis of HH had lower radial strain and circumferential strain, and a minor reduction of longitudinal strain. Rotation, twist and torsion were also lower than in subjects without HH with similar age, sex and cardiovascular risk factors. Echocardiography, and particularly 2D strain echocardiography could be useful to detect early ventricular mechanical abnormalities in asymptomatic patients with systemic iron overload due to HH.

Conflicts of interests

None declared.

(See authors' conflicts of interest forms on the website/ Supplementary material).

REFERENCES

1. Fitzsimons EJ, Cullis JO, Thomas DW, Tsochatzis E, Griffiths WJ; British Society for Haematology. Diagnosis and therapy of genetic haemochromatosis (review and 2017 update). *Br J Haematol* 2018;181:293-303. <http://doi.org/gdgb9t>
2. Bacon BR, Adams PC, Kowdley KV, Powell LW, Tavill AS; American Association for the Study of Liver Diseases. Diagnosis and management of hemochromatosis: 2011 practice guideline by the American Association for the Study of Liver Diseases. *Hepatology* 2011;54:328-43. <http://doi.org/dqq8sd>
3. Kremastinos DT, Farmakis D. Iron overload cardiomyopathy in clinical practice. *Circulation* 2011;124:2253-63. <http://doi.org/bjm4h3>
4. Ramm GA, Ruddell RG. Iron homeostasis, hepatocellular injury, and fibrogenesis in hemochromatosis: The role of inflammation in a noninflammatory liver disease. *Semin Liver Dis* 2010;30:271-87. <http://doi.org/dxp54j>
5. Gulati V, Harikrishnan P, Palaniswamy C, Aronow WS, Jain D, Frishman WH. Cardiac involvement in hemochromatosis. *Cardiol Rev* 2014;22:56-68. <http://doi.org/f56v25>
6. Yang Q, McDonnell SM, Khoury MJ, Cono J, Parrish RG. Hemochromatosis-Associated Mortality in the United States from 1979 to 1992: An Analysis of Multiple-Cause Mortality Data. *Ann Intern Med* 1998;129:946-53. <http://doi.org/df6k>
7. Niederau C, Fischer R, Pürschel A, Stremmel W, Häussinger D, Strohmeyer G. Long-term survival in patients with hereditary hemochromatosis. *Gastroenterology* 1996;110:1107-19. <http://doi.org/cebqvm>
8. Cusmà Piccione M, Piraino B, Zito C, Khandheria BK, Di Bella G, De Gregorio C, et al. Early identification of cardiovascular involvement in patients with β -thalassemia major. *Am J Cardiol* 2013;112:1246-51. <http://doi.org/f3hsmr>
9. Ari ME, Ekici F, Çetin İI, Tavil EB, Yaralı N, Işık P, et al. Assessment of left ventricular functions and myocardial iron load with tissue Doppler and speckle tracking echocardiography and T2* MRI in patients with thalassemia major. *Echocardiography* 2017;34:383-89. <http://doi.org/f9ns53>
10. Chen MR, Ko HS, Chao TF, Liu HC, Kuo JY, Bulwer BE, et al. Relation of myocardial systolic mechanics to serum ferritin level as a prognosticator in thalassemia patients undergoing repeated transfusion. *Echocardiography* 2015;32:79-88. <http://doi.org/df6m>
11. Monte I, Buccheri S, Bottari V, Blundo A, Licciardi S, Romeo MA. Left Ventricular Rotational Dynamics in Beta Thalassemia Major : A Speckle-Tracking Echocardiographic Study. *J Am Soc Echocardiogr* 2012;25:1083-90. <http://doi.org/df6n>
12. Di Odoardo LA, Giuditta M, Cassinerio E, Roghi A, Pedrotti P, Vicenzi M, et al. Myocardial deformation in iron overload cardiomyopathy : speckle tracking imaging in a beta-thalassemia major population. *Intern Emerg Med* 2017;12:799-809. <http://doi.org/df6q>
13. Lang RM, Badano LP, Mor-Avi V, Afilalo J, Armstrong A, Ernande L, et al. Recommendations for cardiac chamber quantification by echocardiography in adults: an update from the American Society of Echocardiography and the European Association of Cardiovascular Imaging. *J Am Soc Echocardiogr* 2015;28:1-39.e14. <http://doi.org/bhj5>
14. Mitchell C, Rahko PS, Blauwet LA, Canaday B, Finstuen JA, Foster MC, et al. Guidelines for Performing a Comprehensive Transthoracic Echocardiographic Examination in Adults: Recommendations from the American Society of Echocardiography. *J Am Soc Echocardiogr* 2019;32:1-64. <http://doi.org/gfxmcp>
15. Olson LJ, Edwards WD, McCall JT, Ilstrup DM, Gersh BJ. Cardiac iron deposition in idiopathic hemochromatosis: histologic and analytic assessment of 14 hearts from autopsy. *J Am CollCardiol* 1987;10:1239-43. <http://doi.org/cppch3>
16. Buja LM, Roberts WC. Iron in the heart. Etiology and clinical significance. *Am J Med* 1971;51:209-21. <http://doi.org/bt9zn5>
17. Gujja P, Rosing DR, Tripodi DJ, Shizukuda Y. Iron overload cardiomyopathy: better understanding of an increasing disorder. *J Am Coll Cardiol*. 2010;56:1001-12. <http://doi.org/brv29n>
18. Murphy CJ, Oudit GY. Iron-overload cardiomyopathy: pathophysiology, diagnosis, and treatment. *J Card Fail* 2010;16:888-900. <http://doi.org/fnz79b>
19. Omar AM, Vallabhajosyula S, Sengupta PP. Left ventricular twist and torsion: research observations and clinical applications. *Circ Cardiovasc Imaging* 2015;8(6). pii: e003029. <http://doi.org/df6r>
20. Ho SY. Anatomy and myoarchitecture of the left ventricular wall in normal and in disease. *Eur J Echocardiogr* 2009;10:iii3-7. <http://doi.org/ctqnc>
21. Nakatani S. Left ventricular rotation and twist: why should we learn? *J Cardiovasc Ultrasound* 2011;19:1-6. <http://doi.org/bkt8tc>
22. Rozwadowska K, Daniłowicz-Szymanowicz L, Fijałkowski M, Sikorska K, Gałaska R, Kozłowski D, et al. Can two-dimensional

- speckle tracking echocardiography be useful for left ventricular assessment in the early stages of hereditary haemochromatosis? *Echocardiography* 2018;35:1772-81. <http://doi.org/df6s>
23. Byrne D, Walsh JP, Daly C, McKiernan S, Norris S, Murphy RT, et al. Improvements in cardiac function detected using echocardiography in patients with hereditary haemochromatosis. *Ir J Med Sci* 2019. (Epub ahead of print) <http://doi.org/df6t>
24. Weich Glogier F, Vilkas Ansorena J. Miocardiopatías restrictivas. Cianciulli TF, Prezioso HA, Lax JA. Nuevas técnicas en ecocardiografía. CABA, Argentina. Ediciones Journal; 2012. p. 211-23.
25. Sengupta PP, Krishnamoorthy VK, Abhayaratna WP, Korinek J, Belohlavek M, Sundt TM 3rd, et al. Disparate patterns of left ventricular mechanics differentiate constrictive pericarditis from restrictive cardiomyopathy. *JACC Cardiovasc Imaging*. 2008;1:29-38. <http://doi.org/cb2h2q>
26. Cheng CF, Lian WS. Prooxidant Mechanisms in Iron Overload Cardiomyopathy. *Biomed Res Int*. 2013;2013:740573. <http://doi.org/gb6gmh>
27. Kremastinos DT, Flevari P, Spyropoulou M, Vrettou H, Tsiapras D, Stavropoulos-Giokas CG. Association of heart failure in homozygous beta-thalassemia with the major histocompatibility complex. *Circulation* 1999;100:2074-8. <http://doi.org/b29p>
28. Kremastinos DT, Farmakis D, Aessopos A, Hahalis G, Hamodraka E, Tsiapras D, et al. Beta-thalassemia cardiomyopathy: history, present considerations, and future perspectives. *Circ Heart Fail* 2010;3:451-8. <http://doi.org/df3tk2>
29. Carpenter JP, He T, Kirk P, Roughton M, Anderson LJ, de Noronha SV, et al. Calibration of myocardial T2 and T1 against iron concentration. *J Cardiovasc Magn Reson* 2014;16:62. <http://doi.org/f6grx4>
30. Carpenter JP, He T, Kirk P, Roughton M, Anderson LJ, de Noronha SV, et al. On T2* magnetic resonance and cardiac iron. *Circulation*. 2011;123:1519-28. <http://doi.org/cqkq9q>
31. Torlasco C, Cassinerio E, Roghi A, Faini A, Capecchi M, Abdel-Gadir A, et al. Role of T1 mapping as a complementary tool to T2* for non-invasive cardiac iron overload assessment. *PLoS One*. 2018;13:e0192890. <http://doi.org/gc2x8d>
32. Brown RA, Moon JC, Telfer PT, Khanji MY. Extreme cardiac iron loading in transfusion-dependent thalassaemia major: cardiac T2* and T1 mapping guiding treatment. *Eur Heart J* 2019. pii: ehz137. <http://doi.org/df6x>
33. Fernandes JL, Sampaio EF, Fertrin K, Coelho OR, Loggetto S, Piga A, et al. Amlodipine reduces cardiac iron overload in patients with thalassaemia major: a pilot trial. *Am J Med* 2013;126:834-7. <http://doi.org/f2wv53>