

# Lung Ultrasound in Cardiology: A Window to Pulmonary Edema

## *Ecografía pulmonar en cardiología: Una ventana para el edema pulmonar*

ELIZABETH HIRSCHHAUT SCHOR<sup>1</sup>, CARMEN JULIA DELGADO MOSQUERA<sup>2</sup>, MARÍA GABRIELA CORTEZ MONTERO<sup>3</sup>

### ABSTRACT

Lung ultrasound is a novel diagnostic tool that has revolutionized the way of performing ultrasonography and cardiology based on the interpretation of artifacts and modifying the diagnostic and therapeutic approach of patients with heart diseases. This technique can be performed by the cardiologist with the transducer and screen adjustments used in echocardiography and should recognize four ultrasound patterns: aerated/dry lung, wet or interstitial lung, pleural effusion and consolidation. The interstitial pattern is the basis of the applications of this technique in cardiology, which is summarized in seven clinical settings: differential diagnosis of dyspnea, heart failure syndrome, identification of acute respiratory distress, extreme situations as high altitude pulmonary edema, breath-hold diving and ironman, dialysis patients, acute coronary syndrome and alveolar-capillary stress echo. Developing skills in cardiopulmonary ultrasound should be mandatory and not optional for cardiologists.

### RESUMEN

La ecografía pulmonar es una técnica que ha innovado la forma de hacer ultrasonido y cardiología, basando su interpretación en artefactos y modificando el abordaje diagnóstico y terapéutico de pacientes con cardiopatía. El cardiólogo puede hacer ecografía pulmonar con el transductor y ajustes de pantalla de la ecocardiografía y debe reconocer los 4 patrones ecográficos: patrón de pulmón aireado/seco, pulmón húmedo o intersticial, derrame pleural y consolidación. El patrón intersticial es la base de las aplicaciones de esta técnica en el área cardiológica, que se resumen en 7 situaciones clínicas: diagnóstico diferencial de disnea, síndrome de insuficiencia cardíaca, identificación del distrés respiratorio agudo, situaciones extremas como el edema de altura, buceo en apnea y el iron man, nefrópatas en diálisis, síndrome coronario agudo y prueba de ecografía de estrés alvéolo-capilar. Se propone la realización de una ecografía cardiopulmonar como obligatoria y no opcional para el cardiólogo.

### INTRODUCTION

Lung ultrasound (LUS) is a novel diagnostic tool that has revolutionized the way of performing ultrasonography and cardiology based on the interpretation of artifacts by optimizing the diagnostic and therapeutic approach of patients with heart disease. (1) The first mention of this technique was made in 2010 in the scientific statement “Assessing and grading congestion in acute heart failure”, with the timid comment that “ultrasonography of the lungs using an echocardiographic probe is another potentially useful way to assess pulmonary congestion through the visualization of lung ultrasound comet-tails”. (2) In 2012, the

document “International evidence-based recommendations for point-of-care lung ultrasound” stated that this technique is a complement more accurate than chest X-rays and compares well with computed tomography scan in most pulmonary and pleural diseases, as it facilitates the diagnosis of heart failure (HF). (3)

In the consensus statement “Echocardiography and lung ultrasonography for the assessment and management of acute heart failure”, published in 2017 by the European Society of Cardiology (ESC), this technique attained its appropriate position as a fundamental complement of echocardiography, in an integrated approach of heart and lung assessment, to

REV ARGENT CARDIOL 2019;87:463-468. <http://dx.doi.org/10.7775/rac.v87.i6.16767>

Received: 10/23/2019 – Accepted: 11/01/2019

Address for reprints: Elizabeth Hirschhaut - Unidad de Ecocardiografía y Ecografía Pulmonar del Dpto. de Cardiología del Hospital Militar Universitario Dr. Carlos Arvelo, Caracas, Venezuela. E-mail: elihir00@yahoo.com

<sup>1</sup> Specialist in Internal Medicine and Cardiology. Director of the Echocardiography and Lung Ultrasound Unit, Department of Cardiology, Hospital Militar Universitario Dr. Carlos Arvelo, Caracas, Venezuela.

<sup>2</sup> Specialist in Internal Medicine, Pulmonology and Critical Care Medicine. Director of the Echocardiography and Lung Ultrasound Unit, Thoracic Medicine Department, Complejo Hospitalario Dr. José Ignacio Baldó, El Algodonal, Caracas, Venezuela.

<sup>3</sup> Specialist in Internal Medicine and Pulmonology. Adjunct Staff, Department of Pulmonology, Complejo Hospitalario Universitario de Orense, Spain.

improve the evaluation, diagnosis and follow-up of patients with HF and identify those with the worse outcome. (4) In the same year, in the publication “Organ dysfunction, injury and failure in acute heart failure: from pathophysiology to diagnosis and management”, the ESC stated that LUS:

- Is more accurate than auscultation or chest X-ray for the detection of pulmonary congestion.
- Serial assessment may be useful for monitoring treatment effects in patients with HF.
- Provides a graded measure of pulmonary congestion with high reproducibility after a short training period (30 minutes).
- Detects residual pulmonary congestion at discharge of patients with HF, indicating risk for subsequent hospitalizations or death. (5)

In 2018, the ESC continued promoting this technique with two documents:

1. “Comprehensive in-hospital monitoring in HF: Applications for clinical practice and future directions for research” indicating that “LUS allows guiding decongestive therapy and may be useful to indicate discharge readiness. (6)
2. “Indications and practical approach to non-invasive ventilation in acute HF” which included findings of ultrasonography signs of pulmonary congestion as diagnostic criteria for confirmation of acute cardiogenic pulmonary edema. (7)

All these publications show that including LUS in cardiology has modified the daily practice of the specialty by allowing an integrated cardio-pulmonary ultrasound assessment in acute and chronic settings, thus optimizing the diagnosis, follow-up and prognosis of patients with cardiac diseases.

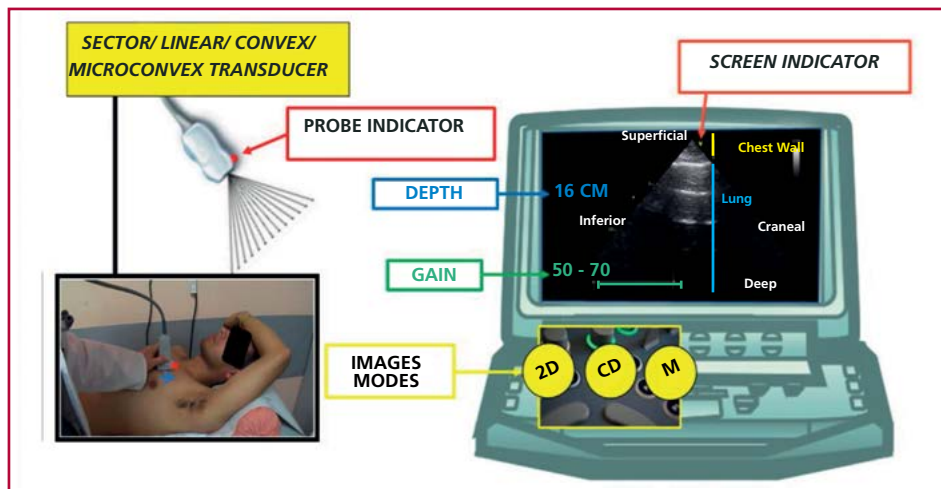
**TECHNICAL ASPECTS**

The cardiologist can use the same probe used for echocardiography, with the same orientation and specifications on the screen. For the exploration, each hemithorax is divided into six regions. Using the anatomic landmarks set by the anterior and posterior axillary lines, three regions are determined: anterior, lateral and posterior. Each region is divided in superior and inferior using the inter-nipple and subscapular lines. The transducer is placed perpendicular to the chest wall, with the probe indicator toward the patient’s head (longitudinal approach). In this way, the superficial structures are visualized at the top of the screen with the cranial structures at the right (Figure 1). (8)

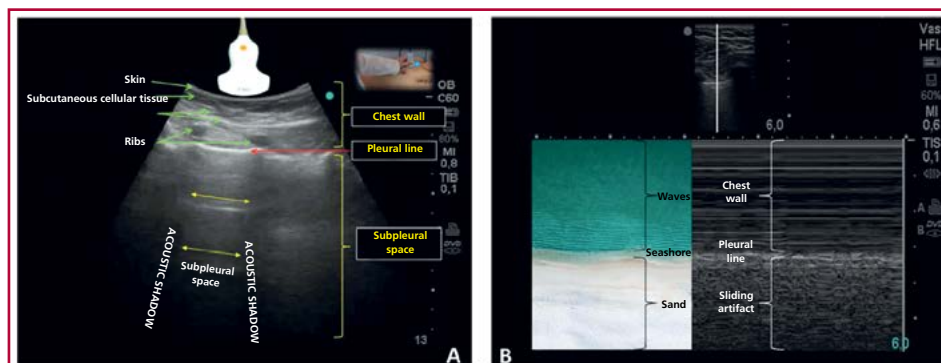
**ULTRASOUND IMAGE**

After placing the transducer on the anterior or superior regions, the following structures shown in Figure 2A are visualized:

- a. Superficial structures of the chest wall, from surface to depth:



**Fig. 1.** Technical aspects of lung ultrasound: probe placement, probe indicator orientation and buttons (depth, gain, imaging modality). 2D: Two-dimensional, CD: Color-Doppler, M: M-mode



**Fig. 2.** A. Pulmonary ultrasound image obtained with a convex transducer in the anterosuperior window. The structures of the chest wall and the sub-pleural space can be identified. B. The seashore sign confirms pleural sliding.

1. Skin: Thin isoechoic line.
  2. Subcutaneous cellular tissue: Hypoechoic area.
  3. Muscle plane: Shades of gray with hyperechoic lines.
  4. Ribs: Thin hyperechoic lines within the muscle plane with posterior acoustic shadowing.
- b. Pleural line: Horizontal and smooth hyperechoic line, 3-mm wide and 0.5 - 1 cm deep to the costal margin. The visceral and parietal pleura slide over each other during inspiration and expiration, giving rise to the sparkling and brilliant “lung sliding” sign. Only in case of doubt, this sign can be confirmed by M-mode image with the “seashore sign”, where the waves correspond to the chest wall, the seashore to the pleural line and the sandy appearance to the artifact created by pleural sliding (Figure 2B).
- c. Sub-pleural space or pulmonary ultrasound window: Space immediately below the pleural line. Artifacts are seen when air is the predominant component and real images are visualized if the lung is mostly filled with fluid.

#### The cardiologist must recognize four ultrasound patterns:

Aerated/dry lung

Interstitial pattern or wet lung

Pleural effusion

Lung consolidation

Each pattern represents a different balance between air and fluid and indicates the degree of aerated lung. (9)

#### Aerated/dry lung pattern:

This pattern corresponds to lung aeration of 99% and has the following characteristic signs:

- “Lung sliding sign”.
- “Seashore sign”
- A lines.

With 99% lung aeration, the ultrasound beam penetrating the chest wall reflects the interface between the pleura and the aerated lung tissue generating A lines, which represent horizontal reverberation artifacts parallel to the pleural line, vanish in depth and are equidistant to the space between the skin and the

pleural line. In this pattern, the subpleural space is represented as a hypoechoic area with A lines, and corresponds to normal lungs or air trapping in diseases as COPD and asthma (Figure 3A).

#### Wet lung pattern, interstitial pattern or interstitial syndrome

This pattern is present with lung aeration of 95%-97% (3%-5% of fluid) and is characterized by the presence of B lines (Figure 3B). In the lung, fluid initially accumulates in the interstitial space (interlobular and intralobular septa surrounded by alveoli). The ultrasonic beam interacts with the interface between the pleural line and interstitial fluid (fluid or inflammatory cells), and is transmitted to the interstitial space, and reflected in the interface between the pleural line and alveolar air, generating artifacts called “B lines” with the following six characteristics:

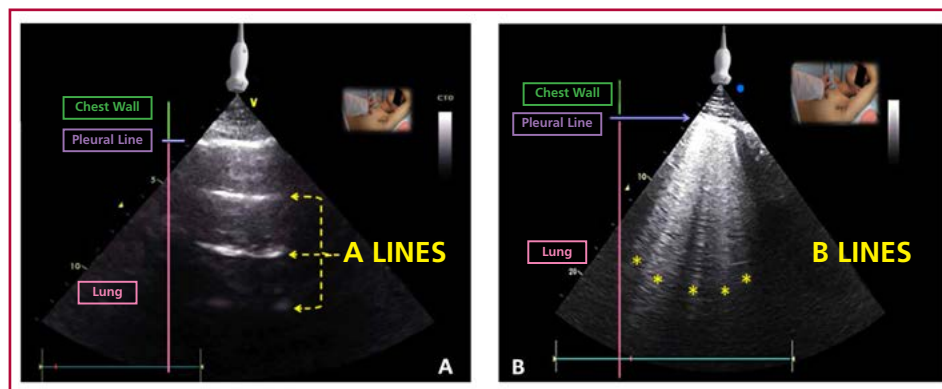
- o They are vertical artifacts.
- o They arise from the pleural line.
- o They continue to the depth of the image.
- o They are laser-like lines.
- o They erase A-lines.
- o They are dynamic and move with pleural sliding.

B lines (< 3) can be seen in normal lungs especially at the bases. However, 3 or more B lines in an intercostal space through a longitudinal approach indicate an interstitial pattern, as described by Lichtenstein in 1997. (10)

This pattern occurs when the normal aeration of the lung decreases, either by the presence of fluid due to hydrostatic (cardiogenic or non-cardiogenic) pulmonary edema or inflammatory cells (parenchymal lung diseases), with correlation between the number of B lines and the severity of the edema. Once the diagnosis of interstitial syndrome has been made, it should be characterized and quantified. Four parameters are used for characterization:

- o Affected areas: Four regions are explored: two anterior regions and two lateral regions. It can be:
  - Diffuse: Two regions affected or greater.
  - Focal: One region affected.
- o Extent:
  - Unilateral: One hemithorax.
  - Bilateral: Both hemithorax.

**Fig. 3.** Images obtained with sector probe in the anterosuperior window. **A.** Aerated or dry lung pattern with A lines. **B.** Wet lung pattern with B lines.



- o Distribution:
  - Homogeneous: The same pattern in all the regions.
  - Heterogeneous: Different patterns.
- o Aspect of the pleural line:
  - Normal: Regular, thin, sliding.
  - Abnormal: Irregular, thick, sliding may not be present.

Characterization may guide the diagnosis. Heart failure is characterized by a diffuse, bilateral and homogeneous pattern with normal pleural line, while in acute respiratory distress syndrome the pattern is diffuse and bilateral, but heterogeneous with abnormal pleural line.

Quantification indicates severity in qualitative or semi-quantitative terms, using several methods: number of B lines present in an intercostal space; echogenicity of the subpleural space (black or white); separation of the B lines at the level of the pleural line (proposed by Lichtenstein); the qualitative appreciation of B lines separation (used in our center) in the following way:

Separated: B lines are spaced. It indicates mild interstitial edema.

Close together: B lines have minimal separation. It indicates moderate interstitial-alveolar edema.

Confluent: B lines without separation. It indicates severe alveolar edema.

#### Pleural effusion pattern

This pattern corresponds to 100% fluid in the subpleural space. It is identified as an area of variable echogenicity, usually anechoic (Figure 4). The lower areas of the thorax should be explored to assess it and the liver or spleen can be used as acoustic window. Once these solid organs are located, the cranial hyperechoic border corresponding to the diaphragm is identified, and everything cephalic to it corresponds to the thorax. Once the thorax is detected, the anechoic area corresponds to pleural effusion. Pleural effusion is classified and quantified by ultrasound. The classification is based on the presence of echogenic images within the effusion. Simple effusions are anechoic and are usually transudates. Complex effusions with echogenic spots or septa strains are exudates in 100% of the cases. (11) There are several ways of quantification in the sitting position and supine position, but all of them inaccurate; however, they give an idea of the amount of fluid and provide a way of monitoring. One of the most convenient ways of quantification is Bialik's formula. With the patient in the supine position with trunk elevation at 15°, the maximal distance between parietal and visceral pleura is measured in end-expiration and multiplied by 20 to obtain an approximate amount of pleural fluid. (12)

#### Lung consolidation pattern

This pattern is present with lung aeration <10%, so the lung is predominantly fluid filled and the images seen are predominantly real (Figure 5). The lung is

seen as a tissue-like structure in echogenicity closely resembling the liver. This pattern is commonly seen in pneumonia, atelectasis, pulmonary infarction, tumors or contusions. The diagnosis is based on the different characteristics of the "tissue-like sign", such as the presence of internal components, homogeneity, margins, vascularization and changes with breathing or different positions. The cardiologist should recognize this pattern to rule out pneumonia as a cause of decompensated HF.

#### CLINICAL APPLICATIONS

The use of LUS in cardiology is mainly based on identifying the wet lung pattern or interstitial syndrome, and can be summarized in seven clinical situations: (13)

1. Dyspnea. Lichtenstein was one of the first to apply LUS for dyspnea. He described that B lines could differentiate acute cardiogenic pulmonary edema from exacerbation of COPD. (14) In 2008, Lichten-

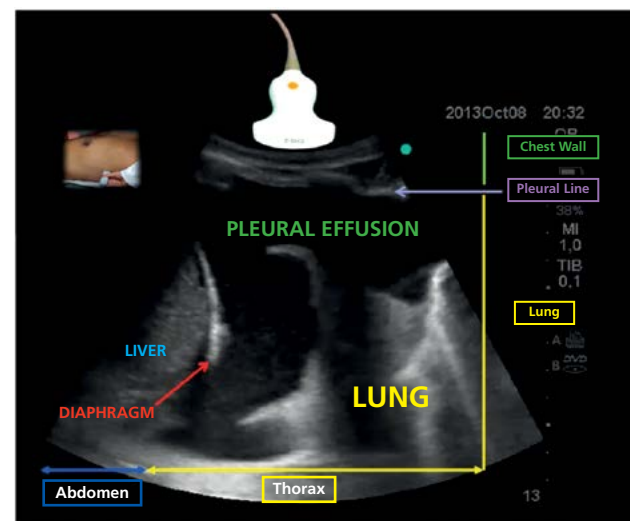


Fig. 4. Pleural effusion pattern.

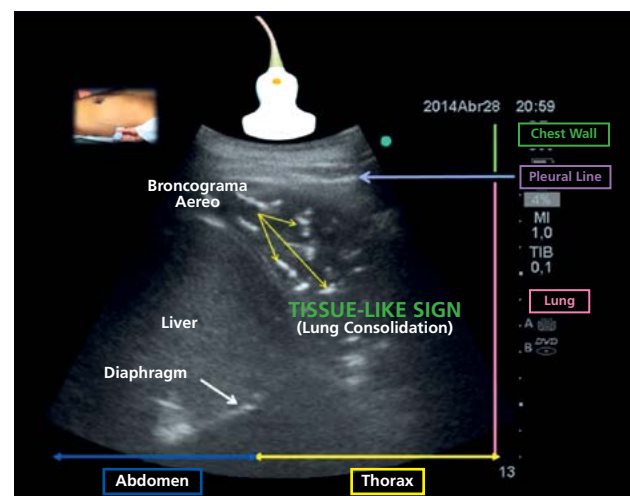


Fig. 5. Lung consolidation pattern

stein described the BLUE protocol for patients with respiratory failure, in which LUS was used to guide the diagnosis with an accuracy of 90.4%. (15) In patients with dyspnea/respiratory failure, the aerated/dry lung pattern directs the diagnosis towards conditions with air trapping such as COPD or asthma. The wet lung pattern suggests cardiogenic or non-cardiogenic pulmonary edema (acute respiratory distress) or interstitial conditions such as interstitial lung disease or interstitial pneumonitis. A pleural effusion pattern can be classified as simple/complex or unilateral/bilateral, and suggests a systemic or local disease. Finally, a consolidation pattern orientates towards the diagnosis of pneumonia, atelectasis, tumors or pulmonary infarction. Thus, LUS not only provides differential diagnoses of the causes of dyspnea but also gives information on the possible causes of decompensation in cardiac patients. Nowadays, LUS is an important first-line modality in the primary evaluation of acute dyspnea. (16)

2. Heart failure syndrome. Heart failure is one of the main applications of LUS in cardiology because of its prevalence and for being the common pathway of most heart diseases. The interstitial pattern identifies pulmonary congestion in acute HF, while the pleural effusion pattern indicates chronic HF. The B lines have been related with several parameters used in cardiology, such as functional class, pulmonary capillary wedge pressure, E/e' ratio, BNP, Kerley B lines, pulmonary congestion by chest x-ray, computed tomography scan or thermodilution methods, among others. (4, 14) Subclinical congestion begins with hemodynamic congestion with elevation of ventricular filling pressures days or weeks before symptoms develop, and is followed by pulmonary congestion with extravasation of fluid into the extravascular pulmonary space. (6) Lung ultrasound can detect congestion in this early stage. B lines are used as markers of edema for:
  - a. Diagnosis:
    1. Presence of three or more B lines in an intercostal space with a diffuse, bilateral and homogeneous pattern and normal pleural line.
    2. Indicator of clinical or subclinical (early diagnosis) pulmonary congestion.
    3. It allows ruling out other etiologies and defines causes of decompensated heart failure.
  - b. Monitoring:
    1. To assess severity.
    2. To guide treatment according to the number of B lines.
    3. To monitor decongestion.
    4. To determine the moment of discharge. (18)
  - c. Prognosis:
    1. To detect residual pulmonary congestion (persistent B-lines at discharge or in ambulatory visits).
    2. To predict readmissions. (19)
3. B lines in acute respiratory distress syndrome (ARDS). In contrast to cardiogenic pulmonary edema, the sonographic findings of ARDS can include the following:
  1. Diffuse, bilateral heterogeneous interstitial pattern with abnormal pleural line.
  2. Small subpleural consolidations visualized as hypoechoic nodules below the pleural line (fragmented pleural line).
  3. "Spared areas": areas of dry lung pattern surrounded by areas of multiple B-lines within the same intercostal space.

This syndrome is produced by abnormalities in alveolar-capillary permeability. In HF, pulmonary congestion is due to increased hydrostatic pressure leading to transudation of fluid into the pulmonary interstitium and then into the alveoli. In ARDS, interstitial and alveolar edema occur simultaneously.
4. Pulmonary edema in extreme settings as high altitude pulmonary edema, after apnea diving and ironman triathlon. (20, 21) High altitude pulmonary edema occurs at heights above 2500 m and is due to hypobaric hypoxia which produces pulmonary hypertension. Lung ultrasound is useful for the evaluation of climbers during their ascent to high altitudes in the different points of ascent in order to delay those who present B lines until they disappear, indicating adaptation. In divers, pulmonary edema after apnea is caused by significant blood volume shift from the peripheral to the central circulatory system, with a non-negligible prevalence of 25% to 45% (associated with genetic predisposition). The prevalence of asymptomatic pulmonary edema until 12 hours after the race has been described in up to 75% of ironman athletes.
5. In chronic kidney failure patients, LUS is particularly useful for the evaluation of dyspnea during dialysis for the early diagnosis of pulmonary congestion in asymptomatic patients. As the number of B lines decreases with dialysis, the use of LUS between dialyses has prognostic implications because the presence of B lines constitutes a risk factor for cardiovascular events and mortality. (22)
6. Acute coronary syndrome. Dr. Gargani was the first to describe ejection fraction, TAPSE and ultrasound lung comet-tails (former name of the B lines) as the only independent predictors of mortality. (23) In acute coronary syndrome, LUS provides:
  - Early diagnosis of pulmonary edema.
  - Prognosis and risk stratification: Patients with B lines are at higher risk of complications and mortality.
7. Alveolar-capillary stress echo. The presence of B lines at peak stress can evaluate the competence of the alveolar-capillary membrane. Within the first minutes after peak stress, hemodynamic congestion is evaluated by the E/e' ratio and the presence

of B lines indicate pulmonary congestion. In the “Stress echo 2020 project for the study of ischemic and non-ischemic heart disease”, Picano et al. proposed ten protocols, five of which included the assessment of B lines. (24)

In light of the evidence, LUS has become a mandatory learning method for the cardiologist, as an indispensable complement to echocardiography which, as an integrated cardiopulmonary ultrasound evaluation, optimizes the diagnosis, treatment, follow-up and prognosis of patients with ischemic, non-ischemic, acute and chronic heart diseases.

## REFERENCES

- Hirschhaut E, Delgado CJ. Ecografía Pulmonar: un nuevo abordaje para cardiólogos. *RETIC* 2018;2:1-7.
- Gheorghide M, Follath F, Ponikowski P, Barsuk JH, Blair JE, Clelan JG, et al. Assessing and grading congestion in acute heart failure: a scientific statement from the acute heart failure committee of the heart failure association of the European Society of Cardiology and endorsed by the European Society of Intensive Care Medicine. *Eur J Heart Fail* 2010;12:423-33. <http://doi.org/dwbz4>
- Volpicelli G, Elbarbary M, Blavais M, Lichtenstein D, Mathis G, Kirkpatrick A, et al. International evidence-based recommendations for point of care lung ultrasound. *Intensive Care Med* 2012;38:577-91. <http://doi.org/gdwph6>
- Price S, Platz E, Cullen L, Tavazzi G, Christ M, Cowie M, et al. Echocardiography and lung ultrasonography for the assessment and management of acute heart failure.
- Harjola V, Mullens W, Banaszewski M, Bauersachs J, Brunner H, Chioncel O, et al. Organ Dysfunction, injury and failure in acute heart failure: from pathophysiology to diagnosis and management. A review on behalf of the Acute Heart Failure Committee of the Heart Failure Association (HFA) of the European Society of Cardiology (ESC). *Eur J Heart Fail* 2017;19:821-36. <http://doi.org/ddh6>
- Harjola V, Parissis J, Brunner H, Celutkienė J, Chioncel O, Collins SP, et al. Comprehensive in-hospital monitoring in acute heart failure: applications for clinical practice and future directions for research. *Eur J Heart Fail* 2018;20:1081-99. <http://doi.org/gdwz42>
- Masip J, Peacock F, Price S, Cullen L, Martin-Sanchez J, Seferovic P, et al. Indications and practical approach to non-invasive ventilations in acute heart failure. *Eur Heart J* 2018;39:17-25. <http://doi.org/gcmqxs>
- Hirschhaut E, Delgado CJ. Ecografía pulmonar: Ciencia o ficción. *Salus Militiae* 2016;40:58-72.
- Toma T, Trigiani M, Zanforlin A, Inchigolo R, Zanobetti M, Sammiceli L, et al. Competence in thoracic ultrasound. *Panminerva Medica* 2019;61:344-66. <http://doi.org/ddh7>
- Lichtenstein D, Meziere G, Biderman P, Gepner A, Barre O. The comet-tail artifact: an ultrasound sign of alveolar-interstitial syndrome. *Am J Respir Crit Care Med* 1997;156:1640-6. <http://doi.org/ddh8>
- Yang PC, Luh KT, Chang DB, Wu HD, Yu CJ, Kuo SH, et al. Value of sonography in determining the nature of pleural effusion: analysis of 320 cases. *Am J Roentgenol* 1992;159:29-33. <http://doi.org/ddh9>
- Balik M, Plasil P, Waldauf P, Pazout J, Fric M, Otahal M, et al. *Intensive Care Med* 2006;32:318-21. <http://doi.org/dfbhgb>
- Gargani L. Lung Ultrasound: a new tool for the cardiologist. *Cardiovasc Ultrasound* 2011;27:6. <http://doi.org/dxb4sf>
- Lichtenstein D, Meziere G. A lung ultrasound sign allowing bedside distinction between pulmonary edema and COPD: the comet tail artifact. *Intensive Care Med* 1998;24:1331-4. <http://doi.org/bb3q4p>
- Lichtenstein D, Meziere G. Relevance of Lung Ultrasound in the Diagnosis of Acute respiratory Failure: The BLUE Protocol. *Chest* 2008;134:117-25. <http://doi.org/cspcds>
- Chun F. Lung Ultrasound- A primarily survey of the acute dispneic patient. *J Intensive Care* 2016, 4:57. <http://doi.org/ddjb>
- Agricola E, Bove T, Oppizzi M, Marino G, Zangrillo A, Margonato A, et al. Ultrasound Comet-tail images: a marker of pulmonary edema: a comparative study with wedge pressure and extravascular lung water. *Chest* 2005;127:1690-5. <http://doi.org/d4bp2v>
- Gargani L, Pang PS, Frassi F, Miglioranza M, Dini F, Landi P, et al. Persistent pulmonary congestion before discharge predicts rehospitalization in heart failure: a lung ultrasound study. *Cardiovascular Ultrasound* 2015;13:40. <http://doi.org/f7pr27>
- Migioranza M, Picano E, Badano LP, Sant Anna R, Rover M, Zafaroni F, et al. Pulmonary congestion evaluated bay lung ultrasound predicts decompensation in heart failure outpatients. *Int J Cardiol* 2016;218:104-8.
- Schwab M, Jayet P, Allemann Y, Sartori C, Scherrer U. Edema Pulmonar de Altura. *Medicina* 2007;67:71-81
- Pingitore A, Garbella E, Piaggi P. Early subclinical increase in pulmonary water content in athletes performing sustained heavy exercise at sea level: ultrasound lung comet tail evidence. *Am J Physiol Heart Circ Physiol* 2011;301:H2161-7. <http://doi.org/csdkm>
- Zoccali C, Torino C, Tripepi R, D Arrigo G, Postorino M, Gargani L. Pulmonary congestion predicts cardiac events and mortality in ESRD. *J Am Soc Nephrol*. 2013;24:639-46. <http://doi.org/ddnb>
- Bedetti G, Gargani L, Sicari R, Gianfaldoni M, Molinaro S, Picano E. Comparison of prognostic value of Echocardiographic Risk Score with Thrombolysis in Myocardial Infarction (TIMI) and Global Registry in Acute Coronary Events (GRACE) Risk Scores in Acute Coronary Syndrome. *Am J Cardiol* 2010;106:1709-16. <http://doi.org/djkzbn>
- Picano E, Ciampi Q, Citro R, DAndrea A, Scali M, Cortigiani L et al. Stress Echo 2020: the international stress echo study in ischemic and non-ischemic heart disease. *Cardiovascular Ultrasound* 2017;15:3. <http://doi.org/f9sst5>