BRIEF ARTICLE

Electrocardiographic Findings in 302 Patients in Prone position due to COVID-19

Hallazgos Electrocardiográficos en 302 pacientes en Decúbito Prono por COVID-19

RICARDO LEVIN[1,2,3], CARLOS RUANO[1], XAVIER RIVADENEIRA MANRIQUE[2-3], MARTIN VILLAFAÑE[1], FERNANDO LIPOVESTKY 3[,4]

ABSTRACT

Background: Respiratory distress syndrome in patients with SARS CoV-2 poses the need for prolonged prone position. This hinders the performance of a conventional electrocardiogram (ECG), leading to consider the one obtained in prone position.
Objective: The aim of this study was to determine the electrocardiographic findings in patients in prone position and compare them with those obtained in supine position.
Methods: Patients in prone position due to respiratory distress syndrome were included in the study. An ECG was performed with definition of the most frequent findings which were compared with those observed in supine position. A p value <0.05 was considered statistically significant.
Results: A total of 302 patients in prone position showed: low voltage in 232 patients (76.8%), counter-clockwise rotation in 207 (68.5%), QS image in right precordial leads in 198 (65.6%), T wave abnormalities in 193 (63.9%), supraventricular arrhythmias in 134 (44.4%), ventricular arrhythmias in 59 (19.5%), and ischemic events in 2 (0.7%) cases.
Conclusions: The most frequent electrocardiographic findings were low voltage, counter-clockwise rotation, QS pattern in right precordial leads and reduced P wave and QRS complex voltage.

Key words: COVID-19 - SARS-CoV-2 - Electrocardiogram - Prone position

RESUMEN

Introducción: El distrés respiratorio en pacientes con SARS-CoV-2 plantea la necesidad de decúbito Prone position prolongado, ubicación que dificulta la realización del electrocardiograma (ECG) convencional, lo cual lleva a plantear su obtención en Prone position.
Objetivos: Determinar los hallazgos electrocardiográficos en pacientes pronados, comparándolos con los obtenidos en posición supina
Material y métodos: Fueron incluidos pacientes pronados por distrés. Se realizó ECG y se definieron los hallazgos más frecuentes y su comparación con la posición supina. Un valor de P menor de 0.05 se consideró significativo
Resultados: en 302 pacientes pronados se observó: bajo voltaje en 232 (76,8%) pacientes, rotación antihoraria en 207 (68,5%), imagen QS en precordiales derechas en 198 (65,6%) y trastornos de la onda T en 193 (63,9%), arritmias supraventriculares en 134(44,4%), ventriculares en 59 (19,5%), y eventos isquémicos en 2 (0,7%) casos.
Conclusión: Los hallazgos más frecuentes resultaron el bajo voltaje, la rotación antihoraria, el patrón QS en precordiales derechas y la reducción del voltaje de la onda P y el QRS.

Palabras clave: COVID-19 - SARS-CoV-2 - Electrocardiograma – Posición Prona

Abbreviations

ARDS	Acute respiratory distress syndrome	**ECG**	Electrocardiogram
AMI	Acute myocardial infarction		

INTRODUCTION

The electrocardiogram (ECG) is a practical and effective tool for the diagnosis of diverse cardiological conditions. In common situations, it is obtained in supine position and the variables considered normal are defined based on this position. (1, 2)

The global COVID-19 pandemic can occur with respiratory involvement leading, in up to 20% of cases, to the development of acute respiratory distress syndrome (ARDS) in adult patients, a condition which requires among other management strategies, prolonged use of a prone position. (3-5)

This position hinders the performance of a periodic ECG in critically ill patients, many of whom could de-

REV ARGENT CARDIOL 2021;89:342-346. http://dx.doi.org/10.7775/rac.v89.i4.20413

Received: 04/07/2021 – *Accepted:* 05/28/2021

Address for reprints: Ricardo Levin - Portela 2975, CABA - E –mail: rllevin@gmail.com

[1] Hospital Santojanni. CABA
[2] Hospital Universitario (Universidad Abierta Interamericana). CABA
[3] Hospital del Cruce Annex. Buenos Aires. República Argentina
[4] Clínica Santa Bárbara. CABA

velop cardiac complications whose detection would be complicated or even go unnoticed. The performance of an ECG in prone position, as well as its findings, have been scarcely described in the literature, but given the increase in the number of COVID-19 cases and the need for prone position, they have attained special relevance. (6)

The aims of the present study were:

1) To assess the electrocardiographic findings observed in patients in prone position due to ARDS secondary to COVID-19.
2) To compare these characteristics with the ECG of the same patient, performed in supine position.

METHODS

Patients >18 years admitted for ARDS in the context of SARS-CoV-2 infection requiring prone position were included between April 1, 2020 and December 1, 2020.

A "conventional" ECG was obtained in supine position on hospital admission, while in those requiring prone position, another ECG was subsequently performed, followed by an ECG every 24 hours on a scheduled basis, or according to the treating physician's opinion. The performance of an ECG in prone position involved placing the precordial electrodes (prone position leads) on the patient's back in a pattern equivalent to that of right precordial leads (Table 1 and Figure 1). (6-8)

Patients in whom the ECG could not be obtained in prone position, those with previously implanted pacemakers, complete left or right bundle branch block or left ventricular hypertrophy and patients with anterior acute myocardial infarction (AMI) sequelae were excluded.

Definitions:

COVID-19 infection: Defined by the presence of a nasopharyngeal swab with positive PCR for SARS-Cov-2.

ARDS: Defined by the presence of hypoxemia, with a PaO2/FiO2 ratio <150, diffuse infiltrate on chest x-ray or computed tomography, and reduced lung compliance in the absence of left ventricular failure.

Generalized low voltage: Presence of electrocardiographic complexes with an amplitude <5 mm in the limb leads and <10 mm in precordial leads (Figure 2)

Right precordial QS image: Presence of pathological Q waves with or without minimal R wave in leads V1 to V3 (Figure 2).

Counter-clockwise rotation: Electrical transition shifted to the right or slight rotation (Figure 2).

ST segment abnormalities: ST-segment elevation without convex pattern, <2 mm or recorded at less than 0.04 mm from the J point, or in less than two leads, or in non-contiguous leads.

T wave disorders: presence of asymmetric T wave abnormalities (positive or negative).

Evidence of ischemia: ST-segment elevation with convex pattern >2 mm in at least two contiguous leads at 0.04 mm from the J point.

Statistical analysis

Clinical and demographic variables were expressed as absolute values and percentages, while electrocardiographic results were expressed as mean and standard deviation for continuous variables and frequencies and percentages for categorical variables.

Student's t test and Pearson's chi-square test were used to establish differences between the analyzed variables, as appropriate. A p value <0.05 was considered statistically significant. SPSS 21.0 (IBM Corp.) software package was used for the statistical analysis.

Ethical considerations

The study was carried out following the recommendations for research in human beings and current legal regulations. Since a review of medical records was performed using anonymous data, no informed consent was obtained from participants. The members of the study implemented measures to protect the privacy and confidentiality of the data in accordance with current legal regulations (Law 25326 on Protection of Personal Data)..

RESULTS

During the study period, 378 patients developing ARDS secondary to COVID-19 were admitted to the intensive care unit. Among them, 76 (20.11%) were excluded from the study, 4 (1.06%) due to death prior to obtaining the ECG in prone position, 24 (6.35%) for having permanent pacemaker, 31 (8.20%) due to previous complete bundle branch block or ventricular hypertrophy and 17 (4.50%) due to sequel of anterior wall infarction; the remaining 302 patients were the study sample.

Average age was 57.4 years (range 32-89) and 185 patients (61.25%) were men. The main characteristics and history of these patients are described in Table 2.

There were 726 ECGs obtained in prone position (average of 2.40 ECGs per patient). The average time between the ECG obtained on hospital admission and the first ECG in prone position was 3.8 (1-7.5) days. The average time between the first and last ECG in prone position was 2.1 (1.5-2.5) days. The average time in prone position was 46.5 (38-60) hours.

No difficulty was observed in obtaining ECGs in

Table 1. Location of electrocardiographic leads in a prone position electrocardiogram. Location of "precordial" leads on the patient's back (prone position leads)

Prone position Lead	Location
V1	Fourth intercostal space, left paravertebral area
V2	Fourth intercostal space, right paravertebral area
V3	Equidistant between V2 and V4 leads in prone position
V4	Fifth intercostal space and scapular midline
V5	Fifth intercostal space and posterior axillary line
V6	Fifth intercostal space and mid axillary line

Note: Do not forget the inversion in the position of the upper limb electrodes (left arm to right arm and vice versa).

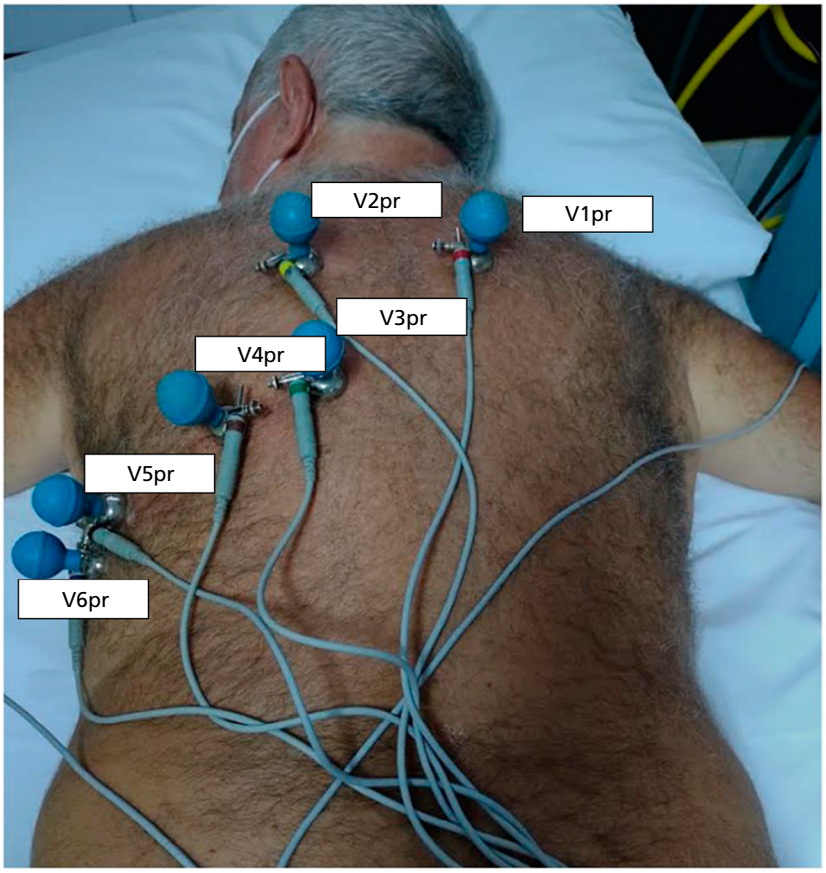

Fig. 1. PLocation of "prone position" leads on the patient's back; pr: Prone position

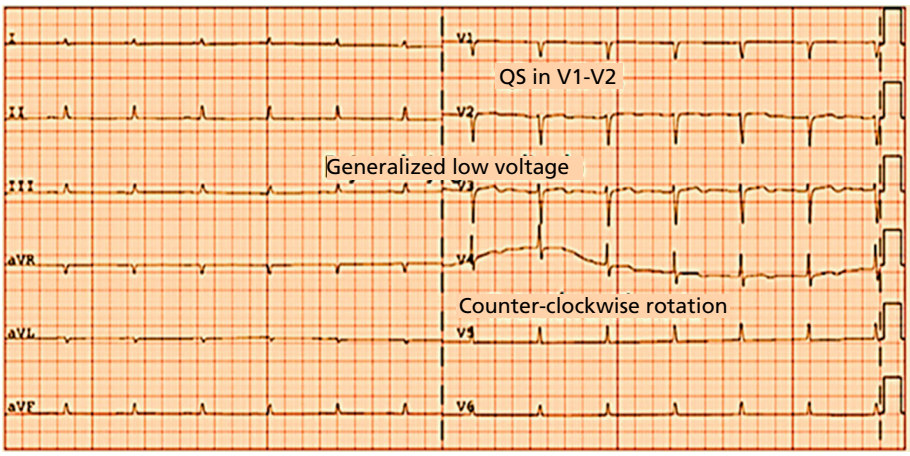

Fig. 2. Electrocardiogram in prone position highlighting some of the characteristics observed: low voltage, QS image in V1 and V2 and counter-clockwise or slight rotation

prone position, although in 6 cases the upper limb leads were incorrectly inverted. Table 3 depicts the comparison between the electrocardiographic findings in prone and supine positions. Figures 3A and 3B show the difference between the precordial leads in both positions.

During prone position, patients were ventilated in a volume-controlled mode with a lung protective strategy (tidal volume of 3 ml/kg of body weight) and maintained under strict protocol of sedoanalgesia with midazolam in 302 patients (100%), fentanyl in 302 (100%), propofol in 31 (10.3%), use of muscle relaxant drugs such as atracurium in 276 (91.4%) and vecuronium in 26 (10.3%), while 265 patients (87.7%) required vasoactive drugs.

DISCUSSION

To our knowledge, the present series represents the largest number of patients in prone position secondary to ARDS due to COVID-19 evaluated for their elec-

Table 2. General population characteristics

Variable	Number (N=302)	v
Average age (range), years	57.4 (32-89)	
Male gender	165	61.2
Medical history		
Hypertension	191	63.2
Diabetes	96	37.8
Dyslipidemia	66	21.8
Smoking	144	47.7
Chronic Obstructive Pulmonary Disease	73	24.1
Prior infarction	61	20.2
Prior percutaneous coronary intervention	74	24.5
Prior cardiac surgery	28	9.3

Table 3. Comparison between electrocardiographic findings in supine and prone position

Variable	Supine (n = 302)	Prone position (n = 302)	p value
Electrical axis (frontal) degrees	+62 ± 5.7	+65 ± 5.68	0.03
Heart rate (bpm)	83.2 ± 14.5	102.5 ± 21.5	<0.001
P wave amplitude (mV)	0.20 ± 0.3	0.12 ± 0.05	<0.001
QRS amplitude (mV)	1.34 ± 0.66	0.63 ± 0.23	<0.001
Generalized low voltage	29 (9.6%)	232 (76.8%)	<0.001
Counter-clockwise rotation	23 (7.6%)	207 (68.5%)	<0.001
QS in right precordial leads	13 (4.3%)	198 (65.6%)	<0.001
ST abnormalities	55 (18.2%)	112 (37.1%)	<0.001
T wave abnormalities	63 (20.9%)	193 (63.9%)	<0.001
Presence of myocardial ischemia	0	2 (0.7%)	0.12
Supraventricular arrhythmias	32 (10.6%)	134 (44.4%)	<0.001
Ventricular arrhythmias	17 (5.6%)	59 (19.5%)	<0.001

bpm: Beats per minute
mV: millivolts

trocardiographic characteristics. The main findings were the detection of generalized low voltage, counter-clockwise rotation, presence of QS complexes in right precordial leads, an increased heart rate, a decrease in the amplitude of both P wave and QRS complex, and presence of ventricular repolarization abnormalities.

The series shows the feasibility of obtaining ECGs in prone position, avoiding the daily need of rotating the patient with ARDS, limiting the risk of exposure for the health team, as well as the mobilization of critically ill patients with respiratory failure, many of whom were unstable under vasoactive drugs. A minor inconvenience, observed in different centers and mentioned in our initial report in 2020, was the omission of inverting the leads located in the upper limbs, leading to an inverted lead image configuration. (6)

Rationale of electrocardiographic findings: The presence of electrocardiographic abnormalities associated to changes in the position of the body was reported by Sigler and White et al. in the 30´s and 40s, mainly referred to T wave abnormalities in these conditions, and by Leindorfer. (9-11)

The mobilization of the heart in prone position towards a ventral position further away from the "precordial" electrodes located on the patient's back, explains the frequent finding of low voltage (and its reduction in P waves and QRS complexes) due to the interposition of a greater amount of soft tissues and bone structures, as well as the greater impedance generated by the injured lung itself, as described by Nguyen et al. in a single patient in prone position due to ARDS secondary to COVID-19. (12)

The same author describes that in the horizontal plane in patients in prone position, the initial forces are directed anteriorly and away from the dorsal electrodes, which generates the QS image in right precordial leads and the counter-clockwise rotation image observed as a result of the dorsal electrodes predominantly facing the left ventricle. Ball et al. described the positional variation of various body structures located both in the head, thorax and abdomen with the change from supine to prone position. In a computed tomography study of 38 patients, the authors reported the ventral shift of the heart and great vessels, together with a change in the heart shape, which acquires a more globular or rounded aspect (13). The increase in heart rate, as well as the supraventricular and ventricular tachyarrhythmias observed in our series, would be associated with the critical situation of patients with respiratory failure secondary to ARDS, with the intervention of factors such as hypoxemia, fever, hydroelectrolytic disorders, presence of a gen-

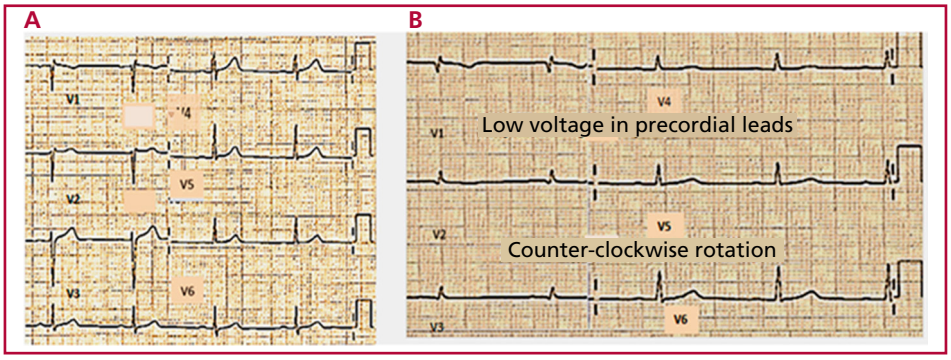

Fig. 3. A: Precordial leads in supine position. **B:** Precordial leads in prone position.

eralized inflammatory condition, and the effect of the various drugs used, many of them with positive chronotropic and proarrhythmic effects (14-15). With the unfortunate prolongation of the COVID-19 pandemic, the need for the use of a prone position will also expand and an increasingly frequent use of the ECG will be necessary in that position, highlighting the importance of establishing and knowing its characteristics. In this sense, the analysis of 40 healthy volunteers undergoing prone position ECG reported by Daralammouri et al. agreed with several of our findings, such as increased heart rate, lower amplitude of the QRS complex, and QS image in the right precordial leads. (16)

CONCLUSIONS

1) The most frequent electrocardiographic findings in prone position were low voltage, counter-clockwise rotation, QS pattern in right precordial leads, and reduced voltage in both the P wave and QRS complex.
2) These findings, in addition to increased heart rate, supraventricular and ventricular arrhythmias and nonspecific repolarization abnormalities, were more frequent than in supine position.
3) Ischemia was detected in a very low number of patients without differences with the ECG in supine position.
4) The aforementioned characteristics are mainly based on the changes experienced by the position of the intrathoracic organs during the prone position, the critical condition of the patients and the effect of the various drugs used during this position.

Conflicts of interest

None declared.

(See authors' conflict of interests forms on the web/Additional material.)

REFERENCES

1. Kligfield P, Gettes LS, Bailey JJ, Childers R, Deal BJ, Hancock EW, et al. Recommendations for the standardization and interpretation of the electrocardiogram. Part I: The electrocardiogram and its technology. A scientific statement from the American Heart Association Electrocardiography and Arrhythmias Committee, Council on Clinical Cardiology; the American College of Cardiology Foundation; and the Heart Rhythm Society.Heart Rhythm 2007;4;394-412. https://doi.org/10.1016/j.hrthm.2007.01.027.

2. Adams MG and Drew BJ. Body position effects on the ECG: implication for ischemia monitoring. J Electrocardiol 1997;4:285 -91. https://doi.org/10.1016/s0022-0736(97)80040-4.

3. Munshi L, Del Sorbo L, Adhikari NKJ, Hodgson CL, Wunsch H, Meade MO, et al. Prone position Position for Acute Respiratory Distress Syndrome. A Systematic Review and Meta-Analysis. Ann Am Thorac Soc 2017;14(Suppl 4):S280-8. https://doi.org//10.1513/AnnalsATS.201704-343OT

4. Piehl MA, Brown RS. Use of extreme position changes in acute respiratory failure. Crit Care Med 1976;4:13-4. https://doi.org/10.1097/00003246-197601000-00003.

5. Guerin C, Beuret P, Constantin JM, Bellani G, Garcia Olivares P, Roca O, et al. A prospective international observational prevalence study on prone position positioning of ARDS patients: the APRONE POSITIONT (ARDS Prone position Position Network) study. Intensive Care Med 2018;44:22-37. https://doi.org/10.1007/s00134-017-4996-5

6. Levin RL. Lipovetsky F, García Aurelio M. Electrocardiografía en tiempos de COVID-19 (Derivaciones pronas). Rev Argent Cardiol 2020;88:239. http://dx.doi.org/107775/rac.es.v88.i3.18208

7. Sanchez JM, Farasat M, Levy AE, Douglas IS, Stauffer BL, Tzou WS, et al. A novel approach to electrocardiography in the prone position patient. Heart Rhythm O2 2021;2:107-9. https://doi.org/10.1016/j.hroo.2020.10.001

8. Tomcsányi J. ECG pearl: prone position position ECG for COVID-19 patients. Orv Hetil 2020;161:1103-4. https://doi.org/10.1556/650.2020.31896.

9. Sigler LH. Electrocardiographic changes occurring with alterations of posture from recumbent to standing positions. Am Heart J 1938;15:146-57.

10. White PD, Chamberlain FL, Graybiel A. Inversion of the T Waves in Lead II Caused by a Variation in Position of the Heart. Heart 1941;3;233-40.

11. Leindorfer A. The electrocardiographic response to changes of posture during respiratory arrest following deep inspiration or expiration; clinical significance. Ann Intern Med 1948;29:1043-55.

12. Nguyen HH, Trohman RG, Huang HD. Influence of Prone position Positioning on Electrocardiogram in a Patient with COVID-19. JAMA Intern Med. 2020;180:1521–3. https://doi.org/10.1001/jamainternmed.2020.3818

13. Ball WS, Wicks JD, Metler FA. Prone position-Supine Change in Organ Position: CT Demonstration. AJR Am J Roentgenol 1980;135:815-20. https://doi.org/10.2214/ajr.135.4.815

14. Overgaard CB, Dzavik V. Inotropes and Vasopressors. Review of Physiology and Clinical Use in Cardiovascular Disease. Circulation 2008;118:1047-56. https://doi.org/10.1161/CIRCULATIONAHA.107.728840.

15. Levin RL, Ruano C, Rios I. Degrange M, Perna E, Marturano MP y cols. Consenso de Inotrópicos y Asistencia Circulatoria Mecánica. Rev Argent Cardiol 2020;88(Supl. 2):1-36

16. Daralammouri Y, Azamtta M, Hamayel H, Adas A, Sawalmeh O, Ismail Y, et al. Impact of Prone position Position on 12-Lead Electrocardiogram in Healthy Adults: A Comparison Study with Standard Electrocardiogram. Cardiol Res Pract 2021;2021:6653061. https://doi.org/10.1155/2021/6653061