

# Management of Symptomatic Unruptured Abdominal Aortic Aneurysms: State of the Art

## *Manejo del aneurisma de aorta abdominal sintomático no roto: últimos adelantos*

FERNANDO D. GARAGOLI<sup>1</sup>, MARÍA L. FERNÁNDEZ RECALDE<sup>1</sup>, ANDRÉS M. IZAGUIRRE<sup>1</sup>

### ABSTRACT

Symptomatic unruptured abdominal aortic aneurysm (AAA) refers to a group of patients with intact AAA but who present abdominal and/or lumbar pain attributed to the aneurysm. This form of clinical presentation is potentially fatal, since its etiopathogenesis, involving acute changes in the aortic wall, including inflammation, increases the probability of impending rupture. It is clear that these patients should be referred to AAA repair. However, the timing of the intervention is controversial. Therefore, the aim of the present work was to review updated information on the diagnostic-therapeutic approach of symptomatic unruptured AAA.

**Key words:** Symptomatic unruptured abdominal aortic aneurysm - Inflammation - Open surgery - Endovascular aneurysm repair

### RESUMEN

El aneurisma de aorta abdominal (AAA) sintomático no roto es una patología que involucra a aquellos pacientes con AAA intacto, pero que presentan dolor abdominal y/o lumbar atribuido al aneurisma. Esta forma de presentación clínica es potencialmente mortal, dado que su etiopatogenia comprende cambios agudos en la pared aórtica, incluyendo inflamación, lo que incrementa la probabilidad de ruptura inminente. Está claro que estos pacientes deben ser derivados a reparación del AAA. Sin embargo, el momento de la intervención es controvertido. Por lo tanto, el objetivo del presente trabajo fue revisar la información actualizada sobre el abordaje diagnóstico-terapéutico del AAA sintomático no roto.

**Palabras clave:** Aneurisma de aorta abdominal sintomático no roto - Inflamación - Cirugía abierta - Reparación endovascular del aneurisma

### INTRODUCTION

The etymology of the word aneurysm can be traced in ancient Greek language. (1,2) It derives from the word *ἀνεύρυσμα* (aneurysma), which means “dilation”. (2) Therefore, “aortic aneurysm” refers to an abnormal dilation of the aorta that compromises one or more wall segments. In this sense, an increase in diameter greater than 50% of the aortic diameter at the level of the diaphragm is accepted as abnormal. However, this definition is not always applicable, since often the limit between the healthy and pathological aorta is not precise. (3,4) Consequently, there is a general consensus in considering abdominal aortic aneurysm (AAA) to be a dilation of the aorta greater than or equal to 30 mm. (4-7) Multiple studies have been developed to evaluate the results

of elective AAA repair, as well as those associated with emergency repair of ruptured aneurysms. (8-15) However, there is a third type of potentially fatal and scarcely studied clinical presentation of AAA: symptomatic unruptured AAA. (16) Therefore, the aim of the present work was to review updated information on the diagnostic-therapeutic approach of symptomatic unruptured AAA.

### METHODS

Searches were carried out in PubMed/Medline, EMBASE, and Cochrane Clinical Trials electronic databases to identify clinical studies that evaluated the diagnostic-therapeutic approach of symptomatic unruptured AAA, using the terms “abdominal aortic aneurysm”, “symptomatic aneurysm”, “unruptured aneurysm”, “open surgery”, and “endovascular aneurysm repair”.

ARGENT J CARDIOL 2023;91:214-218. <http://dx.doi.org/10.7775/rac.v91.i3.20636>

Received: 03/19/2023 – Accepted: 05/29/2023

Address for reprints: Fernando Garagoli MD. email: fernando.garagoli@hospitalitaliano.org.ar. 4190 Perón St, Buenos Aires, Argentina  
Telephone: +541149590200 (5303). ZipCode: C1199ABB



<https://creativecommons.org/licenses/by-nc-sa/4.0/>

@Argentine Journal of Cardiology

<sup>1</sup> Department of Cardiology, Hospital Italiano de Buenos Aires, Buenos Aires, Argentina

The selection of articles was made according to the following criteria: a) publications issued from 1990 to the present; b) observational studies, clinical trials, systematic reviews and recommendations of scientific societies; c) human studies; and d) articles referring to management of symptomatic unruptured AAA. Studies were excluded if the full text was not accessible.

Primary outcomes of this article were: a) to synthesize knowledge about epidemiology, prognosis and diagnostic-therapeutic approach of symptomatic unruptured AAA; and b) to develop an algorithm towards its diagnostic-therapeutic management.

### Definition and epidemiology

Symptomatic unruptured AAA refers to a group of patients with intact AAA but who present abdominal and/or lumbar pain attributed to the aneurysm. Another symptom includes tenderness to palpation overlying the AAA in the abdomen, back, or flank. (17) The presence of pain is due to multiple causes, including acute changes in the aortic wall, as we will describe later. In large aneurysms, pain may be caused by compression of adjacent structures. Symptomatic unruptured AAA patients generally do not have arterial hypotension because the aortic wall is intact, with no evidence of retroperitoneal hemorrhage. (7) The reported incidence of this type of clinical presentation is between 3% and 15%. (18,19)

### Pathophysiology

The pathophysiology of symptomatic unruptured AAA involves acute changes in the aneurysmal wall, including increased wall stress and intra-thrombus expansion or new bleeding, raising the probability of impending aneurysm rupture. (20) Evidence demonstrates the role of aneurysmal wall inflammation in the etiopathogenesis of this type of clinical presentation. In this sense, increased 18-fluorodesoxyglucose metabolism by positron emission computed tomography (PET/CT) in patients with symptomatic unruptured AAA compared with asymptomatic ones correlated with increased inflammatory infiltrate density in aneurysmal wall biopsies. (21)

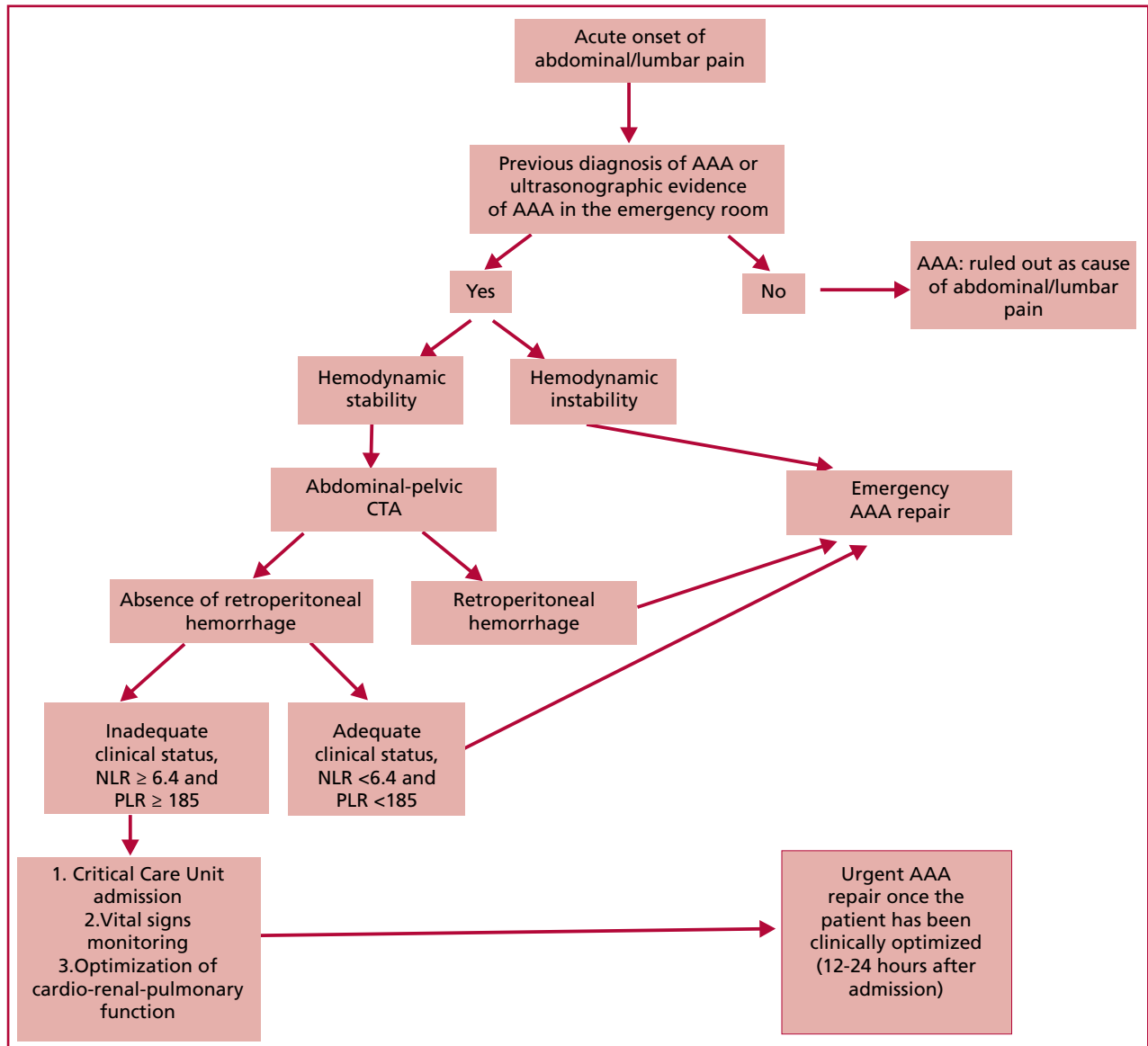
### Prognosis and repair outcomes

The current perioperative mortality rate in symptomatic unruptured AAA patients is below that previously reported in the literature. In this regard, De Martino et al. showed a global in-hospital mortality rate of 1.7% (2.2% in operated patients and 0% in patients undergoing endovascular repair). (22) Similarly, Chandra et al. published a contemporary (2005-2014) global perioperative mortality of 5.9%, involving 8% of surgical patients and 5% of those undergoing endovascular procedures. (17) Regarding postoperative complications and long-term survival, De Martino et al. reported that the rate of postoperative complications, including kidney failure, acute myocardial infarction, arrhythmias and respiratory insufficiency was 35% in patients with symptomatic unruptured AAA versus 20% and 63% in those with asymptomatic and ruptured AAA, respectively. In the case of 1 and 4-year survival, this was 83% and 68%, respectively, in patients with symptomatic unruptured AAA, while in asymptomatic ones it was 89% and 73%, and in those with ruptured AAA, 49% and 35%, respectively. (22) In conclusion, in-hospital mortality of symptomatic unruptured AAA repair is similar or discreetly superior to that observed for the elective intervention. However, the rates of postoperative complications and long-term survival are

intermediate compared with asymptomatic and ruptured AAA repair. (23-27)

### Diagnostic-therapeutic approach

When a symptomatic AAA is suspected, a large caliber venous access should be placed, invasive blood pressure monitoring should be performed, and diagnostic confirmation and immediate treatment should be accomplished at the center where the patient is located. If the conditions to carry out the diagnosis and treatment in the medical center are not met, immediate referral to a high complexity hospital should be activated. (7) Most patients will present with hemodynamic stability since, by definition, there is no rupture of the aortic wall. (17) A high degree of clinical suspicion is essential given the poor prognosis of ruptured and symptomatic unruptured AAA. In a meta-analysis that included studies published after 1990, ruptured AAA misdiagnosis was seen in 32% of cases. The most common erroneous differential diagnoses were ureteric colic and myocardial infarction. (28,29) Figure 1 postulates an algorithm for the diagnostic-therapeutic approach of symptomatic AAA. All individuals admitted to an emergency center with abdominal and/or lumbar pain with a known diagnosis of AAA and who are stable from a hemodynamic point of view, must quickly undergo an abdominal-pelvic computed tomography angiography (CTA). (5) Clinicians may use an abdominal ultrasound to help make the diagnosis whenever it is available. (30) While ultrasound can identify the presence of AAA and intraabdominal fluid, it is less effective at detecting signs of aortic rupture. (31) Ultrasound is therefore not considered a confirmatory test for rupture; however, it represents a useful tool in identifying AAA. Those patients with clinical suspicion and presence of AAA on ultrasound could be considered high-risk for symptomatic AAA, and this may allow for expedited referral CTA. On the other hand, in patients with low clinical risk of symptomatic AAA, the absence of AAA on ultrasound may be sufficient not to carry out further tests, especially if there is another more probable cause that explains the symptoms. (32) If symptomatic AAA is confirmed, a retroperitoneal hemorrhage or the absence of aortic rupture with persistent pain despite optimal medical treatment, including analgesia and control of vital signs, indicates mandatory emergency repair. If, on the contrary, no tomographic findings of aneurysmal rupture are observed, the timing of intervention is controversial and remains a challenge. (8) Numerous retrospective case series have published higher morbidity and mortality rates in emergency AAA repair compared with urgent intervention (18-26% vs. 4-5%). (33-35) In addition, no deaths associated with aneurysm rupture have been reported in patients with symptomatic unruptured AAA, in whom the intervention was postponed and performed semi-electively. (18) Concerning this aspect, different series which have evaluated the causes of death in this group of patients have shown that, in most cases, these are secondary to myocardial infarction, respiratory insufficiency, kidney failure, multiorgan failure and sepsis. (34,36) In our opinion, considering that the morbidity and mortality of patients with symptomatic unruptured AAA undergoing emergency surgery is related to cardio-reno-pulmonary dysfunction, it is reasonable to prioritize the optimization of these systems prior to AAA repair. In this sense, we consider that these objectives could be achieved in a short time span of 12-24 hours, provided the medical center has the necessary resources. It is essential that the patient be admitted to a critical care unit, with suitable vital sign monitoring. From a cardiovascular viewpoint, there is evidence on the usefulness of focused cardiac ultrasonogra-



Modified Sullivan’s algorithm (34)  
 AAA: abdominal aortic aneurysm; CTA: computed tomography angiography; NLR: neutrophil-to-lymphocyte ratio; PLR: platelet-to-lymphocyte ratio

**Fig. 1.** Algorithm for the diagnostic-therapeutic approach of symptomatic AAA

phy (FoCUS) for critical patient assessment, as well as for presurgical evaluation. (37) An echocardiogram performed in the emergency room will provide essential information for hemodynamic management, including left ventricular ejection fraction, presence of significant valve diseases and the degree of patient’s preload, through the transmitral filling pattern, E/E’ relationship, pulmonary systolic pressure, and inferior vena cava diameter, and inspiratory collapsibility. (37) Frequently, elderly patients present with reduced preload prior to surgery with a negative impact on cardiac output, and this can be optimized with an adequate volume load. Some cases may require more invasive monitoring with a Swan Ganz catheter, allowing therapeutic guidance as a function of the hemodynamic state of the patient. Moreover, achieving adequate preload will reduce the risk of postoperative kidney failure. From a respiratory standpoint, reversible obstructive pulmonary disease can improve through a short

treatment with intravenous steroids and aerosol bronchodilators. (34)

Therefore, in this subgroup of patients with symptomatic unruptured AAA it is crucial to identify individuals at high preoperative risk who may benefit from a fast optimization of their clinical status (cardiological, pulmonary and/or renal) prior to an urgent intervention. (17,34) With the objective of answering this problem, different publications have evaluated the usefulness of scores and certain biochemical markers to predict in-hospital mortality in patients with symptomatic unruptured AAA. Antonello et al. reported that the Glasgow Aneurysm Score is a good predictor of perioperative morbidity and mortality after urgent open surgery of symptomatic unruptured AAA. The authors suggest that patients with score <90 can safely undergo an emergency open repair. However, patients with score ≥90 should undergo a thorough assessment and optimization of the preoperative clinical sta-

tus. (38) On the other hand, considering the role of inflammation in the etiopathogenesis of this disease, Garagoli et al. recently evaluated the usefulness of inflammatory biochemical markers for the prediction of in-hospital mortality in patients submitted to surgical and endovascular repair of symptomatic unruptured AAA. The authors concluded that patients with neutrophil-to-lymphocyte ratio  $\geq 6.4$  and/or platelet-to-lymphocyte ratio  $\geq 185$  are at high risk and could benefit from a surveyed waiting conduct prior to optimization of the presurgical clinical status or, even consider an endovascular repair. (36,39) These biomarkers are widely available, have low cost and, in addition, have the advantage of representing the inflammatory state of the patient at the time of hospital admission. This is different from the Glasgow Aneurysm Score that uses clinical variables referred to the patient's prior medical history and considers shock as the only variable of the clinical status at the time of presentation, which we regard as insufficient since, as previously mentioned, these individuals generally present with hemodynamic stability. (36,39)

However, during this preoperative evaluation, it is fundamental that the treating physician is alert to signs and symptoms leading to a mandatory emergency intervention. The development of hypotension, tachycardia, oliguria or metabolic acidosis requires an immediate repair. (7)

#### **Decision on the type of symptomatic unruptured AAA repair: open surgery versus endovascular intervention**

Evidence shows that endovascular intervention reduces morbidity and mortality after symptomatic unruptured AAA repair. In this sense, this type of repair offers some potential advantages compared with conventional surgical treatment in this clinical setting: less physiological aggression to the organism, less need for deep anesthesia, less blood loss, minimizes hypothermia and reduces intervention time. (7) The analysis of the ENGAGE Registry demonstrated lack of difference in the elective endovascular repair of asymptomatic AAA versus symptomatic unruptured AAA. (19) A systematic review identified 23 observational studies evaluating 7040 symptomatic unruptured and ruptured AAA repairs (with surgical and endovascular intervention) and showed that patients undergoing endovascular intervention presented a lower rate of in-hospital mortality compared with open surgery (odds ratio 0.624, 95% CI 0.518-0.752;  $p < 0.0001$ ), as well as reduced length of hospital stay, lower bleeding and decreased intervention time. (40)

However, to perform endovascular AAA repair it is essential to fulfill the required anatomical criteria in addition to an institutional program for the emergency endovascular intervention. In this context, the role of CTA is crucial to define those patients fit for endovascular repair. (5,8) Moreover, we consider that the transfer to a high-complexity vascular center is appropriate for hemodynamically stable patients and anatomically apt for endovascular repair, especially if the surgical risk is high.

#### **CONCLUSIONS**

Symptomatic unruptured AAA constitutes a clinical form of potentially life-threatening AAA, with an intermediate prognosis between asymptomatic patients and those with ruptured aneurysms. Although the timing of intervention is still controversial, we consider it is essential to stratify individual preoperative risk, with the object of identifying high-risk patients who would benefit from the optimization of their clinical

status prior to the intervention. Endovascular repair is feasible in this clinical scenario, mainly in patients at high surgical risk, provided the required anatomical criteria are fulfilled and the institution has a program for emergency endovascular intervention.

#### **Financing**

This research has not received any specific grant from public, commercial, or non-profit agencies.

#### **Conflicts of interest**

None declared.

(See authors' conflict of interests forms on the web/Additional material).

#### **REFERENCES**

1. Antoniou GA, Antoniou AI, Antoniou SA, Lazarides MK. A historical perspective of medical terminology of aortic aneurysm. *J Vasc Surg [Internet]*. 2011;54:1527-8. Available from: <http://dx.doi.org/10.1016/j.jvs.2011.04.036>
2. Real Academia Real Academia de la Lengua Espanola, de la lengua Española Asociacion de Academias. *Diccionario de la Lengua Espanola RAE [Internet]*. Planeta Publishing; 2014. Available from: [https://books.google.com/books/about/Diccionario\\_de\\_la\\_Lengua\\_Espanola\\_RAE.html?hl=&id=naqwoQEACAAJ](https://books.google.com/books/about/Diccionario_de_la_Lengua_Espanola_RAE.html?hl=&id=naqwoQEACAAJ)
3. Doval HC, Lucas LO. Aneurisma de aorta abdominal. En: Doval HC, Tajer CD, editores. *Evidencias en cardiología: De los ensayos clínicos a las conductas terapéuticas*. 8° edición. Ciudad Autónoma de Buenos Aires: GEDIC; 2016. p. 1139-69.
4. Erbel R, Aboyans V, Boileau C, Bossone E, Bartolomeo RD, Eggebrecht H, et al. 2014 ESC Guidelines on the diagnosis and treatment of aortic diseases: Document covering acute and chronic aortic diseases of the thoracic and abdominal aorta of the adult. The Task Force for the Diagnosis and Treatment of Aortic Diseases of the European Society of Cardiology (ESC). *Eur Heart J [Internet]*. 2014;35:2873-926. Available from: <http://dx.doi.org/10.1093/eurheartj/ehu281>
5. Chaikof EL, Dalman RL, Eskandari MK, Jackson BM, Lee WA, Mansour MA, et al. The Society for Vascular Surgery practice guidelines on the care of patients with an abdominal aortic aneurysm. *J Vasc Surg [Internet]*. 2018;67:2-77.e2. Available from: <http://dx.doi.org/10.1016/j.jvs.2017.10.044>
6. Writing Committee Members, Isselbacher EM, Preventza O, Hamilton Black J Iii, Augoustides JG, Beck AW, et al. 2022 ACC/AHA Guideline for the Diagnosis and Management of Aortic Disease: A Report of the American Heart Association/American College of Cardiology Joint Committee on Clinical Practice Guidelines. *J Am Coll Cardiol [Internet]*. 2022;80:e223-393. Available from: <http://dx.doi.org/10.1016/j.jacc.2022.08.004>
7. Bluro I. Consenso de Enfermedad Vascul Periférica (versión resumida). *Rev Argent Cardiol [Internet]*. 2015;83:461-86. Available from: [http://ppct.caicyt.gov.ar/index.php/rac/article/view/6400/pdf\\_1](http://ppct.caicyt.gov.ar/index.php/rac/article/view/6400/pdf_1)
8. Wanhainen A, Verzini F, Van Herzele I, Allaire E, Bown M, Cohnert T, et al. Editor's Choice - European Society for Vascular Surgery (ESVS) 2019 Clinical Practice Guidelines on the Management of Abdominal Aorto-iliac Artery Aneurysms. *Eur J Vasc Endovasc Surg [Internet]*. 2019;57:8-93. Available from: <http://dx.doi.org/10.1016/j.ejvs.2018.09.020>
9. Reimerink JJ, Hoornweg LL, Vahl AC, Wisselink W, van den Broek TAA, Legemate DA, et al. Endovascular repair versus open repair of ruptured abdominal aortic aneurysms: a multicenter randomized controlled trial. *Ann Surg [Internet]*. 2013;258:248-56. Available from: <http://dx.doi.org/10.1097/SLA.0b013e31828d4b76>
10. IMPROVE Trial Investigators, Powell JT, Sweeting MJ, Thompson MM, Ashleigh R, Bell R, et al. Endovascular or open repair strategy for ruptured abdominal aortic aneurysm: 30 day outcomes from IMPROVE randomised trial. *BMJ [Internet]*. 2014;348:f7661. Available from: <http://dx.doi.org/10.1136/bmj.f7661>
11. Desgranges P, Kobeiter H, Katsahian S, Bouffi M, Gouny P, Favre JP, et al. Editor's Choice - ECAR (Endovasculaire ou Chirurgie

- dans les Anévrismes aorto-iliaques Rompus): A French Randomized Controlled Trial of Endovascular Versus Open Surgical Repair of Ruptured Aorto-iliac Aneurysms. *Eur J Vasc Endovasc Surg* [Internet]. 2015;50:303–10. Available from: <http://dx.doi.org/10.1016/j.ejvs.2015.03.028>
12. Greenhalgh RM, Brown LC, Kwong GPS, Powell JT, Thompson SG, EVAR trial participants. Comparison of endovascular aneurysm repair with open repair in patients with abdominal aortic aneurysm (EVAR trial 1), 30-day operative mortality results: randomised controlled trial. *Lancet* [Internet]. 2004;364:843–8. Available from: [http://dx.doi.org/10.1016/S0140-6736\(04\)16979-1](http://dx.doi.org/10.1016/S0140-6736(04)16979-1)
  13. United Kingdom EVAR Trial Investigators, Greenhalgh RM, Brown LC, Powell JT, Thompson SG, Epstein D. Endovascular repair of aortic aneurysm in patients physically ineligible for open repair. *N Engl J Med* [Internet]. 2010;362:1872–80. Available from: <http://dx.doi.org/10.1056/NEJMoa0911056>
  14. Blankensteijn JD, de Jong SECA, Prinssen M, van der Ham AC, Buth J, van Sterkenburg SMM, et al. Two-year outcomes after conventional or endovascular repair of abdominal aortic aneurysms. *N Engl J Med* [Internet]. 2005;352:2398–405. Available from: <http://dx.doi.org/10.1056/NEJMoa051255>
  15. Lederle FA, Freischlag JA, Kyriakides TC, Padberg FT Jr, Matsuura JS, Kohler TR, et al. Outcomes following endovascular vs open repair of abdominal aortic aneurysm: a randomized trial. *JAMA* [Internet]. 2009;302:1535–42. Available from: <http://dx.doi.org/10.1001/jama.2009.1426>
  16. Signs, symptoms and risk factors predicting ruptured or symptomatic unruptured aneurysms before arrival at the hospital, and in non-specialist hospital settings: Abdominal aortic aneurysm: diagnosis and management: Evidence review N [Internet]. London: National Institute for Health and Care Excellence (NICE); Available from: <https://www.ncbi.nlm.nih.gov/pubmed/32407039>
  17. Chandra V, Trang K, Virgin-Downey W, Tran K, Harris EJ, Dalman RL, et al. Management and outcomes of symptomatic abdominal aortic aneurysms during the past 20 years. *J Vasc Surg* [Internet]. 2017;66:1679–85. Available from: <http://dx.doi.org/10.1016/j.jvs.2017.04.033>
  18. Cambria RA, Glociczki P, Stanson AW, Cherry KJ Jr, Hallett JW Jr, Bower TC, et al. Symptomatic, nonruptured abdominal aortic aneurysms: are emergent operations necessary? *Ann Vasc Surg* [Internet]. 1994;8:121–6. Available from: <http://dx.doi.org/10.1007/BF02018859>
  19. Stokmans RA, Teijink JAW, Cuyppers PWM, Riambau V, van Sambeek MRHM. No differences in perioperative outcome between symptomatic and asymptomatic AAAs after EVAR: an analysis from the ENGAGE Registry. *Eur J Vasc Endovasc Surg* [Internet]. 2012;43:667–73. Available from: <http://dx.doi.org/10.1016/j.ejvs.2012.02.034>
  20. Aggarwal S, Qamar A, Sharma V, Sharma A. Abdominal aortic aneurysm: A comprehensive review. *Exp Clin Cardiol* [Internet]. 2011;16:11–5. Available from: <https://www.ncbi.nlm.nih.gov/pubmed/21523201>
  21. Reeps C, Essler M, Pelisek J, Seidl S, Eckstein HH, Krause BJ. Increased 18F-fluorodeoxyglucose uptake in abdominal aortic aneurysms in positron emission/computed tomography is associated with inflammation, aortic wall instability, and acute symptoms. *J Vasc Surg* [Internet]. 2008;48:417–23; discussion 424. Available from: <http://dx.doi.org/10.1016/j.jvs.2008.03.059>
  22. De Martino RR, Nolan BW, Goodney PP, Chang CK, Schanzer A, Cambria R, et al. Outcomes of symptomatic abdominal aortic aneurysm repair. *J Vasc Surg* [Internet]. 2010;52:5–12.e1. Available from: <http://dx.doi.org/10.1016/j.jvs.2010.01.095>
  23. Stather PW, Sidloff D, Dattani N, Choke E, Bown MJ, Sayers RD. Systematic review and meta-analysis of the early and late outcomes of open and endovascular repair of abdominal aortic aneurysm. *Br J Surg* [Internet]. 2013;100:863–72. Available from: <http://dx.doi.org/10.1002/bjs.9101>
  24. Powell JT, Sweeting MJ, Ulug P, Blankensteijn JD, Lederle FA, Becquemin JP, et al. Meta-analysis of individual-patient data from EVAR-1, DREAM, OVER and ACE trials comparing outcomes of endovascular or open repair for abdominal aortic aneurysm over 5 years. *Br J Surg* [Internet]. 2017;104:166–78. Available from: <http://dx.doi.org/10.1002/bjs.10430>
  25. Li B, Khan S, Salata K, Hussain MA, de Mestral C, Greco E, et al. A systematic review and meta-analysis of the long-term outcomes of endovascular versus open repair of abdominal aortic aneurysm. *J Vasc Surg* [Internet]. 2019;70:954–69.e30. Available from: <http://dx.doi.org/10.1016/j.jvs.2019.01.076>
  26. Sweeting MJ, Balm R, Desgranges P, Ulug P, Powell JT, Ruptured Aneurysm Trialists. Individual-patient meta-analysis of three randomized trials comparing endovascular versus open repair for ruptured abdominal aortic aneurysm. *Br J Surg* [Internet]. 2015;102:1229–39. Available from: <http://dx.doi.org/10.1002/bjs.9852>
  27. Alsusa H, Shahid A, Antoniou GA. A comparison of endovascular versus open repair for ruptured abdominal aortic aneurysm - Meta-analysis of propensity score-matched data. *Vascular* [Internet]. 2022;30:628–38. Available from: <http://dx.doi.org/10.1177/17085381211025168>
  28. Tchana-Sato V, Sakalihan N, Defraigne JO. [Ruptured abdominal aortic aneurysm]. *Rev Med Liege* [Internet]. 2018;73:296–9. Available from: <https://www.ncbi.nlm.nih.gov/pubmed/29926569>
  29. Azhar B, Patel PJE, Hinchliffe RJ, Thompson MM, Karthikesalingam A. Misdiagnosis of ruptured abdominal aortic aneurysm: systematic review and meta-analysis. *J Endovasc Ther* [Internet]. 2014;21:568–75. Available from: <http://dx.doi.org/10.1583/13-4626MR.1>
  30. Mai T, Woo MY, Boles K, Jetty P. Point-of-Care Ultrasound Performed by a Medical Student Compared to Physical Examination by Vascular Surgeons in the Detection of Abdominal Aortic Aneurysms. *Ann Vasc Surg* [Internet]. 2018;52:15–21. Available from: <http://dx.doi.org/10.1016/j.avsg.2018.03.015>
  31. Shuman WP, Hastrup W Jr, Kohler TR, Nyberg DA, Wang KY, Vincent LM, et al. Suspected leaking abdominal aortic aneurysm: use of sonography in the emergency room. *Radiology* [Internet]. 1988;168:117–9. Available from: <http://dx.doi.org/10.1148/radiology.168.1.3289085>
  32. Fernando SM, Tran A, Cheng W, Rochweg B, Strauss SA, Mutter E, et al. Accuracy of presenting symptoms, physical examination, and imaging for diagnosis of ruptured abdominal aortic aneurysm: Systematic review and meta-analysis. *Acad Emerg Med* [Internet]. 2022;29:486–96. Available from: <http://dx.doi.org/10.1111/acem.14475>
  33. Haug ES, Romundstad P, Aadahl P, Myhre HO. Emergency non-ruptured abdominal aortic aneurysm. *Eur J Vasc Endovasc Surg* [Internet]. 2004;28:612–8. Available from: <http://dx.doi.org/10.1016/j.ejvs.2004.09.013>
  34. Sullivan CA, Rohrer MJ, Cutler BS. Clinical management of the symptomatic but unruptured abdominal aortic aneurysm. *J Vasc Surg* [Internet]. 1990;11:799–803. Available from: <http://www1.mosby.com/scripts/om.dll/serve?action=searchDB&searchDBfor=art&artType=abs&id=a19420>
  35. Ten Bosch JA, Koning SW, Willigendael EM, VAN Sambeek MR, Stokmans RA, Prins MH, et al. Symptomatic abdominal aortic aneurysm repair: to wait or not to wait. *J Cardiovasc Surg* [Internet]. 2016;57:830–8. Available from: <https://www.ncbi.nlm.nih.gov/pubmed/23867861>
  36. Garagoli F, Fiorini N, Pérez MN, Rabellino JM, Valle Raleigh J, Chas JG, et al. Neutrophil-to-lymphocyte ratio and platelet-to-lymphocyte ratio predict in-hospital mortality in symptomatic but unruptured abdominal aortic aneurysm patients. *Int Angiol* [Internet]. 2022;41:188–95. Available from: <http://dx.doi.org/10.23736/S0392-9590.22.04754-X>
  37. Lenk T, Whittle J, Miller TE, Williams DGA, Bronshteyn YS. Focused cardiac ultrasound in preoperative assessment: the perioperative provider's new stethoscope? *Perioper Med (Lond)* [Internet]. 2019;8:16. Available from: <http://dx.doi.org/10.1186/s13741-019-0129-8>
  38. Antonello M, Lepidi S, Kechagias A, Frigatti P, Tripepi A, Biancari F, et al. Glasgow aneurysm score predicts the outcome after emergency open repair of symptomatic, unruptured abdominal aortic aneurysms. *Eur J Vasc Endovasc Surg* [Internet]. 2007;33:272–6. Available from: <http://dx.doi.org/10.1016/j.ejvs.2006.09.006>
  39. Samy AK, Murray G, MacBain G. Glasgow aneurysm score. *Cardiovasc Surg* [Internet]. 1994;2:41–4. Available from: <https://www.ncbi.nlm.nih.gov/pubmed/8049922>
  40. Sadat U, Boyle JR, Walsh SR, Tang T, Varty K, Hayes PD. Endovascular vs open repair of acute abdominal aortic aneurysms - a systematic review and meta-analysis. *J Vasc Surg* [Internet]. 2008;48:227–36. Available from: <http://dx.doi.org/10.1016/j.jvs.2007.11.028>